



Thoroughly Updated with all Recent and Image-based Questions

Free Online Exam Support www.accesspgmee.com

Review of

RADIOLOGY

*Based on facts and concepts from Som and Curtin 5th/e, Dahnert 8th/e, Grainger 6th/e, Sutton, Scott, Rumack 4th/e, CT and MRI (Haaga), and AIIMS-MAMC PGI Imaging Series
Updated based on latest editions of standard books*

Rajat Jain
Virendra Jain

Explained Referenced Answers

All Recent Questions (2016–2012)

All India (2012–1991)

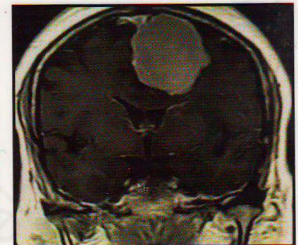
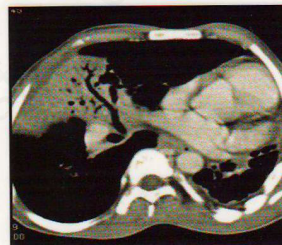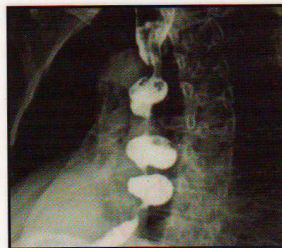
AIIMS (May 2016–1991)

DNB (2012–1991)

AP, JIPMER, WBPGMEE (2016)

Other State Exams (2016–1991)

Image-based questions



Download From: AghaLibrary.com

A must-buy book for All India, AIIMS, PGI, JIPMER, DNB, USMLE, FMGE & State entrance exams

Review of Radiology

Rajat Jain

MD (MAMC) DNB FRCR (UK)

Fellow, Body Imaging

University of Ottawa, Canada

Consultant and Head, Department of Radiology

Primus Super Speciality Hospital

Chanakyapuri, New Delhi

Virendra Jain

MBBS (UCMS) MD (MAMC) FRCR (UK)

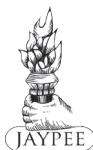Senior Resident

Maulana Azad Medical College, New Delhi



JAYPEE *The Health Sciences Publisher*

New Delhi | London | Philadelphia | Panama



Jaypee Brothers Medical Publishers (P) Ltd

Headquarters

Jaypee Brothers Medical Publishers (P) Ltd.
4838/24, Ansari Road, Daryaganj
New Delhi 110 002, India
Phone: +91-11-43574357
Fax: +91-11-43574314
E-mail: jaypee@jaypeebrothers.com

Overseas Offices

J.P. Medical Ltd.
83, Victoria Street, London
SW1H 0HW (UK)
Phone: +44-20 3170 8910
Fax: +44(0)20 3008 6180
E-mail: info@jpmedpub.com

Jaypee-Highlights Medical Publishers Inc.
City of Knowledge, Bld. 235, 2nd Floor, Clayton
Panama City, Panama
Phone: +1 507-301-0496
Fax: +1 507-301-0499
E-mail: cservice@jphmedical.com

Jaypee Medical Inc.
325 Chestnut Street
Suite 412
Philadelphia, PA 19106, USA
Phone: +1 267-519-9789
E-mail: support@jpmedus.com

Jaypee Brothers Medical Publishers (P) Ltd.
17/1-B, Babar Road, Block-B, Shaymali
Mohammadpur, Dhaka-1207
Bangladesh
Mobile: +08801912003485
E-mail: jaypeedhaka@gmail.com

Jaypee Brothers Medical Publishers (P) Ltd.
Bhotahity, Kathmandu, Nepal
Phone: +977-9741283608
E-mail: kathmandu@jaypeebrothers.com

Website: www.jaypeebrothers.com
Website: www.jaypeedigital.com

© 2016, Jaypee Brothers Medical Publishers

The views and opinions expressed in this book are solely those of the original contributor(s)/author(s) and do not necessarily represent those of editor(s) of the book.

All rights reserved. No part of this publication may be reproduced, stored or transmitted in any form or by any means, electronic, mechanical, photocopying, recording or otherwise, without the prior permission in writing of the publishers.

All brand names and product names used in this book are trade names, service marks, trademarks or registered trademarks of their respective owners. The publisher is not associated with any product or vendor mentioned in this book.

Medical knowledge and practice change constantly. This book is designed to provide accurate, authoritative information about the subject matter in question. However, readers are advised to check the most current information available on procedures included and check information from the manufacturer of each product to be administered, to verify the recommended dose, formula, method and duration of administration, adverse effects and contraindications. It is the responsibility of the practitioner to take all appropriate safety precautions. Neither the publisher nor the author(s)/editor(s) assume any liability for any injury and/or damage to persons or property arising from or related to use of material in this book.

This book is sold on the understanding that the publisher is not engaged in providing professional medical services. If such advice or services are required, the services of a competent medical professional should be sought.

Every effort has been made where necessary to contact holders of copyright to obtain permission to reproduce copyright material. If any have been inadvertently overlooked, the publisher will be pleased to make the necessary arrangements at the first opportunity.

Inquiries for bulk sales may be solicited at: jaypee@jaypeebrothers.com

Review of Radiology

First Edition: **2016**

ISBN: 978-93-85999-00-0

Printed at

Dedicated to

Our mothers

*Mrs Kanta Devi Jain and Mrs Sarla Jain
for their love and moral support*

Preface

Review of Radiology, the book is intended to help students in understanding the basic concepts of the subject with the help of images, who are preparing for the postgraduate medical entrance examination (PGMEE). It is a concise review of key radiology principles to help students not just in understanding radiology which they might have missed during their clinics in MBBS but also to help them in applications of imaging modalities for various clinical conditions like in medicine and surgery. Considering the changing pattern of exam and introduction of NEET at Pan India level, we feel that application-based questions are future of entrance exams at postgraduate level. We would like to state that, this book is not a substitute for comprehensive textbooks of radiology at any level, however, we have tried to cover all the commonly asked topics in entrance exams in a concise format so that students can finish the reading of this book in two days. Some facts are presented in the boxes on the side so that they can be easily revised in the end. We feel that after reading this book, a student preparing for postgraduate entrance examination will not feel the need to refer any other radiology books or courses.

This book is a concise and considerably shorter, still complete version than the full-length, standard radiology textbook. Most of this book evolved from the latest editions of **Grainger and Sutton's Textbooks of Radiology**, CT and MRI imaging—Haaga and AIIMS- MAMC-PGI CME series. All the facts in the book are checked multiple number of times to give an accurate and up-to-date content to the students.

The material is organized into 4 sections and seven chapters. Section-A includes General Radiology (Chapter 1). Section-B includes, Neuroradiology (Chapter 2), Cardiothoracic Radiology (Chapter 3), Gastrointestinal and Genitourinary System (Chapter 4) and Musculoskeletal Radiology (Chapter 5). Section-C includes Radiotherapy and Chemotherapy (Chapter 6), and Nuclear Scans (Chapter 7) and one special Section-E for Image Based Questions exercise.

Difficult concepts are explained stepwise and in form of flowcharts with special high yield points in separate boxes adjacent to text wherever relevant. More than 150 images and more than 50 flow diagrams and tables will help the students not just to understand the text but also to memorize the material quickly in a way to aid in long-term retention.

Each chapter begins with a concise theory of each topic, followed by multiple-choice questions (MCQs) and their clear, concise, proper explanations with references of the standard textbooks and/or, research papers wherever required to avoid repetition of the text. Various states PG, AIIMS and JIPMER examination questions had been separated from PGI questions, so that the students can easily concentrate different examinations according to their choice.

Each chapter has high yield points in the boxes which are predicted and highly expected new questions for future examination, based on current examination pattern.

Section-E, The IBQ section would definitely help the students in preparing for the different types of questions based in images expected to be asked in the examination.

The online pool of questions is going to be a backbone for the preparation of IBQs in any examination not just for radiology but for other subjects too.

Finally the Section-D has a collection of important factual information of radiology including the investigations of choices, important systemic signs and important principles of radiology which might be helpful to solve questions from any clinical subject if understood rightly.

How to Read this Book

The best way to read this book is to read the theory given at the beginning of the chapter first and then solve the MCQs. The MCQs of a particular system are arranged randomly without mentioning the years. Absolute care has been taken to avoid repetition of the MCQs as lots of time is wasted in solving the same MCQ again and again. We want to stress on this fact that nowadays in the exams, same questions are not repeated but same topics are repeated and hence students are advised to focus more on the theoretical concepts rather than just MCQs. It is this reason that, deliberately years of the questions and superscript on important lines have not been put as we believe that each line written is a potential MCQ. We suggest that section A, C and D should be read together where section C should be read in associating with other clinical subjects like medicine, surgery, orthopedics, pediatrics, gynecology-obstetrics as they are interlinked.

We wish that our students will go through this book thoroughly and will do excellent in their examinations.

Best wishes for your postgraduate medical entrance examination. Your queries and feedback will always be welcomed. You are free to contact at email: reviewofradiology@gmail.com

Rajat Jain
Virendra Jain

Tips for Winners

- ★ Confidence is the key to success. Believe in yourself because if you won't nobody else will.
- ★ Don't be daunted by the efforts others put in because everybody is a different person and you only can find a pace and method to prepare that is conducive to exclusively yourself and thus maximizes your potential.
- ★ Never believe a person who says that you can't do something. People will tell you certain things can't be done when they can't do them themselves.
- ★ Studying smarter than others is much more important than studying harder when it comes to competitive exams.
- ★ It is a level playing field... so forget your past performances whether good or bad because in the end everybody is preparing for the same one day game. Hence, it is important to take your best shot on that very day.
- ★ It is never too late to start, seriously. There are a large number of success stories of people who started out late. However, the sooner the better still holds good even for those people especially in a rank based system.
- ★ Never doubt yourself and your capabilities. Even the brightest of minds have their episodes of insecurity and uncertainty. In such times try this technique. Close your eyes and recall a past episode during which you were under stress and you handled it well, exceeding your own expectations. The feeling of being in control will return your confidence in no time and the doubt will vanish.
- ★ BEG/BORROW/STEAL/KILL/ROB OR LOOT... but always lay your hands on the question papers of the previous few years because even if none of the questions are repeated (of which there is a slim chance of happening), you'll at least be familiar with the pattern and the type of questions asked in that exam.
- ★ Weeks before the exam, have an honest conversation with yourself, reassure yourself about your preparation and come to terms with the lacunae. A day before the exam, reassess the state and decide how much you expect from the exam..
- ★ Get adequate rest, starting a week before exam... large multicentric studies have proven that it is common sense to.
- ★ While taking the exam, take your time while marking each answer because it is marked in ink. And one wrong question takes away more than even leaving one at the end. So take your time while answering. This is where the importance of practice tests lie.
- ★ Guessing is a tricky game. Exclude all the choices you are SURE can not be the answer then mark your favorite letter!! In cases of all choices being new, go for the first one you think is the answer. Apart from saving time most often changing your mind leads to a wrong answer.
- ★ Personally I don't believe in leaving any question unmarked, but it is a personal decision and should heavily depend on the state of rest of the paper and number of unmarked answers.
- ★ After the exam, celebrate!!!! No matter what ...and hope for the best.

Cool Quotes (to be Read when on a Break)

- * Motivation will almost always beat mere talent.
- * A mind troubled by doubt cannot focus on the course to victory.
- * Do what you can, with what you have, where you are.
- * Many of life's failures are people who did not realize how close they were to success when they gave up.
- * The art of being wise is knowing what to overlook.
- * Obstacles are those frightful things you see when you take your eyes off your goal.
- * Too many people overvalue what they are not and undervalue what they are.
- * Though no one can go back and make a brand new start, anyone can start from now and make a brand new ending.
- * The real contest is always between what you've done and what you're capable of doing. You measure yourself against yourself and nobody else.
- * The difference between a successful person and others is not a lack of strength, not a lack of knowledge, but rather a lack of will.
- * According to aerodynamic laws, the bumblebee cannot fly. Its body weight is not the right proportion to its wingspan. Ignoring these laws, the bee flies anyway.
- * The mind is like a parachute—it works only when it is open.
- * Yesterday is a cancelled check; Tomorrow is a promissory note; Today is the only cash you have, so spend it wisely.
- * Never mistake knowledge for wisdom. One helps you make a living, the other helps you make a life.
- * The more I want to get something done, the less I call it work.
- * The secret of success is to do the common things uncommonly well.
- * Hard work beats talent when talent doesn't work hard.
- * Successful and unsuccessful people do not vary greatly in their abilities. They vary in their desires to reach their potential.
- * You must do the very thing you think you cannot do.
- * Your goal should be out of reach but not out of sight.

Acknowledgments

First of all, I (**Rajat Jain**) would like to thank my wife, Dr Ananta Khurana for her constant and unconditional support and also for taking care of my cute little daughter almost single handedly at this time. My special thanks to my elder daughter, Anushka and just born daughter Ahaana.

Very special thanks to my dear friend, Dr Nishith Kumar for helping me at each step during the writing of this book

A very special thanks to my dear friends, colleagues and seniors Dr Thameem Saif, Dr Apurv Mehra, Dr Devesh Mishra and Dr Praveen Kumar for literally pushing me to write this book.

A very special thanks to Dr Mukesh Bhatia (Director, Dr Bhatia Medical Institute), Mr Rajesh Sharma (Director, PG-DIAMS), Dr Vineet Gupta (Director, MIST) and Dr Sukreet Sharma (Director, IAMS) for believing in me and giving me the opportunity to interact with the students and understanding my potential to be of some help to students in achieving their dream.

A special thanks to our respected teachers who have taught us enough radiology so that we are able to reach to this level to help the students in their Endeavour. The list is endless but the names that need special mention are:

Dr Veena Chowdhury (Ex-Director, GB Pant Hospital and HOD Radiology, MAMC, New Delhi)

Dr Anju Garg (HOD Radiology, MAMC, New Delhi)

Dr BB Thukral (HOD Radiology, VMMC, New Delhi)

Dr Lalendra Upreti (HOD Radiology, UCMS, New Delhi)

Dr Rama Anand (HOD Radiology, Lady Hardinge Hospital, New Delhi)

Dr UC Garga (HOD Radiology, RML Hospital New Delhi)

Dr Anjali Prakash (Faculty, MAMC, New Delhi)

Dr Rashmi dixit (Faculty, MAMC, New Delhi)

Dr Alpana Manchanda (Faculty, MAMC, New Delhi)

D Gaurav Pradhan (Faculty, MAMC, New Delhi)

Dr Sapna Singh (Faculty, MAMC, New Delhi)

Dr Jyoti Kumar (Faculty, MAMC, New Delhi)

Dr MK Mittal (Faculty, VMMC, New Delhi)

Dr Atin Kumar (Faculty, AIIMS, New Delhi)

Dr Deepak Gupta (Director Radiology, Saroj Hospital, New Delhi)

We would also like to thank Dr OP BANSAL, president, Indian Radiological Imaging Association and the entire team of Delhi state branch with a special mention of Dr Upreti, Dr Atin, Dr Raghav, Dr Pankaj and Dr Lalchandani for giving us the opportunity to enhance our teaching skills by giving us the opportunity to deliver talks in various conferences at state and national level.

We would also like to thank our other co-faculties with whom we have a lot of healthy discussions about exam including MCQs, changing pattern of exam and lot of other mischievous talks during waiting for the flight at the airport, in the flight, dinner discussions after the long class. Again, we would like to mention few names here:

Dr Rajesh Kaushal, Anatomy
Dr Ashwini, Anatomy
Dr Ashish, Physiology
Dr Ankur, Biochemistry
Dr Devesh Mishra, Pathology
Dr Praveen kumar, Pathology
Dr Akhilesh Jhamad, Forensic Medicine, Microbiology and Dermatology
Dr Gobing Rai Garg, Pharmacology
Dr Ranjan Kumar Patel, Pharamcology
Dr Saurabh, Pharmacology
Dr Vivek Jain, PSM
Dr Manisha, ENT
Dr Ray, Ophthalmology
Dr Thameem Saif, Medicine
Dr Deepak Marwah, Medicine
Dr Shubham Vats, Medicine
Dr Pritesh Singh, Surgery
Dr Tiwari, Surgery
Dr Vineet Gupta, Surgery
Dr Harmeet, Gyne & Obstetrics
Dr Vij, Gyne & Obstetrics
Dr Meenakshi, Pediatrics
Dr Apurv Mehra, Orthopedics
Dr Amit kohli, Anesthesia
Dr Manish Soni, Dermatology
Dr Dharmedra, Psychiatry
Dr Shivani jain, Ophthalmology
Dr Praveen Tripathi, Psychiatry

We are also very thankful to following coordinators for encouraging us and highlighting our positive and negative points during our teaching sessions for constant improvement.

Dr Chintan, Rajkot
Dr Neeraj, Kolkata
Dr Praneet, Hyderabad
Dr Rajeshwar Gudade, Nagpur
Mr Ajay Sharma, Ahmedabad
Mr Alok and Shivlok, Bihar and Jharkhand

Mr Amit Bhatia, Jaipur

Mr Anil, Mumbai

Mr Anupam, Chandigarh

Mr Dhruv Kharbanda, Lucknow

Mr Moin, Bangalore

Mr Rahul, Hyderabad

Mr Rajeev Sharma, Chennai

Mr Abhishek Dubey, Bhopal

I (**Virendra Jain**) would like to acknowledge and thank my family for having the patience with me and supporting throughout especially my father (G.L Jain) and my brothers (Devender and Narendar Jain), who gave me encouragement in their particular way.

I would also like to thank my Seniors, Dr. Naveen Bhardwaj and Dr. Manoj Middha, who have always supported me throughout my career and authoring this book and I really appreciate it.

It is a great pleasure to acknowledge the inspiration and help of my colleagues (Kanav Kaushal and Sahil Batra) and seniors in my department for their constant help and support and my juniors (Amar, Vinayaga and Sanchit) who always were ready to help me whenever I asked for.

We would like to thank Mr Jitendar P Vij (Group Chairman) of Jaypee Brothers Medical Publishers (P) Ltd. for enabling me to publish this book. We would also like to thank Mr Rakesh Sheoran for helping us in the process of selection and editing.

Last but the most important, we would like to thank all our students who have been our inspiration and support for writing this book.

Rajat Jain
Virendra Jain

Suggested Time-Table for Preparation in One Year

Dear Friends, there is no limit of reading as knowledge never goes waste however, being passed through the same phase and also by performing decently in exam we have realized that you can crack this exam by combined knowledge of all the 19 subjects rather than being a master of three subjects and leaving 3 subjects.

We suggest that you should have ample time to revise the topics before the exam and in the initial part of the preparation, more time should be spent on building up the concepts whereas factual parts should be kept for revision as your concepts will stay with you but facts need to be strengthen again and again. We believe that every student should follow his own time-table but we are giving a suggested time-table based on the importance of the subject in the postgraduate exam and we encourage students to use this as a baseline with individualization, depending upon the needs.

| S. No. | Subject | No of days |
|--------|---------------------------|------------|
| 1. | Anatomy | 8 |
| 2. | Physiology | 8 |
| 3. | Biochemistry | 10 |
| 4. | Pathology | 20 |
| 5. | Microbiology | 7 |
| 6. | Pharmacology | 15 |
| 7. | Forensic Medicine | 3 |
| 8. | Community Medicine | 15 |
| 9. | ENT | 7 |
| 10. | Ophthalmology | 10 |
| 11. | Medicine | 27 |
| 12. | Surgery | 25 |
| 13. | Gynecology and Obstetrics | 20 |
| 14. | Pediatrics | 10 |
| 15. | Orthopedics | 3 |
| 16. | Skin | 3 |
| 17. | Anesthesia | 3 |
| 18. | Psychiatry | 3 |
| 19. | Radiology | 3 |
| | | 200 |

Contents

Section A: General Radiology

1. General Radiology 3

Section B: Systemic Radiology

2. Neuroradiology 45
3. Cardiothoracic Radiology 75
4. Gastrointestinal and Genitourinary System 124
5. Musculoskeletal Radiology 170

Section C: Radiotherapy and Nuclear Scans

6. Radiotherapy and Chemotherapy 213
7. Nuclear Scans 236

Section D: Few Thumb Rules in Radiology

- Few Thumb Rules in Radiology 253

Section E: Image Based Questions

- Image Based Questions

Section A

GENERAL RADIOLOGY

mebooksfree.com

1

General Radiology

GENERAL

Radiation: Energy that comes from a source and travel through some material or through space.

Can be:

| (1) Ionizing | (2) Non-ionizing |
|-----------------------------------|--------------------|
| Electromagnetic radiations | (a) UV-rays |
| (a) X-rays | (b) Visible rays |
| (b) γ -rays | (c) Infra red-rays |
| (c) Cosmic rays | (d) microwaves |
| Particulate radiations | (e) radiowaves |
| (a) α -rays | |
| (b) β -rays | |
| (c) Protons | |
| (d) neutrons | |

Various diagnostic modalities and procedures and radiations

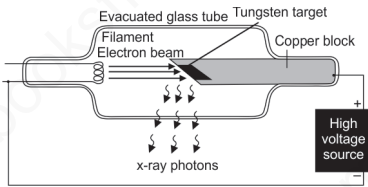
| <u>Ionizing Radiations</u> | | <u>Non-Ionizing</u> |
|----------------------------|----------------------------|---------------------|
| X-Rays are used in | γ -Rays are used in | |
| 1. CT-scan | PET | MRI |
| 2. Radiography | Bone-scan | USG |
| 3. DEXA | Radionuclide Scan | Thermogra- phy |
| 4. IVP/IVU | SPECT | Doppler |
| 5. HSG | | MRCP |
| 6. Bronchography | | |
| 7. ERCP | | |
| 8. Fluoroscopy | | |

1 Particulate Radiations have variable charge and mass whereas electromagnetic radiations have no charge and mass.

1 All electromagnetic rays have same velocity i.e. velocity of light.

1 X-rays are extranuclear in origin. Gamma rays are intranuclear in origin.

1 X-rays: Iodinated dye (always)
ERCP = Diagnostic + Therapeutic but invasive
MRCP = Only diagnostic but non-invasive



X-Ray Tube

Wilhelm Conrad Roentgen, a German physicist, discovered X-rays on **November 8, 1895**.

- Awarded the **first Nobel Prize for Physics in 1901**.
- *Considered as Father of radiology*
- *International radiology day = 8th November*

PARTS OF X-RAY TUBE

- **Glass Envelope:** Provides protected and vacuumated environment to the tube.
 - **Target window:** It is the thinning of glass in lower part of glass envelope which allows X-ray to come out of tube
- **Cathode:** Negatively charged electrode and consist of filament, supporting wires, and focusing cups
 - Filament:

An electric current is passed through the filament and it gets heated to a very high temperature (approx 2200°C) which makes the metal sufficiently violent to enable a fraction of free electrons to leave the surface despite net attractive pull of the lattice of the positive ions.

- **Anode:** it is the positively charged electrode and the most important part is target, which is usually made of tungsten. The electrons are repelled by the negative cathode and attracted by the positive anode. Because of the vacuum, they are not hindered in any way and bombarded the target with a velocity around half of the velocity of light. X-rays are produced when fast moving electrons are stopped by impact on a metal target. The kinetic energy of the electrons is converted into X-rays (1%) and into heat (99%).

- **The production of X-rays is largely because of two processes:**

- Interaction with the inner shell electron (k shell) a.k.a photoelectric effect resulting in productions of characteristics radiations.
- Interaction with the nucleus a.k.a Bremsstrahlung reaction. It is the most important reaction (80%) responsible for X-ray production in most of the tube except Mammography where photoelectric effect predominates

1. Most important part of cathode is filament.
 2. Mostly made up of tungsten emits electron by thermionic emission.

1. In photo electric effect maximum photon energy is directly proportional to the atomic no of target material and is independent of KV.

1. In Bremsstrahlung reaction maximum photon energy is numerically equal to the KV.

Two types of anode are available:

- Stationary
- Rotating

FILTER

- To block the low energy radiation
- To decrease radiation dose to the patient without effecting image quality
- Mostly made up of aluminum
- The target window also acts as an inherent filter in the tube.

Collimator

- Beam – restricting device
- It restrict the scattered radiation
- It also gives direction to the beam.

Grid

- Made up of lead
- These are parallel arranged lead stripes placed between patient and cassette
- Blocks scatter radiation from reaching to the film to improve image quality
- Radiation dose to the patient is slightly increased as the useful radiation are slightly blocked by the grid.

Cassette: un Conventional Radiography, It is a Screen Film System

- **Screen:** Calcium tungstate
- It converts X-ray into light

Film

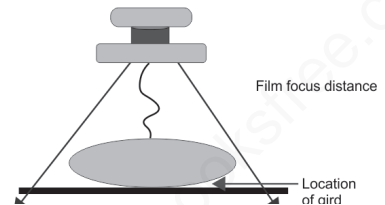
- Made of photosensitive material, mostly silver bromide
- **Single coated film:** If Agbr is present only on one surface, most commonly used
- Double coated film is used in screen film system and in dental radiography.

Contrast

- It is the ability to see something in relation to the background
- Influenced by both KVP and MAS
- Most important factor to influence contrast is KVP



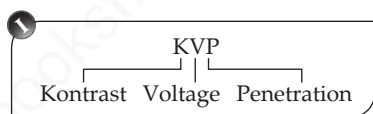
Note: In majority of cases, rotating anode is used because of better heat tolerant capacity
Except: Dental radiography and portable/mobile radiography, where stationary anode is used.



Film focal distance: Distance between X-ray tube and cassette.
For all radiography, this is 100 cm
Except: Chest X-ray (180 cm), to reduce the cardiac magnification.



- For penetration
 - KVP has to be changed
- For contrast
- Both KVP and MAS are important
 - ↑ KVP → ↓ contrast
 - ↑ MAS → ↑ contrast



| Kilo volt peak (KVP) | Milli ampere second (MAS) |
|---|---|
| • Related with voltage | • Current x exposure time |
| • Directly proportional to the energy of the beam | • No effect on energy |
| • Directly proportional to penetration | • No effect on penetration |
| • Inversly proportional to contrast | • Determines the number of photon in a given area |
| | • Determines the background blackening |
| | • Directly proportional to contrast |

RADIATION UNITS

Exposure Dose

- The unit of radiation exposure is the Roentgen (R), defined as an amount of X-rays or gamma rays that will liberate a charge of 2.58×10^{-4} C/kg of air, under standard temperature and pressure
- The SI unit for radiation exposure is Coulombs/kg. Change dose = 2.58×10^{-4} C/kg.
- Conventional unit: Roentgen.

Radiation Absorbed Dose

- **The unit rad** is defined as the radiation necessary to deposit energy of 100 ergs in 1 gram of irradiated material.
- The SI unit for absorbed dose is Gray. One Gray is the amount of radiation necessary to deposit 1 joule of energy in 1 kg of material.
- 1 Gray = 100 rad.

Equivalent Dose

It represents the biological impact of various types of radiation.

- $H_T = W_R \times D$, where H_T is the equivalent dose, W_R is the quality factor and D is the absorbed dose in Rads or Gray.
- The radiation dose equivalent for which the unit was rem, has now been replaced by 'Sievert' in the SI units (système internationale).
- 1 Sievert = 100 rems.

1

| Dose | Conventional | SI Unit |
|--------------------|--------------|-------------|
| 1. Exposure dose | Roentgen | Coulombs/kg |
| 2. Absorbed dose | Rad | Gray |
| 3. Equivalent dose | Rem | Sievert |
| 4. Effective dose | - | Sievert |
| 5. radioactivity | Curie | Bacquerel |

1

| S no. | Types of radiations | quality factor |
|-------|--|----------------|
| 1 | X, gamma, or beta radiation | 1 |
| 2 | Alpha particles and multiple charged particles | 20 |
| 3 | Neutrons | 10 |
| 4 | High energy protons | 10 |

Effective Dose

- It assigns the various tissues/organs the proportional risk of stochastic effect to irradiation, compared to uniform whole body radiation by same equivalent dose.
- It takes into account Tissue Weighting Factor (WT) which depends on the susceptibility of a particular tissue to the stochastic effect by radiation. It is also expressed in Sieverts.
- $H_E = W_T \times H_T$, where H_E is the effective dose, H_T is the equivalent dose, and W_T is the tissue weighting factor. Equivalent dose \times Tissue wt-factor = effective dose.

SI unit: Sievert or milli sievert (mSv).

| Tissue | Weighting factor |
|--|------------------|
| Gonads | 0.2 |
| Active bone marrow, Colon, Lungs, Stomach | 0.12 |
| Bladder, Breast, Esophagus, Liver, Thyroid | 0.05 |
| Bone surfaces, Skin | 0.01 |

Harmful Effects of Radiation

- Ionization of molecule- Free radical generation – damage to DNA.
Note: M/C radiation side effect: Skin erythema.
- Be directly proportional to dose, i.e. deterministic (certainty) effects
 - Related with certainty to a known dose of radiation
 - Dose threshold exists
 - Severity is dose related
 - e.g. skin effects, epilation, lens opacities, etc.
- Not directly proportional to dose, i.e. stochastic effects.
 - Random events without threshold
 - Probability increases with dose
 - 'ALL OR NONE' phenomenon
 - Severity may not be dose related Dose-dependent/Deterministic side effect dose related severity dose threshold exist:
 - e.g. genetic side effects, teratogenicity, mutations, etc.

Radiation protection for patient

10-Day Rule:

- In a female of reproductive age group, any modality which gives ionising radiation should be performed with in first 10 days of menstrual cycle. (because there is no ovulation) – to prevent radiation to an undiagnosed pregnancy.

Radiation protections aims at eliminating the deterministic side effects and reducing the probability of stochastic side effects.

Pregnant occupational worker should not be exposed to more than 2 mSv of radiation applied to surface of her lower abdomen for the declared term of pregnancy which is equivalent to 1 mSv dose to the fetus.

- At doses in excess of 20–100 Gy to the total body, death usually occurs within 24 to 48 hrs from neurologic and cardiovascular failure. This is known as the **cerebrovascular syndrome**. Because cerebrovascular damage cause death very quickly, the failure of other systems do not have time to develop.
- Cerebrovascular syndrome
- 20–100 gray
- Death within 24–48 hours
- Other systems don't have time to develop failure.

At doses between 5 and 12 Gy, death may occur in a matter of days, as a result of the **gastrointestinal syndrome**. The symptoms during this period may include nausea, vomiting and prolonged diarrhea for several days, leading to dehydration, sepsis and death.

Gastrointestinal syndrome

- 5–12 Gray
- Death occurs in days
- Nausea, vomiting of diarrhea leading to dehydration, sepsis of death.

ALARA approach: As low as Reasonably achievable radiation dose. For patient

| | Occupation workers | | General public | |
|------|---------------------------------------|--------------------|-------------------------|--------------------|
| | Limit | Annual equivalents | Limit | Annual equivalents |
| ICRP | 20 mSv/yr over 5 years | 20 mSv | 1 mSv/yr over 5 years | 1 mSv |
| NCRP | Cumulative dose = Age in yrs x 10 mSv | 50 mSv | 5 mSv for 5-year period | 1 mSv |
| AERB | 100 mSv for 5-year period | 30 mSv | 1 mSv/yr for 5 years | 1 mSv |

Note: Radiation workers protect themselves from radiation by

- Aprons (made of lead) thickness = 0.5 mm (according to AERB, it should have at least lead equivalance of 0.25 mm). increase thickness, increases the weight of the apron.
- Lead-free apron: Tin, Antimony, and Bismuth.
- TLD (thermoluminiscent dosimeter): It is a badge which monitors radiation used by radiation worker.
- Checked every 3-month.


Amount of radiation exposure in a CT scan is dependent on the body part to be examined for example in CT head, it is 2.3 MSV and in CT abdomen it is 10 MSV.

A CT chest has radiation exposure of almost equal to 400 chest radiographs.

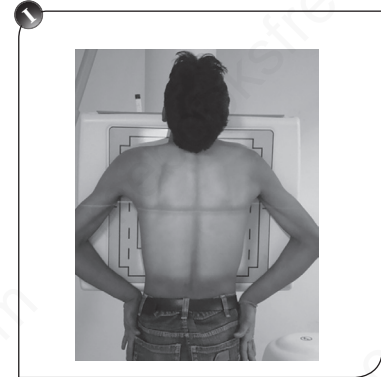

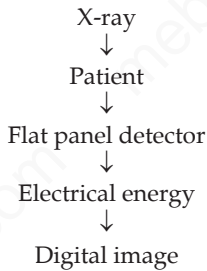
Digital Radiography

- Digitizing conventional film
- Computed radiography (CR)
- Direct radiography (DR)

Computed Radiography



Direct Radiography



| | Computed radiography (CR) | Digital radiography (DR) |
|-----------------------|--|--|
| Steps required | <ul style="list-style-type: none"> • Load cassette • Position patient • Position tube • Perform exposure • Transport cassette • Process cassette • Assess image quality end examination | <ul style="list-style-type: none"> • Position patient • Position tube • Perform exposure • Image is sent to viewing station • Assess image quality • End examination |
| Advantages | <p>Manipulation and positioning of image receptor for cross table projections is possible (useful in trauma)</p> | <ul style="list-style-type: none"> • Relatively faster workflow due to elimination of cassettes |
| | | <ul style="list-style-type: none"> • Shorter turnaround time for viewing image |
| Disadvantages | <ul style="list-style-type: none"> • Slower, more complex workflow | <ul style="list-style-type: none"> • Higher costs |

At total-body doses between 2 and 8 Gy, death may occur several weeks after exposure and is due to effects on the bone marrow, which results in the **hematopoietic syndrome**. The full effect of radiation is not apparent until the mature hematopoietic cells are depleted. Death from the hematologic damage occurs at about 20 to 30 days after exposure and the risk of death continues over the next 30 days. Clinical symptoms during this period may include chills, fatigue and petechial hemorrhage.

Hematopoietic syndrome

- 2-8 Gray
 - Death occurs in several weeks
- Usually due to effect on bone marrow
- Symptoms usually are chills, fatigue and petechial hemorrhage.

Contd...

Contd...

| | Computed radiography (CR) | Digital radiography (DR) |
|--|--|--------------------------|
| | <ul style="list-style-type: none"> Possibility of repetitive motion injuries due to long-term cassette handling | |

Mammography

Mammography uses lower kV (for higher image contrast) and higher mA (for shorter exposure times) compared with the technique for chest and abdominal examinations.

- Small focal spot size (0.2–0.5 mm)
- Beryllium Window
- Target-Filter combination
 - Molybdenum (preferred); Rhodium; Tungsten
 - Mammography is usually done after 40 years because in Young age, breast has dense glandular parenchyma. Where it is difficult to see the lesion on mammography and glandular tissue is more sensitive to radiation.
 - USG is done for palpable lesion and done to differentiate between solid and cystic lesion and to rule out breast abscess.

Two Views

- Mediolateral (more important because of the more coverage area)
- Craniocaudal

Note: Mammography has 10–40 times more radiation exposure than CXR.

BIRADS classification for mammography lesion: (Breast imaging Reporting and systematic).

| Grade | Interpretation | Management |
|-------|---------------------------|--|
| 0 | Incomplete evaluation | Complete it |
| 1 | Normal | None (CRS) continue routine screening |
| 2 | Benign calcified fibro | None (CRS) |
| 3 | Probably benign (< 2%) | Short follow-up |
| 4 | Suspicious | Indeterminate |
| 5 | Highly suspicious (> 15%) | Biopsy |
| 6 | Biopsy proven malignancy | To look for contralateral breast and multicentric disease in the same breast |

1 In younger age, MRI is the preferred screening test.

- **MRI:** Best investigation for breast implant.

Ultrasound

| Advantage | Disadvantage |
|--|--|
| <ul style="list-style-type: none"> • Real-time image • No radiation • Portable • Easy available • Cheap | <ul style="list-style-type: none"> • Operator dependent |

- Works on the principal of **pizeoelectric effect**: generation of sound waves by passing electricity. The electricity is passed through crystal, vibration of which generates sound waves.
- Most commonly used crystal: Lead zirconate Titanate (PZT)
- Medical used frequency: 2–20 MHz
- A handheld transducer is applied to the body. This transducer both sends US waves into the body and receives reflected sound waves. This information is communicated via cable to the US scanner, and the image is generated on a monitor.
- **Real-time B-scans** allow body structures which are moving to be investigated.

Note: Posterior structure better seen on transesophageal echocardiography.

Note: 5-layer of GIT seen on endoscopic US.

Clinical Transducer

For thick, deep body parts (Abdomen, obstetric) = 3.5 to 5 MHz.

For small body parts (Orbit, Thyroid, breast) = 7.5 to 10 MHz.

Intracavitary Transducers (7.5–20 Hz)

Endovaginal—Pelvis

Endorectal—Prostate

Transesophageal—Heart

Intravascular—Blood vessels

Endoscopic ultrasound—Pancreatic lesion, local staging of esophageal cancer, rectal cancer.

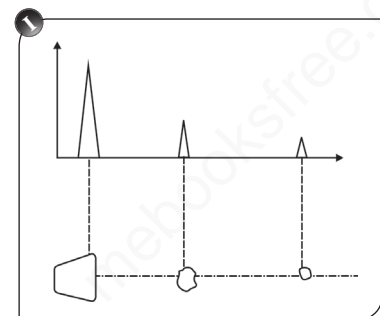
Methods of Display

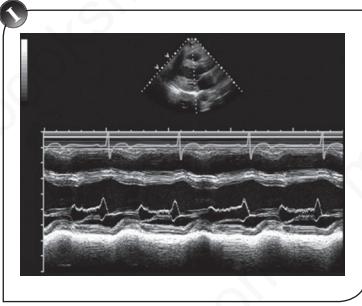
- **A-Mode (AMPLITUDE)**: Amplitude of the returning signals is plotted in a graphical form against their distance from transducer/depth. Commonly used for orbital biometry.

| A | B |
|---------------------|----------------------|
| 2-7 MHz | 7-15 MHz |
| Low-frequency probe | High-frequency probe |

- Lower the frequency of ultrasonography probe more deep it penetrate to see (i.e. more depth).
- More frequency of probe of USG better will be resolution.

- Note:**
- For all thick and deep body parts: Low-frequency probe is used
 - For all thin and superficial body parts: High-frequency.





- **B-Mode (BRIGHTNESS):** The amplitude of returning signals is given grey scale value based on a scale and is represented in the display to form an image of the scan plane. Most commonly used mode
- **M-Mode (MOTION):** Detects any rhythmic motion occurring in the scan plane without any amplitude considerations. Used for valvular morphology and motion.

Nomenclature of USG Images

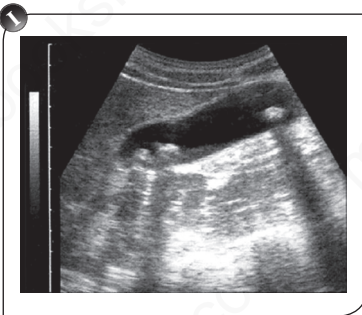
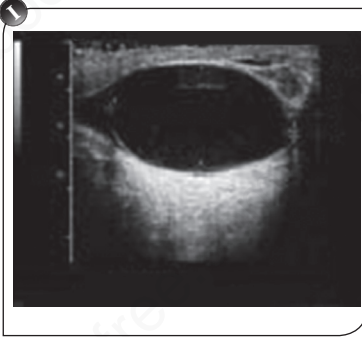
- Regions which reflect a lot of sound to the transducer are termed as *echogenic* or *hyperechoic* and by convention are viewed as bright or white areas.
- Regions which do not reflect many sound waves are termed as *hypoechoic* and are viewed as dark or black areas.
- The regions which have similar pattern to normal viscera or soft tissue are labeled as *isoechoic*.

Fat, calculus, bones, and stones are extremely echogenic on USG.

Fluid is absolutely black on USG and is termed as anechoic.

Posterior acoustic enhancement: Increased brightness beyond the objects that transmit a lot of sound waves, e.g. cysts.

Posterior acoustic shadowing has the opposite effect-decreased brightness seen beyond objects that reflect a great deal of sound. e.g. stones (refer to the image shown with B mode USG).



Ultrasonography is Investigation of Choice for

- Hydrocephalus in infants
- Retinal detachment
- Minimal pleural effusion
- Minimal pericardial effusion
- CHPS
- Gallstones
- Acute cholecystitis (although theoretically HIDA scan is best)
- Screening for Rotator cuff injuries (initial investigation)
- Renal colic in pregnancy
- Minimal ascites
- Pararenal fluid collection post renal transplant

- Obstetrics indications
- Scrotal pathologies
- Varicose veins
- DDH (developmental dysplasia of hip)

Advance Applications of USG

Doppler

Doppler US: For moving structure, i.e. blood. It can be used for

1. Presence/absence of flow
2. Direction of flow

Note: Blood flow toward the probe = Red

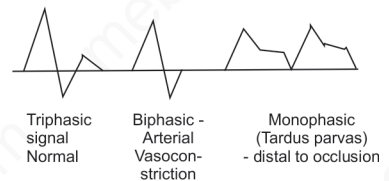
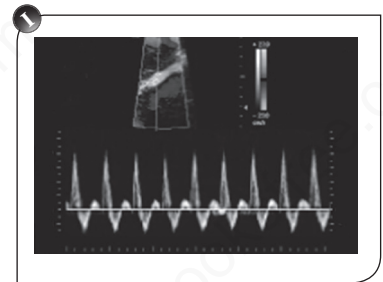
3. Blood flow away from probe = Blue

Note: Green color in Doppler is seen in turbulent blood flow due to mixing of red and blue

4. Velocity of flow
5. Pattern of flow

Doppler can be used to assess velocity of the blood flow which is important in assessing the stenosis in a vessel. As there is a stenosis, velocity increases at the point of stenosis.

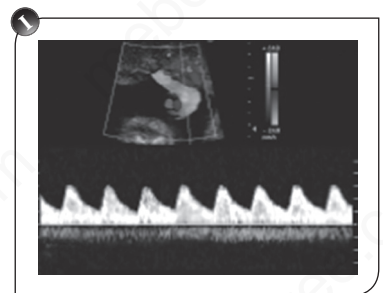
Note: the vessel transducer angle should be less than 60 degree for proper velocity calculation on USG.



Pattern of Flow

Every vessel in the body has a specific pattern of flow which can be detected on Doppler

- The peripheral arteries in the body has a high resistance due to peripheral vascular resistance and commonly shows triphasic pattern.
 - In case of arterial vasoconstriction, the peripheral resistance increase and flow becomes biphasic.
 - In case of peripheral vasodilation, the peripheral resistance decreases and flow becomes monophasic with pulsatility.
 - In case of arterial obstruction, there is significant loss of pressure and the flow distal to obstruction becomes monophasic (tardus parvus).
- The visceral arteries (hepatic artery, renal artery, umbilical artery) in the body has low resistance and usually has low resistance flow, which is monophasic pattern with pulsation.
 - In cases of IUGR, as there is increase in the placental resistance, diastolic flow decreases



Note: hepatic veins have triphasic pattern due to the pressure change in the RA and its continuity with it without any valve.

and the S/D ratio increases (normal S/D ratio is < 2.5 . It is increased to > 3.0 in IUGR).

- When the placental resistance increases further, diastolic flow decreases further and a time comes when the diastolic force becomes equal to the placental resistance and no flow is seen in doppler, this is called as absent diastolic flow and is a sign of severe IUGR.
- When the placental resistance is increased further, there is reversal of flow in diastole and it is the sign of impending fetal death.
- The veins in the body has continuous flow with out pulsations, a.k.a monophasic pattern without pulsations.

Elastography

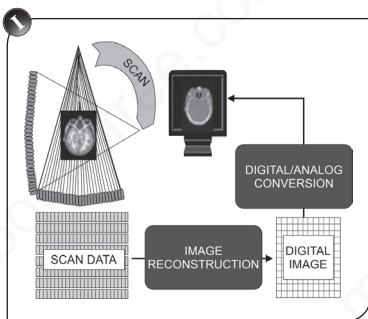
Elastography is a new method which applies a distorting force (stress) to a tissue to move it by few millimetres, and create an image of the tissue's response (strain) by comparing the two. In principle, any imaging method can be used: ultrasound has the advantage that the transducer can be used to apply the stress and of working in real time while magnetic resonance has also been used successfully.

For ultra-sound, the transducer is usually used to apply the stress manually and the strain is detected by tracking the speckle pattern as it changes during probe-induced distortion. The information used to create the images is similar to that gained from clinical palpation except that it is much more sensitive, especially to deeper structures. It has already found clinical applications in the breast, liver, and prostate, and is an active research area. The important uses of elastography include:

- Assessment of degree of fibrosis in liver
- To differentiate benign lesion from malignant lesion in liver, breasts, and prostate.

CT SCAN

The first CT machine used for clinical purposes, developed by the late Sir Godfrey Hounsfield, was installed at the Atkinson Morley Hospital, London, in the early 1970s. In the initial days only sequential acquisition was possible. In 1980s, the development of slip-ring technology enabled continuous revolution of the X-ray unit, which not only reduced the acquisition time per axial image to 1 sec, but also allowed helical



data to be acquired. The next step of development occurred in the late 1990s, when detectors were split into multiple thin rows along the z-axis to permit acquisition of multiple sections simultaneously (multidetector CT). This decreased acquisition time yet further and made it possible to routinely use thin sections. As a result, multidetector CT is nowadays able to provide near isotropic volumetric data sets in which spatial resolution is similar in all planes. 2000s saw the introduction of cardiac CT which is based on ECG-synchronization to freeze cardiac motion. The number of detector rows increased from 4 to somewhere between 64 and 320 rows, depending on the manufacturer. Rapid tube rotation (<0.3s) and dual-source systems with two X-ray tubes were developed to optimize cardiac imaging.

Basic Principle of CT is Linear Attenuation of X-Rays

- **CT No./HU value:** Numerical value, given to a tissue depending on degree of attenuation of X-ray by that tissue

| Substance | HU value |
|-----------|-------------|
| Air | -1000 |
| Fat | -50 to -100 |
| Water | 0 |
| Muscle | 10-40 |
| Blood | ~60 |
| Contrast | 130 |
| Bone | >400 |

- **Slice thickness:** Thickness of tissue scanned in one rotation

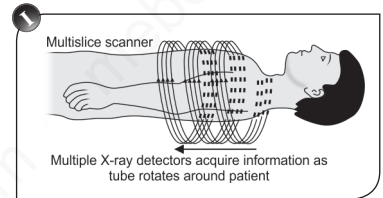
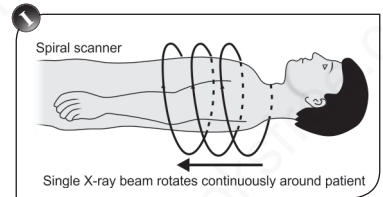
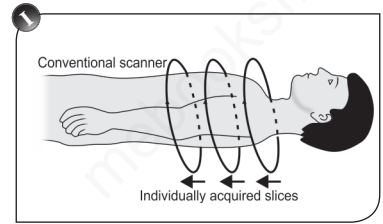
$$\text{Pitch} = \frac{\text{Table movement per rotation}}{\text{Beam collimation or slice thickness}}$$

$$\text{Scan length} = \text{Table movement during entire scan}$$

$$= \frac{\text{Table movement}}{\text{Rotation}} \times \text{no. of rotation}$$

$$= \text{Pitch} \times \text{beam collimation} \times \frac{\text{Total duration of scan}}{\text{Time taken in 1 rotation}}$$

- Increase in the pitch leads to decrease in the scan duration and radiation but reduces the scan quality.
- Decrease in the pitch leads to increase in the scan duration and radiation but improves the scan quality.



Note:

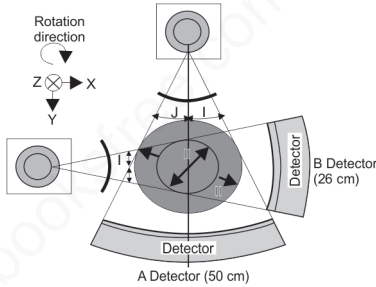
- More H.V. value causes more white (Hyperdense)
- Less H.V. value cause more black (Hypodense)

$$\text{HU} = 1000 \times \frac{\mu - \mu_{\text{water}}}{\mu_{\text{water}} - \mu_{\text{air}}}$$

As you increase the number of detectors, the scan quality improves and time taken to complete the scan reduces.

Advantage of Multislice CT/Multidetector CT

- Faster acquisition
- Coverage of larger area
- Less movement artefacts
- Isotropic multi-planar reformats
- Improved vascular and cardiac imaging
- Potential for faster throughput of patients.



DUAL SOURCE CT

Two X-ray sources are used operating at different potential (Kv). The interaction between the two with tissues in the body is different and by comparing those differences in the two images, radiologists can differentiate, characterize, isolate and distinguish body tissues and fluid, leading to breakthroughs in medical imaging.

| Applications | Bottom-line inference |
|---|---|
| Pulmonary nodule characterization | Not useful Useful, present application |
| Fatty liver quantification for liver donors | Limited data Useful (more validation needed) |
| Characterization of liver lesions | Further data needed |
| Characterization of an adrenal mass | Few data available Useful results from initial patient studies |
| Coronary in-stent stenosis | More data needed |
| Bone subtraction for CTA post processing | MRI is superior to CT in this respect |
| Kidney-stone differentiation | Better tests are available |
| Iron deposition in liver | |
| One densitometry | |

Advantage

- Ability to scan at any heart rate
- No need to use beta-blockers
- Better temporal resolution - 83 ms
- Trauma, oncology, obese patient

HIGH RESOLUTION CT SCAN (HRCT)

It is a type of CT technique done for some specific diseases like

- Interstitial lung disease
- Bronchiectasis

- Miliary tuberculosis
- Temporal bone evaluation
- CSF leaks

Principle

- Thin slice-thickness or collimation
- Narrow field of view
- Bone algorithm for image reconstruction

RADIATION DOSE IN A CT SCAN

CTDI (CT Dose Index): CT dose index (CTDI) is a standardized measure of radiation dose output of a CT scanner which allows the user to compare radiation output of different CT scanners.

CTDI represents the average absorbed dose, along the z-axis, from a series of contiguous irradiations. It is measured from one *axial* CT scan (one rotation of the X-ray tube), and is calculated by dividing the integrated absorbed dose by the nominal total beam collimation. The CTDI is always measured in the axial scan mode for a single rotation of the X-ray source, and theoretically estimates the average dose within the central region of a scan volume consisting of multiple, contiguous CT scans [Multiple Scan Average Dose (MSAD)] for the case where the scan length is sufficient for the central dose to approach its asymptotic upper limit.

Dose Length Product (DLP)

$$DLP \text{ (mGy-cm)} = CTDI_{vol} \text{ (mGy)} \times \text{scan length (cm)}$$

The DLP reflects the total energy absorbed (and thus the potential biological effect) attributable to the complete scan acquisition. Thus, an abdomen-only CT exam might have the same CTDI_{vol} as an abdomen/pelvis CT exam, but the latter exam would have a greater DLP, proportional to the greater z-extent of the scan volume.



Radiation dose depends on tube current (amperage), slice scan time, and tube peak kilovoltage.

MRI

Magnetic resonance imaging (MRI) is a non-invasive method of mapping structure and various aspects of function within the body by producing images by the virtue of gyromagnetic property of protons, with the greatest advantage of not using ionizing radiation for imaging.

Principle of MRI: Nuclear magnetic resonance: Purcell and Bloch

Invention of MRI: Lauterbur and Mansfield

Functional MRI: Ogawa and Rosen

Magnetic resonance is a phenomenon whereby the nuclei of certain atoms, when placed in a magnetic field, absorb and emit energy at a specific or resonant frequency.

Nuclei suitable for MRI contain odd no of protons and/or neutrons. Almost all clinical MR images are produced using the simplest of all nuclei, that of hydrogen (comprising a single proton), which is present in virtually all biological material and exhibits relatively high MR sensitivity.

Parts of MRI

- Maxwell Coil - Gradient coil used to create magnetic field gradients along the direction of the main magnetic field
- Radio frequency coils: to generate stronger magnetic field along the scan field.
- Faraday cage/shield/Hoffman Box – blocks out external static electric fields. Made up of copper [Cu]
- Superconductors – Electromagnets (determines the strength of magnet) measured in tesla.

How Image is Acquired in MRI

- In the absence of magnetic field all protons have random movement
- Under the influence of magnetic field, alignment of proton takes place
- Realignment occurs under the influence of radiofrequency pulse
- After switching off the radiofrequency pulse, the atoms return to their original position and release energy in the form of electrical voltage signal
- When proton releases energy to surrounding lattice, it is called as spin lattice relaxation or T1 relaxation
- When proton releases energy to the surrounding spin, it is called as spin-spin relaxation or T2 relaxation
- This electrical signal (produced in receiver coil) is **digitized and analyzed** in a **computer**, to produce **MR images**.

| | TR (Time to relaxation) | TE (time to echo) |
|----|-------------------------|-------------------|
| T1 | low (< 1000 ms) | low (< 20 ms) |
| T2 | high (>2000 ms) | high (> 50 ms) |

Using T1 and T2 relaxation time, two types of images are broadly acquired using this principal; T1 weighted MR and T2 weighted MR.

Contraindications of MRI

It is a common saying that MRI means “metal results in injury” however it is not true in current scenario and there are many metallic devices compatible with MRI and students should be aware of those, particularly devices made up of TITANIUM which are very much compatible with MRI.

Few important devices or conditions where MRI is usually contraindicated are:

- Cardiac pacemakers
- Cochlear implants
- Intraocular Metallic foreign body
- Electronically, magnetically, and mechanically activated implants
- Ferromagnetic or electronically operated active devices like defibrillators
- Aneurysmal clips
- Prosthetic heart valves
- Insulin pumps and nerve stimulators
- Stapedial implants
- Claustrophobia
- First trimester of pregnancy

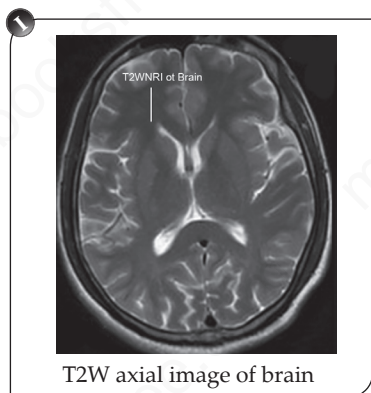
Note: even in the devices mentioned above, MRI can be performed depending upon the make of the device, e.g. some pacemakers are MRI compatible at lower strength magnet, i.e. up to 1.5 Tesla so it is always advised to check the compatibility of the device before saying NO to MRI.

MRI can be Safely Performed in

- Orthopedic implants (usually made of titanium). in cases of implants made of stainless steel, MRI can still be done however, heating is a problem so it is usually recommended for a shorter time and on a lower strength magnet. In permanent tattoos also because of the heavy metal dyes, heating may be an issue.
- Pregnancy after 1st trimester. Safety profile of MRI is not established in first trimester so, should not be done in 1st trimester.

| | T1-weighted MR | T2-weighted MR |
|-------------|--|--|
| Information | Anatomical Information | Pathological information |
| CSF | Black | White World war 2 (WW2) Water is white on T2 |
| Brain | Gray matter-gray White matter-white | Gray matter-white White matter-gray |
| Pathologies | Mostly black (Hypointense) | Mostly white (Hyperintense) |

| Things bright on T1W | Dark on both T1W & T2W |
|----------------------------------|---|
| Fat | Air |
| Hemorrhage | Flowing blood (on SE/FSE images) |
| Proteinaceous substances | Cortical bone |
| Melanin | Ligaments, tendons, and other dense fibrous tissues |
| Paramagnetic agents (gadolinium) | |



- Cholecystectomy clips, sternal sutures
- IUCD
- Non metallic foreign bodies
- Breast implants (investigation of choice is MRI)
- Pediatric patients (MRI is usually preferred because of lack of ionising radiation however, it is usually done under sedation due to uncooperative behavior)
- Coronary stents usually drug eluting stents are used and MRI can be done after 3 months.

SPECIAL SEQUENCES OF MRI

FLAIR: Fluid Attenuated Inversion Recovery Sequence (Flair = T2-water)

It is type of T2 weight MRI where the water is suppressed to make pathology more visible. it is predominantly used at places where water is the confounding factor and limiting the contrast, e.g. brain.

Uses

- For better appreciation of pathologies in brain (most of the pathology being white)
- To differentiate arachnoid cyst from epidermoid cyst (arachnoid is a CSF filled cyst and becomes black on FLAIR, where as epidermoid is not).

STIR (Short Tau Inversion Recovery Sequence)

STIR can be easily remembered as T2- Fat means pathology will remain white whereas Fat will become black.

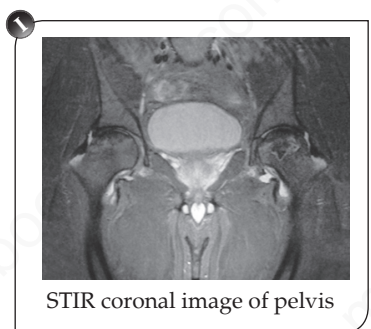
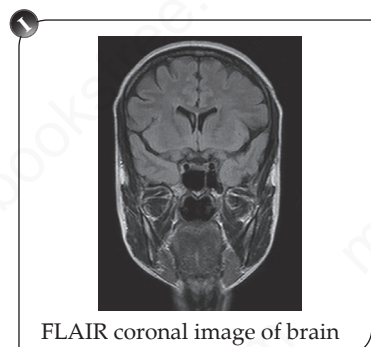
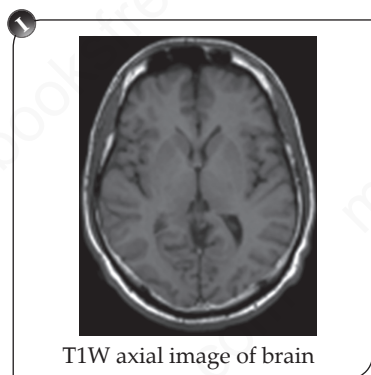
It is predominantly used at places where fat is the confounding factor and limiting the contrast, e.g. rest of the body and musculoskeletal imaging.

Uses

Identification of bone marrow edema in diseases like stress fracture, avascular necrosis, Perthes disease, etc. for better appreciation of diseases in body where presence of fat is reducing the contrast due to background whiteness.

Contrast Enhanced MRI (CEMRI)

Gadolinium containing compounds are most commonly used contrast agents in MRI.



Presence of gadolinium caused reduction in both T1 and T2 relaxation time which leads to increases in signal on T1-weighted MRI and decreases in signal on T2 weighted MRI. As human eyes appreciate white color better, post contrast MRI images are always acquired as T1-weighted MRI.

MRCP (Magnetic Resonance Cholangiopancreatography)

MRCP images are heavily T2-weighted sequences which demonstrate fluid-filled structures as areas of very high signal intensity and are very commonly used to show the biliary and pancreatic ducts in magnetic resonance cholangiopancreatography (MRCP). Being non-invasive and no need of external contrast, it is considered as a preferred investigation to diagnose pathologies of biliary duct and pancreatic duct in comparison to diagnostic endoscopic retrograde cholangiopancreatography (ERCP).

MR Angiography

Visualization of vessels using MRI.

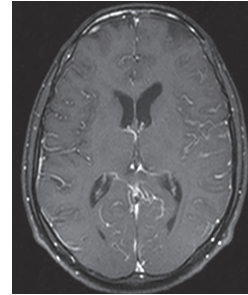
This technique is unique due to the fact that the beautiful angiographic images can be obtained without external administration of contrast. The technique used in MRI for angiography is called TOF (time of flight). it is a very commonly used angiographic technique now days and is the preferred imaging technique to assess renal artery stenosis and an intracerebral aneurysm. It is also preferred investigation to look for carotid artery stenosis.

Diffusion Weighted MRI (DWI)

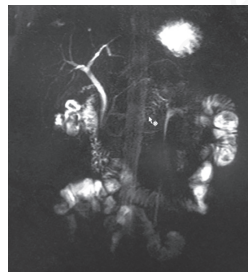It is a special type of MRI technique which assesses the random (brownian) motion of the water molecule, which is a normal phenomenon. In some disease, there is reduction in the brownian motion of the water molecule, which is called as restricted diffusion. Areas of restricted diffusion are seen as white on DWI.

Common Causes of Restricted Diffusion

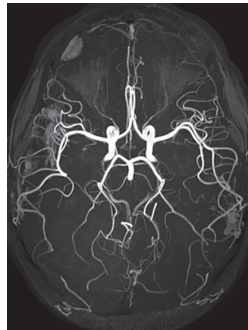- Acute ischemic infarct (most common cause)
- Abscess
- High cellular tumors
- Epidermoid cyst



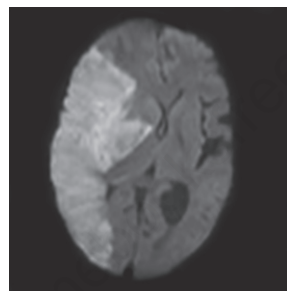
CEMRI image



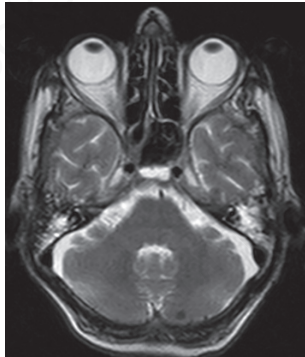
MRCP image



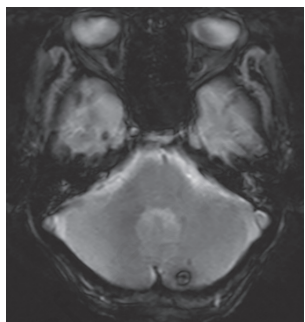
TOF MR angio image



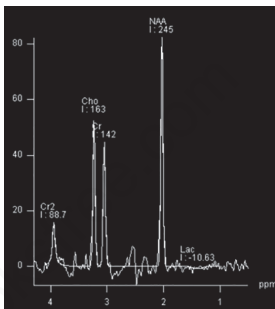
DW image



Axial T2 image showing a hypointense lesion in (L) cerebellar hemisphere



The lesion becomes enlarged in size on Gradient echo images and is much better appreciated



Spectroscopy of brain showing NAA peak in case of Canavan's disease

Gradient Echo Images

Used to see calcification and hamorrhage on MRI.

Spectroscopy

It is a new technique of MRI to assess certain metabolites in the body tissues. Metabolic changes occur earlier than the structural changes and Since routine MRI picks up structure changes, new techniques have been developed for the early diagnosis of the diseases. Commonly studied metabolites are

- N acetyl asperate (NAA)
 - neuronal marker
 - assess neural integrity
 - decrease in most of the brain disorders except Canavan's disease
- Choline
 - present in cell membrane
 - marker of cell membrane turnover
 - increased in malignancies
- Creatine
 - Present in ATP
 - Marker of energy stores
 - Reference marker, used to see the relative concentration of metabolites as it is a stable workers and doesn't change much during diseases.
- Lipid peak. Tuberculomas are rich in caseous necrosis and presence of lipid peak is a useful way to differentiate tuberculoma from cysticercosis which will be seen in tuberculoma and not in neurocysticercosis.

MRI is Usually a Preferred Investigation for

- For all brain tumors (contrast enhanced MRI)
- For extent of pancoast tumor (due to neural involvement)
- Ventricular function (most accurate investigation)
- Posterior mediastinal mass (neurogenic in origin)
- Bony metastais in spine (bone scan is preferred at other places)
- Chronic subarachnoid hemorrhage
- Traumatic paraplegia due to neural involvement
- Extent of pott's spine (for diagnosis Bx is the best)
- Stress fracture, Perthe's disease, avascular necrosis, early osteomyelitis (bone marrow edema)

- Pregnancy after first trimester (not for obstetrics problem but for other abdominal pathologies). For antenatal scanning, USG is still preferred over MRI
- Spinal cord pathologies
- Gynecological malignancies
- Uterine anomalies

| | MRI | CT Scan | USG |
|-------------------------------|--|--|---|
| Ionizing radiation | No | Yes Moderate - high radiation | No |
| Principal | Magnetic moment of protons (gyromagnetism) | Linear attenuation of X-rays | Piezo electric effect |
| Time for scanning | 10 minutes to hour | Less than a minute | Variable |
| Bony details | Cortical bone is not well seen but bone marrow is very well seen | Cortical bone is very well seen | Not well seen. Structure posterior to bone are not seen due to acoustic shadowing |
| Soft tissue structure | Very well seen and differentiated | Seen but not well characterized | Very well seen |
| Multiplanar capability | Images can be acquired in any planes | Scans are acquired in axial planes and later can be reconstructed in any planes on MDCT | Yes depending on the position of the probe |
| Real time imaging | Mostly not | No | Yes |
| Portable | Usually not | Usually not | Yes |
| Cost | Very costly | Costly | Cheap |
| Uses | <ul style="list-style-type: none"> • For neural tissues • For bone marrow • Cartilage • Ligaments • Tendons • Soft tissues | <ul style="list-style-type: none"> • Cortical bone • Acute hematoma in brain • Calculi • Calcifications • Air • Guiding biopsies in lung | Fluid containing structures Guiding biopsies |

Best MRI sequence to differentiate Epidermoid cyst/ Arachnoid cyst

- FLAIR
- DWI (DWI > FLAIR)

Paramagnetic substances reduced both T₁ and T₂ relaxation time on MRI.

Gadolinium does not cross BBB.

Risk of Nephrogenic systemic fibrosis due to gadolinium is seen only in patients suffering from chronic kidney disease.

CONTRAST AGENTS IN RADIOLOGY

MRI CONTRAST AGENTS

Gadolinium containing compounds are considered more nephrotoxic than iodinated compounds in equimolar concentration; however, the amount of gadolinium given is much less than iodinated contrast agents; hence, nephrotoxic side effects are not seen.

Gadolinium chelates are most commonly used contrast agents in MRI studies. Due to lack of iodine, these compounds are relatively safe without any significant risk of anaphylaxis or allergic reactions unlike iodinated contrasts.

Being paramagnetic in nature, they predominantly act by reduction of the T1 and T2 relaxation time.

The most common side effects of these agents are mild headache and a metallic taste.

Pregnant patients should not receive gadolinium chelates. Many of the agents are known to be able to cross the blood-placental barrier, and their effect on the fetus is unknown.

Nephrogenic systemic fibrosis is a scleroderma like dermatopathy that is known to precipitate due to use of gadolinium chelates in patients with compromised renal function.

Risk factors are

- Increased dose of gadolinium
- Repeated doses
- Use of linear gadolinium chelates particularly gadodiamide (omniscan).

European Guidelines for Prevention of Nephrogenic Systemic Fibrosis

Patients at a high risk for nephrogenic systemic fibrosis

- Chronic kidney disease (CKD) 4 and 5 (GFR <30 mL/min), including those who require dialysis and those who have reduced renal function who have had or are awaiting renal transplant.

Low Risk

- CKD 3 (GFR 30–59 mL/min) and
- Children younger than 1-year-old, because of their immature renal function.

Not at risk

- Normal renal function

Contrast agents with highest risk for NSF

- Gadodiamide
- Gadopentetate dimeglumine
- Gadoversetamide

The use of these agents is contraindicated in patients who have CKD4 and 5 (GFR <30 mL/min), including those who require dialysis and patients who have reduced renal function who have had or are awaiting kidney transplantation.

They should be used with caution in patients who have CKD 3 (GFR 30–59 mL/min) and children younger than 1-year-old.

Serum creatinine (eGFR) levels should always be measured before using these three agents.

The intermediate-risk group includes the following agents:

- Gadobenate dimeglumine
- Gadofosveset trisodium
- Gadoxetate disodium

The determination of eGFR levels is not mandatory before using these agents.

The low-risk group includes the following agents:

- Gadobutrol
- Gadoterate meglumine
- Gadoteridol

The measurement of eGFR levels before administration is not mandatory.

USG Contrast Agents

- Gas filled microbubbles with diameter ranges from 0.1 to 10 μm .
- Inert gas enclosed in a phospholipidic, albumin, or polymer shell.

MOA

- Increases the backscattering echo intensity, proportional to the change in acoustic impedance between the blood, and the gas making the bubbles.
- Seen as a increase in color, power and spectral Doppler signal strength or gray scale image intensity.
e.g. Albumex, levovist, echogen.

Uses

- In the liver
 - Characterization of focal liver lesions
 - Can detect flow in portal vein or collaterals in patients with cirrhosis
 - Improves evaluation of TIPSS stent for patency and stenosis

- Small intrahepatic collaterals in patients with Budd-Chiari syndrome
 - Better visualization of vessels in doppler.
- Note:** At least 100 mL of air required to cause air embolism but in USG-contrast we give only 0.5 mL air.

Iodinated Water Soluble Contrast Media

| | Iodinated water soluble contrast agents | | | |
|----------------------------|--|---------------|---|--|
| Name of the contrast agent | Ionic monomers | Ionic dimers | Non-ionic monomers | Non-ionic dimers |
| Iodine particle ratio | 3:2 | 6:2 | 3:1 | 6:1 |
| Osmolality | HOCM | LOCM | LOCM | IOCM |
| e.g. | (URO-GRAFFIN, GASTRO-GRAF-FIN)- Diatrizoate -lothalamate | -lox-aglate | -Iohexol (IOHEX-OL) -Iomeron -Iopamidol -Ipromide -Ioversol -Xenetix | -Iodixanol (VISI-PAQUE) |
| Uses | Preferred for non vascular use | Not available | Most preferred contrast for vascular administration | -The best for patients with associated renal disease |

Contrast Reactions

- Idiosyncratic anaphylactoid reactions (DOC is adrenaline)
- Non-idiosyncratic reactions.

Contrast-induced Nephropathy

Contrast-induced nephrotoxicity (CIN) is a sudden deterioration in renal function following the recent intravascular administration of iodinated contrast medium in the absence of another nephrotoxic event.

Diagnosis

There are no standard criteria for the diagnosis of CIN; criteria used in the past have included percent change in

Adrenaline is usually given through I/M or deep S/C route in patients of anaphylaxis because of risk of arrhythmia with I/V adrenaline unless patients is in severe hypotension when I/V adrenaline is given.

the baseline serum creatinine (an increase of variously 25% to 50%) and absolute elevation from baseline serum creatinine (e.g., an increase of variously 0.5 to 2.0 mg/dL). One of the most commonly used criteria has been an absolute increase of 0.5 mg/dL.

Pathogenesis

The exact pathophysiology of CIN is not understood and the Nephrotoxicity of contrast media is likely to be due to decreased renal perfusion due to renal vasoconstriction due to high osmolality of the contrast media.

Symptoms: Usually asymptomatic. Creatinine peaks in 3–5 days. In severe oliguric patients: peaks in 5–7 days

Risk Factors for CIN

- Pre-existing renal impairment (S.creat > 1.3 mg/dL, GFR < 60 mL/min)
- Dehydration
- CHF
- Use of nephrotoxic drugs (NSAID, aminoglycosides)
- Hypersensitivity disease (multiple myeloma)
- Hypertension
- Hyperuricemia (as in active gout)
- Proteinuria (> 0.5 gm/dL)
- DM, age > 70 years

Most effective way to prevent CIN is adequate hydration of the patients with I/V normal saline.

Prevention of Contrast Induced Nephropathy in High Risk Patients

- **Avoidance of Iodinated Contrast Medium:**
- **Contrast media selection:** Increased osmotic overload on the diseased kidney is considered to be the major etiology of CIN so; these can be significantly reduced by substituting IOCM/LOCM for the very hypertonic HOCM.
- **Hydration:** Adequate hydration is considered to be the single most effective way to prevent CIN. The ideal infusion rate and volume is unknown. One possible protocol would be 0.9% saline at 100 mL/hr, beginning 6 to 12 hours before and continuing 4 to 12 hours after intravascular iodinated contrast medium administration. Oral hydration has also been utilized, but with less demonstrated effectiveness.
- **Sodium bicarbonate:** It has been found to be useful in prevention from CIN according to some studies.
- **N Acetyl Cystine:** The role is controversial. There is evidence that it reduces serum creatinine in normal

volunteers without changing cystatin-C (cystatin-C is reported to be a better marker of GFR than serum creatinine). This raises the possibility that N-acetylcysteine might be simply lowering serum creatinine without actually preventing renal injury. N-acetylcysteine should not be considered a substitute for appropriate pre-procedural patient screening and adequate hydration.

- **Diuretics: Mannitol and Furosemide:** There is no reported benefit and neither mannitol nor furosemide is recommended for CIN risk reduction.
- **Other Agents:** The evidence for other theoretically renal-protective medications, such as theophylline, endothelin-1, and fenoldopam is even less convincing. Use of these agents to reduce the risk of CIN is not recommended.
- hemodialysis has not shown to be of much effect in prevention from CIN. hemofiltration has some benefit.

Patient on Metformin

Remember: Metformin + Chronic Renal Insufficiency + I/v contrast = Lactic Acidosis

| Category 1 | Category 2 | Category 3 |
|--|--|--|
| Normal renal function with no known co-morbidities No reason to discontinue Metformin | Normal renal function with known co-morbidities +, then suspend Metformin for 48 hrs If the patient had normal renal function at baseline, was clinically stable, and had no intercurrent risk factors for renal damage (e.g. treatment with aminoglycosides, major surgery, heart failure, sepsis, repeat administration of large amounts of contrast media), metformin can be restarted | Renal dysfunction then suspend Metformin for 48 hrs and restart only if repeat KFT is normal |

BARIUM STUDIES

Barium sulfate is commonly used for evaluation of GIT because it is an inert substance and not absorbed from the GIT. It also causes mucosal coating and helps in assessing mucosal details.

- **Barium swallow:** done for dysphagia (to rule out stricture or mass) replaced by endoscopy for these indications. Now commonly done for motility disorder.
- **Barium meal:** abdominal pain (to rule out gastric or duodenal ulcer disease), replaced by endoscopy.
- **Small bowel follow-through:** diarrhea or constipation (to rule out Crohn's disease or other small bowel pathologic conditions). Replaced by barium enteroclysis commonly called as small bowel enema and now a days with another technique called as CT enterography.
- **Barium enema:** rectal bleeding (to rule out a polyp or mass). Still performed but at some places, CT virtual colonoscopy is done.

Contraindications of Barium Sulfate in GIT Studies

- Small bowel obstruction (ionic contrast are preferred)
- Intestinal perforation (ionic contrasts are preferred)
- Tracheoesophageal fistula (non ionic contrasts are preferred because of the risk of pulmonary edema with ionic contrast due to very high osmolarity).

Myelography

- Contrast agent is injected into the SUBARACHNOID space following a lumbar puncture.
- Non ionic contrast agents are preferred due to the risk of arachnoiditis with previously used contrast agents.
- Most common side effect of myelography is headache
- Most severe side effect is arachnoiditis.

QUESTIONS

1. **CT or Hounsfield numbers depend upon:**
 - a. Mass density
 - b. Electron density
 - c. Atomic number
 - d. Atomic mass
2. **Which of the following statement is true?**
 - a. By reducing KVP by 50% radiation dose is reduced to half
 - b. In pediatric patients dose should be reduced
 - c. CT dose index is not useful for control exposure in multislice CT
 - d. kV has no control over CT dose index
3. **Investigation of choice in parathyroid pathology is:**
 - a. CT scan
 - b. Gallium scan
 - c. Thallium scan
 - d. Tc-thallium subtraction scan
4. **Which artery is dissected most commonly following arteriography by femoral route?**
 - a. Celiac trunk
 - b. Superior mesenteric artery
 - c. Inferior mesenteric artery
 - d. Gastroduodenal artery
5. **Earliest investigation for diagnosis of Ankylosing spondylitis:**
 - a. MRI STIR sequence
 - b. Bone scan
 - c. CT scan
 - d. X-ray
 - e. USG
6. **How much area is covered by spiral CT in 30 seconds?**
 - a. Entire organ
 - b. Entire abdomen
 - c. Entire trunk
 - d. Whole body
7. **In CT scan, Hounsfield units depends on:**
 - a. Electron density
 - b. Mass density
 - c. Effective atomic number
 - d. Linear attenuation coefficient
8. **X-ray view of choice for lumbar spondylosis is/are:**
 - a. PA view
 - b. PA view
 - c. Lateral view
 - d. Left oblique view
 - e. Right oblique view
9. **High resolution CT of the lung is a specialized CT technique for greater detail of lung parenchyma and it utilizes:**
 - a. Special lung filters
 - b. Thick collimation
 - c. Bone algorithm for image reconstruction
 - d. Large field of view
10. **Which of the following is non-ionising radiation?**
 - a. X-ray
 - b. β -rays
 - c. α -rays
 - d. Microwave
 - e. γ -rays
11. **Time sector scanning of neonates is preferred because of the following reason. Most practical reason:**
 - a. Open fontanelles
 - b. Inexpensive
 - c. Children more co-operative
 - d. Better resolution
12. **PET stands for:**
 - a. Positive electron tomography
 - b. Proton-electron therapy

- c. Positron emission tomography
d. Photon emitting tomography
13. **What modification is needed for proper radiographic image in a heavy bony built person?**
a. ↑ed ma
b. ↑kvp
c. ↑ed exposure time
d. ↑ed developing time
14. **Maximum radiation exposure occurs in:**
a. Bone scan b. X-ray
c. MRI d. CT scan
15. **USG is definitive investigation of:**
a. Vasa previa
b. Abruptio placenta
c. Placenta previa
d. Imperforate hymen
16. **Investigation of choice in whole body imaging in metastasis is:**
a. Magnetic resonance imaging
b. Angiography
c. Venography
d. CT scan
17. **Gyromagnetic property of proton is seen in:**
a. MRI b. CT
c. PET scan d. USG
18. **Most reliable test for spinal tuberculosis:**
a. Raised ESR
b. PPD skin test
c. CT guided biopsy
d. MRI
19. **In magnetic resonance imaging, paramagnetic substances cause:**
a. Shortening of both T1 and T2 relaxation times
b. Shortening of T2 relaxation time only
c. Shortening of T1 relaxation time only
d. No effect on T1 or T2 relaxation times
20. **SI unit of absorbed dose of radiation is:**
a. Roentgen
b. Gray
c. Sievert
d. Coulomb
21. **Frequency of ultrasound waves in USG:**
a. 2000 Hz b. 5000 Hz
c. <2 MHz d. >2 MHz
22. **Which of the following is a non-iodine containing contrast?**
a. Gadolinium b. Visipaque
c. Iopamidol d. Diatrizoate
23. **In computed tomography (CT), the attenuation value are measured in Hounsfield units (HU). An attenuation value of '0' (zero) HV corresponds to:**
a. Water
b. Very dense bone structure
c. AIR
d. Fat
24. **The best contrast to perform an IVU in the contemporary era is:**
a. Iodinated ionic water soluble contrast
b. Iodinated nonionic water soluble contrast
c. Gadolinium based contrast
d. Lipidol
25. **All of the following are true about iodinated intravascular contrast media except:**
a. They are used in digital subtraction angiography
b. They are radio-opaque
c. They can cause anaphylactic reactions
d. They are used in magnetic resonance imaging
e. They are excreted mainly by the kidneys

26. **BIRADS stands for:**
- Breast Imaging reporting and data system
 - Best imaging reporting and data system
 - Brain imaging reporting and data system
 - Best imaging reporting and data system
27. **Doppler effect is due to:**
- Change in frequency in relation to the movement of source or observer
 - Change in attenuation
 - Change in absorption
 - Change in reverberation
28. **Diagnosis of pulmonary embolism is primarily made by:**
- Multidetector CT contrast
 - Angiography
 - Ventilation perfusion scan
 - CXR
29. **Alpha particle is similar to:**
- Electron
 - Proton
 - Neutron
 - Helium nucleus
30. **Neural tube defect is best detected by:**
- USG
 - Chromosomal analysis
 - Amniocentesis
 - Placentography
31. **Light rays and X-rays have same:**
- Velocity
 - Wavelength
 - Energy
 - Frequency
32. **The magnetic field in a MRI machine is measured in:**
- Hounsfield unit
 - Tesla
 - Watt/sec
 - None of the above
33. **The basic principle behind ultrasound probe technology is:**
- Piezoelectric effect
 - Photoelectric effect
 - Calorimetric effect
 - Raman effect
34. **PACS in medical imaging stands for:**
- Portal archiving common system
 - Photo archiving computerized system
 - Picture archiving communication system
 - Planning archiving communication scheme
35. **Wavelength of light is:**
- 400-700 nm
 - SOD-800 nm
 - 700-900 nm
 - 300-600 nm
36. **CAT was invented by:**
- Hounsfield
 - Roentgen
 - Cormack
 - Tesla
37. **The study using barium for small intestine is known as:**
- Barium meal follow through
 - Barium swallow
 - Barium enema
 - None of the above
38. **Which is not echogenic while doing ultrasonography?**
- Bile
 - Gas
 - Bone
 - Gallstones
39. **The dark areas in a conventional radiographic film are due to particulate deposits of:**
- Carbon
 - Iron
 - Silver
 - Copper
40. **IV contrast is not used in:**
- CECT
 - MRI
 - IVP
 - Myelography
41. **Maximum scattering in X-ray plate occurs in:**
- Carbon
 - Mercury
 - H⁺
 - Ca⁺⁺

42. **Radiation produced by nuclear decay/disintegration:**
a. Gamma rays b. X-rays
c. Alpha rays d. Cosmic rays
43. **Contrast used in CT:**
a. Gadolinium b. Technitium
c. Iodine d. Chromium
44. **Investigation of choice to see gallbladder:**
a. CT
b. USG
c. Plain X-ray
d. Oral cholecystogram
45. **Radiocontrast is contraindicated in all except:**
a. Renal failure
b. History of previous severe allergic reaction
c. Dehydration
d. Morbid obesity
46. **The wavelength of X-ray is:**
a. Greater than that of light
b. Lesser than that of light
c. Equal to that of light
d. None of the above
47. **Slice of tissue X-rays is:**
a. Tomography
b. Mammography
c. Contrast studies
d. All of the above
48. **Contrast agent used in PET scan is:**
a. FDG
b. Gallium
c. Gadolinium
d. Iodine
49. **In which of the following form of imaging, harmonic imaging is related:**
a. Sonography
b. Digital radiography
c. MRCP
d. Nuclear imaging
50. **Not a contraindication to MRI is:**
a. Cochlear prosthesis
b. Foley's catheter
c. Penile implants
d. Metallic intraocular implants
51. **The CT scanner room are coated with:**
a. Lead b. Glass
c. Tungsten d. Iron
52. **"Time of Flight" technique is employed in:**
a. Spiral CT
b. MR angiography
c. CT angiography
d. Digital radiography
53. **Which of the following is not ionizing?**
a. Beta radiation
b. Alpha radiation
c. Gamma radiation
d. UV radiation
54. **USG wave travel in human body at the rate of:**
a. 1500 m/s b. 2500 m/s
c. 3500 m/s d. None of above
55. **Rad is burned to produce:**
a. 10 ergs/g b. 100 ergs/g
c. 0.1 erg/g d. 1000 ergs/kg
56. **Ultrasound frequency used for diagnostic purposes in obstetrics:**
a. 1-20 MHz b. 20-40 MHz
c. 40-60 MHz d. 60-80 MHz
e. 80-100 MHz
57. **All of them use nonionizing radiation except:**
a. Ultrasonography
b. Thermography
c. MRI
d. Radiography
58. **X-rays are produced when:**
a. Electron beam strike the nucleus of the atom

- b. Electron beam strikes the anode
 - c. Electron beam reacts with the electromagnetic field
 - d. Electron beam strikes the cathode
59. X-rays are modified:
- a. Protons b. Electrons
 - c. Neutrons d. Positrons
60. Contrast in X-rays is predominantly dependent on:
- a. KV
 - b. MA
 - c. Duration of exposure
 - d. Distance between source and object
61. Negative contrast medium is:
- a. Difficult for X-rays to penetrate
 - b. Easily penetrated by X-rays
 - c. High in atomic number
 - d. Opaque to X-rays
62. The contrast used for MRI includes:
- a. Perfluorocarbons
 - b. Ferric ammonium citrate
 - c. Gadolinium diethylmethylamine
 - d. All of the above
63. NMR based in the principle of:
- a. Electron beam
 - b. Proton beam
 - c. Magnetic field
 - d. Neutron beam
64. MRI is not better than CT for detection of:
- a. Ligament injury
 - b. Soft tissue tumors
 - c. Meningeal pathology
 - d. Calcified lesions
65. All of the following about MRI are correct except:
- a. MRI is contraindicated in patients with pacemakers
 - b. MRI is useful for evaluating bone marrow
 - c. MRI is better for calcified lesions
 - d. MRI is useful for localizing small lesions in the brain
66. Patient with a metallic foreign body investigation is not done:
- a. MRI b. USG
 - c. X-ray d. CT
67. The EEG cabins should be completely shielded by continuous sheet of wire mesh of copper to avoid the noise from external electromagnetic disturbances. Such a shielding is called as:
- a. Maxwell cage
 - b. Edison's cage
 - c. Faraday cage
 - d. Ohm's cage
68. Ionizing radiation is the substance which ionizes the atoms when it passes. It is harmful for biological matter. Which of the following is non-ionizing modality?
- a. Conventional X-rays
 - b. Computerized tomography
 - c. Magnetic resonance imaging
 - d. Isotopic scanning
69. Investigation of choice for focal neurologic deficit in emergency room is:
- a. CT
 - b. MRI
 - c. Lumbar puncture
 - d. USG
70. Fracture of nose, which view X-ray taken:
- a. Waters view
 - b. Caldwell's view
 - c. Lateral view
 - d. Occlusive anterior view
71. Which of the following statements about contrast in radiography is true?
- a. Ionic monomers have three iodine atoms per two particles in solution
 - b. High osmolar contrast agents may be ionic or nonionic
 - c. Gadolinium may cross the blood brain barrier
 - d. Iohexol is a high osmolar contrast media

72. Doppler effect results from change in:
- Amplitude of sound
 - Frequency of sound
 - Direction of sound
 - None of the above
73. Investigation of choice for subdural hemorrhage is:
- Angiography
 - NCCT
 - CECT
 - MRI
74. Which of the following contrast agents is preferred in a patient with decreased renal function to avoid contrast nephropathy?
- Acetylcysteine
 - Fenoldopam
 - Mannitol
 - Low osmolar contrast
75. High resolution computed tomography of the chest is the ideal modality for evaluating:
- Pleural effusion
 - Interstitial lung disease
 - Lung mass
 - Mediastinal adenopathy
76. Investigation of choice in congenital uterine anomaly is:
- MRI
 - CT
 - HSG
 - Hysteroscopy
77. Best investigation for pericardial effusion is:
- MRI
 - CT
 - X-ray
 - Echocardiography
78. Barium swallow is used for:
- Colon
 - Esophagus
 - Duodenum
 - Jejunum
79. Rhese view is used for:
- Superior orbital foramen
 - Inferior orbital foramen
 - Optic foramen
 - Sella turcica
80. Becquerel is equal (disintegration/sec) to:
- 3.7×10^{10}
 - 2.7×10^{10}
 - 1.7×10^{10}
 - 3.7×10^{-2}
 - 1
81. Which one of the following has the maximum ionization potential?
- Electron
 - Proton
 - Helium ion
 - Gamma-Photon
82. Which of the following techniques uses Piezo-electric effect?
- MR spectroscopy
 - Xeroradiography
 - Ultrasonography
 - Conventional tomography
83. Investigation of choice in cholelithiasis:
- CT
 - PET scan
 - USG
 - MRCP
84. Investigation of choice for DVT is:
- Doppler USG
 - Angiography
 - CT scan
 - MRI
85. A 8-year-old child was injected contrast in hand for CECT chest. Immediately he developed swelling in the arm which gradually increased. After 4 hours, there was numbness and pain, and he was not allowing the doctor to flex the hand. Pulse is present. What should be done?
- High dose prednisolone
 - Arterial thrombectomy
 - Immediate fasciotomy
 - Angiography
86. Radionuclide scan done for parathyroid adenoma is:
- Sestamibi
 - Iodine-123 scan
 - ^{99m}Tc -sulphurcolloid
 - Gallium scan

87. Use of water-soluble contrast medium is:
- Constipation
 - Perforation
 - Ileocecal tuberculosis
 - Gastroesophageal reflux
88. Which of the following liver metastasis appears hypoechoic on ultrasonography?
- Breast cancer
 - Colon cancer
 - Renal cancer
 - Mucinous adenocarcinoma
89. X-ray artifact is:
- A radiolucent area
 - Any abnormal opacity in the radiograph
 - Produced when patient moves while taking the shoot
 - Any of the above
90. Decubitus view is useful in diagnosing:
- Pleural effusion
 - Pleural effusion with dependent hemithorax
 - Pericardial effusion
 - Middle lobe consolidation
91. X-rays were discovered by:
- Godfrey Hounsfield
 - Roentgen
 - Coulomb
 - Sievert
92. Grid is a device used for:
- Reducing scattered radiation
 - Reducing patient's exposure time
 - Reducing the contrast of the X-ray
 - All of the above
93. The active ingredient of X-ray film is:
- Silver chloride
 - Silver bromide
 - Silver nitrate
 - Gold chloride
94. The best X-ray view for minimal pleural effusion:
- AP
 - PA
 - Lateral
 - Lateral decubitus
95. Half life of Tc99 is:
- 6 hours
 - 3 days
 - 10 months
 - 12 years
96. Interlobar pleural effusion can be detected in best way in:
- Lateral decubitus
 - Reverse lordotic
 - Lateral oblique
 - Posterior oblique
97. Piezoelectric crystals are made use of in which modality that is safe from radiation also?
- MRI
 - US
 - CT
 - All of above
98. Radioisotope used in PET scan is:
- Tecnetium 99m
 - Iodine 123
 - Iodine 131
 - Fluoride 18
99. Most common radiological feature of sarcoidosis in Indian patients:
- Normal chest X-ray
 - Bilateral hilar lymphadenopathy
 - Bilateral hilar lymphadenopathy with parenchymal infiltrate
 - Only parenchymal infiltrate
100. Which one of the following imaging modalities is most sensitive for evaluation of extra-adrenal Pheochromocytoma?
- Ultrasound
 - CT
 - MRI
 - MIBG scan
101. The diagnostic procedure not done in case of pheochromocytoma:
- CT scan
 - MRI
 - FNAC
 - MIBG scan

102. True about electromagnetic radiations are all except:
- Pair production occur for low energy
 - Infrared is an EM radiation
 - Compton scattering occur for intermediate energy
 - X-ray is EM radiation
103. Earliest diagnosis of cerebral infarct can be done by:
- NCCT
 - CECT
 - Diffusion weighted MRI
 - FLAIR MRI
104. Best investigation for diagnosing abdominal aortic aneurysm is:
- USG
 - CT angiography
 - Classical radiography
 - Noncontrast CT scan
105. Fluorescein angiography is used to examine:
- Ciliary vasculature
 - Retinal vasculature
 - Corneal vasculature
 - Conjunctival vasculature
106. Hounsfield unit of fat ranges from:
- 1 to 20
 - 100–1000
 - 10 to -100
 - 100–300
107. Chest X-ray, most common view is:
- AP
 - PA
 - RAO
 - LAO
108. Which of the following is the gold standard for imaging of swallowing disorders?
- Dynamic MRI
 - Barium swallow
 - Videofluoroscopy
 - X-ray
109. 1 Gray is equal to:
- 1 Roentgen
 - 1 Rad
 - 100 Rad
 - 1 Rem
110. Inferior rib notching is seen in:
- Coarctation of aorta
 - SLE
 - RA
 - Scleroderma
111. Most sensitive test for ureteric stone is:
- CECT
 - MRI
 - USG
 - NCCT
112. Contrasts used in USG:
- Urografin
 - Ultragraffin
 - Sonavist
 - Conray
 - Barium
113. Best view for collapse of middle lobe lung is:
- Lateral
 - AP
 - Oblique
 - Lordotic
114. On imaging diffuse axonal injury is characterized by:
- Multiple small petechial hemorrhage
 - Patchy, defined low density lesion mixed with small hyperdense petechial hemorrhage
 - Crescentic extra-axial hematoma
 - White matter lucencies
115. Miliary nodules are seen in all except:
- Silicosis
 - TB
 - Aspergillosis
 - Anthracois
116. Hour glass appearance of stomach is seen in:
- Linitis plastica
 - Gastric ulcer
 - Duodenal ulcer
 - Gastric carcinoma
117. Which of the following is the investigation of choice for dissecting aortic aneurysm?
- CECT
 - PET
 - MRI
 - TEE

118. Ultrasonogram is the primary modality of choice in obstetrics and in surgery. Frequency of the ultrasound used to image the breast, thyroid and testis are:

- a. 2–5 MHz b. 5–10 MHz
- c. 1–2 MHz d. 20–25 MHz

119. In a 90-year-old man with pyonephrosis and with pacemaker and Sr. creatinine of 3 mg/dL, which of the following should be used:

- a. CECT b. NCCT
- c. MRI d. X-ray

Multiple Correct Answers

120. Energy linear acceleration used in:

- a. X-ray b. Cathode rays
- c. Photon rays d. α -rays
- e. γ -rays

121. Which of the following do not use radiation?

- a. MRI b. CT
- c. USG d. SPECT
- e. PET

122. True about virtual colonoscopy are A/E:

- a. Provide endoluminal view
- b. Biopsy can be taken
- c. CT and MRI used

- d. Used even when conventional colonoscopy fails
- e. Used for screening of carcinoma-colon

123. Radiological findings of eosinophilic granuloma is/are:

- a. Hilar involvement
- b. Miliary shadowing
- c. Honey comb appearance
- d. White out lung
- e. Splitting of pleura

124. Tracheal bifurcation on X-ray corresponds to

- a. T5T6
- b. T4T5
- c. Sternal angle
- d. Thoracic inlet

125. Radiation hazard is absent in:

- a. MRI
- b. Doppler USG
- c. Digital subtraction angiography
- d. Tc 99 scan

126. Attenuation value (Hounsfield unit) of < zero (i.e. negative) on CT is seen in:

- a. Muscle b. Bone
- c. Fat d. Air
- e. Blood

ANSWER KEYS

1. **Ans. a.** Mass density
 2. **Ans. b.** In pediatric patients dose should be reduced
 3. **Ans. d.** Tc-thallium subtraction scan
 4. **Ans. c.** Inferior mesenteric artery
 5. **Ans. a.** MRI STIR sequence
 6. **Ans. d.** Whole body
 7. **Ans. d.** Linear attenuation coefficient
 8. **Ans. c.** Lateral view
 9. **Ans. c.** Bone algorithm for image reconstruction
 10. **Ans. d.** Microwave
 11. **Ans. a.** Open fontanelles
 12. **Ans. c.** Position emission tomography
 13. **Ans. b.** \uparrow kVp
Its a wrongly framed question friends, ideally the body part of CT should have been mentioned.
 14. **Ans. d.** CT scan
 15. **Ans. c.** Placenta previa
 16. **Ans. d.** PET scan
 17. **Ans. a.** MRI
 18. **Ans. c.** CT guided biopsy
 19. **Ans. a.** Shortening of both T1 and T2 relaxation times
 20. **Ans. b.** Gray
 21. **Ans. d.** >2 MHz
 22. **Ans. a.** Gadolinium
 23. **Ans. a.** Water
 24. **Ans. b.** Iodinated nonionic water soluble contrast
 25. **Ans. d.** They are used in magnetic resonance imaging
 26. **Ans. a.** Breast imaging reporting and data system
 27. **Ans. a.** Change in frequency in relation to the movement of source or observer
 28. **Ans. a.** Multidetector CT contrast
 29. **Ans. d.** Helium nucleus
 30. **Ans. a.** USG
 31. **Ans. a.** Velocity
 32. **Ans. a.** Hounsfield unit
 33. **Ans. a.** Piezoelectric effect
 34. **Ans. c.** Picture archiving communication system
 35. **Ans. a.** 400-700 nm
 36. **Ans. a.** Hounsfield
 37. **Ans. a.** Barium meal follow through
 38. **Ans. a.** Bile
 39. **Ans. c.** Silver
 40. **Ans. d.** Myelography
 41. **Ans. b.** Mercury
*As we all know that Scattering of the radiation is the function of Compton effect and Compton effect is proportional to the no of electron per unit volume which is equal to no of electron/ volume = physical density(m/v) \times electron density (number of electrons per unit mass).
Electrone density is proportional to Z/A (as number of atoms per unit mass is proportional to $1/A$ and number of electrons per atom is proportional to Z)
 A - is atomic mass, Z is atomic number.
Electrone density is maximum for H ($Z/A = 1/1$), while rest of the elements have $Z/A \sim 0.5$.
Physical density of various elements are as follows:*
- | | |
|----------|-----------------------------------|
| Mercury | – 13.5 gm/cm ³ |
| Hydrogen | – 0.000082 |
| Carbon | – 3.513 (diamond); 2.2 (graphite) |
| Calcium | – 1.54 |

So if we look at the combine picture, though hydrogen has most favorable z/A ratio for Compton effect, the difference in mass density so so much that virtually, Compton effect become proportional to the mass density.

Hence the answer should be Mercury (Hg)

42. **Ans. a.** Gamma rays
43. **Ans. c.** Iodine
44. **Ans. b.** USG
45. **Ans. d.** Morbid obesity
46. **Ans. b.** Lesser than that of light
47. **Ans. a.** Tomography
48. **Ans. a.** FDG
49. **Ans. a.** Sonography
50. **Ans. b.** Foley's catheter
51. **Ans. a.** Lead
52. **Ans. b.** MR angiography
53. **Ans. d.** UV radiation
54. **Ans. a.** 1500 m/s
55. **Ans. b.** 100 ergs/g
56. **Ans. a.** 1-20 MHz
57. **Ans. d.** Radiography
58. **Ans. a.** Electron beam strikes the anode
59. **Ans. b.** Electrons
60. **Ans. a.** kV
61. **Ans. b.** Easily penetrated by X-rays
62. **Ans. c.** Gadolinium diethylmethylamine
63. **Ans. b.** Proton beam
64. **Ans. d.** Calcified lesions
65. **Ans. c.** MRI is better for calcified lesions
66. **Ans. a.** MRI
67. **Ans. c.** Faraday cage
68. **Ans. c.** Magnetic resonance imaging
69. **Ans. a.** CT
70. **Ans. c.** Lateral view
71. **Ans. a.** Ionic monomers have three iodine atoms per two particles in solution
72. **Ans. b.** Frequency of sound
73. **Ans. b.** NCCT
74. **Ans. d.** Low osmolar contrast
75. **Ans. b.** Interstitial lung disease
76. **Ans. a.** MRI
77. **Ans. d.** Echocardiography
78. **Ans. b.** Esophagus
79. **Ans. c.** Optic foramen
80. **Ans. e.** 1
81. **Ans. c.** Helium ion
82. **Ans. c.** Ultrasonography
83. **Ans. d.** MRCP
84. **Ans. a.** Doppler USG
85. **Ans. c.** Immediate fasciotomy
86. **Ans. a.** Sestamibi
87. **Ans. b.** Perforation
88. **Ans. c.** Renal cancer
89. **Ans. c.** Produced when patient moves while taking the shoot
90. **Ans. b.** Pleural effusion with dependent hemithorax
91. **Ans. b.** Roentgen
92. **Ans. a.** Reducing scattered radiation
93. **Ans. b.** Silver bromide
94. **Ans. d.** Lateral decubitus
95. **Ans. a.** 6 hours
96. **Ans. b.** Reverse lordotic
97. **Ans. b.** US
98. **Ans. d.** Fluoride 18
99. **Ans. b.** Bilateral hilar lymphadenopathy
100. **Ans. d.** MIBG scan
101. **Ans. c.** FNAC
102. **Ans. a.** Pair production occur for low energy
103. **Ans. c.** Diffusion weighted MRI
104. **Ans. b.** CT angiography
105. **Ans. b.** Retinal vasculature

106. **Ans. a.** -10 to -1000
107. **Ans. b.** PA
108. **Ans. b.** Barium swallow
109. **Ans. c.** 100 Rad
110. **Ans. a.** Coarctation of aorta
111. **Ans. d.** NCCT
112. **Ans. c.** Sonavist
113. **Ans. d.** Lordotic
114. **Ans. b.** Patch ill, defined low density lesion mixed with small hyperdense of petechial hemorrhage
115. **Ans. c.** Aspergillosis
116. **Ans. b.** Gastric ulcer
117. **Ans. a.** CECT
118. **Ans. b.** 5-10 MHz
119. **Ans. b.** NCCT

Multiple Correct Answers

120. **Ans. a.** X-ray, **b.** Cathode rays
121. **Ans. a.** MRI, **c.** USG
122. **Ans. a.** Provide endoluminal view and **e.** Used for screening of carcinoma colon
123. **Ans. a.** Hilar involvement, **b.** Miliary shadowing, **c.** Honey comb appearance, **d.** White out lung, **e.** Splitting of pleura
124. **Ans. b.** T4T5
Most of the standard radiology textbooks and 40th edition of Gray's anatomy says the bifurcation is at T4T5 level which however descend to T6 level on deep inspiration.
41st edition of Gray's anatomy says that bifurcation is at upper half of T6 vertebra level which however descend to T6 level on deep inspiration which looks like a controversial statement
125. **Ans. a.** MRI, **b.** Doppler USG
126. **Ans. c.** Fat, **d.** Air

Section B

SYSTEMIC RADIOLOGY

- **Neuroradiology**
- **Cardiothoracic Radiology**
- **Gastrointestinal and Genitourinary System**
- **Musculoskeletal Radiology**

mebooksfree.com

NCCT-Non contrast CT
SDH-Subdural hemorrhage
IOC-Investigation of choice

SAH-Subarachnoid hemorrhage
EDH-Extradural hemorrhage
D/d-Differential diagnosis

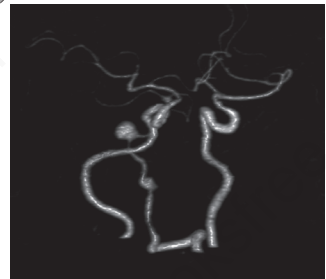
Trauma/Stroke

- **IOC** for suspected intracranial bleed in case of trauma—NCCT Head
- **IOC** for acute SAH—NCCT Head
- **IOC for cause of acute SAH (nontraumatic)**—Angiography
- CT angio, MR angio
- **MC-cause of nontraumatic SAH** → Rupture of berry aneurysm (IMAGE)
- **MC-cause of SAH** → trauma
- **IOC** for diagnosis of chronic Intracranial bleed → MRI (>48 hrs)
- As it can pick hemorrhagic products like hemosiderin even if they are not visible on CT (on gradient images of MRI)
- In unconscious patients **IOC** for stroke → NCCT Head as it rules out acute bleed or hemorrhagic infarct (which is a contraindication for thrombolysis).
- **IOC** for Nonhemorrhagic infarct/stroke—MRI (**Diffusion weighted images**)
- 1st investigation for TIA → USG Doppler of carotid vessels—**best modality to visualize small atherosclerotic plaque.**
- **Screening modality** for atherosclerotic brain disorder standard MR angiography.

Signs of Hyperacute Infarct on NCCT

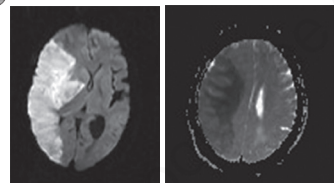
- Hyperdense MCA sign
- Cortical ribbon/insular ribbon sign
- Ill-marginated lentiform nuclei

IOC for acute intracranial bleed is NCCT as it appears hyperdense on CT and CT can be performed in unstable patients unlike MRI.

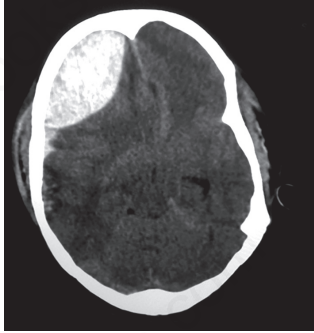


Berry aneurysm

Restricted diffusion appears hyperintense on DW images and hypointense on ADC images.



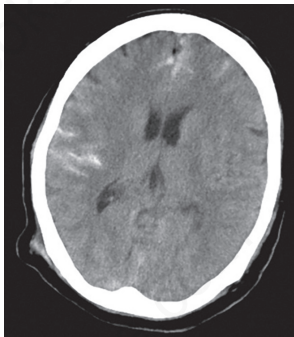
DWI, ADC- showing restricted diffusion



Acute EDH

Acute bleed can be iso to hypodense if
 -Clotting pathway abnormality
 -Severe anemia

Subclavian Steal Phenomenon-
 Can cause Stroke due to reversal of blood flow in I/L vertebral artery due to thrombosis in proximal SCA. (Initial IOC-USG doppler)



Acute-SAH

Swirl Sign- due to active bleed in EDH seen as **hypodense area** in hyperdense bleed on NCCT.

- Sulcal effacement due to edema.
 - Acute infarct-wedge shaped cortical based hypodense area involving both grey and white matter on NCCT
 - Fogging effect in subacute stage of infarct due to reopening of capillaries and leak leads to increase attenuation of brain of acute infarct.
- As hyperacute infarct can be missed on NCCT
 - IOC for Hyperacute Infarct → MRI-[best sequence -DWI]
 - Acute/hyperacute infarcts shows restricted diffusion

| Bleeds | |
|--|---|
| Intra axial | Extra axial |
| <i>Hemorrhagic contusion</i> <i>DAI</i> | SAH-Linear collection along sulci SDH-concavo convex-(cres centric) EDH-Biconvex (lenticiform) (IMAGE) due to torn MMA |
| Acute bleed → Hyperdense Subacute bleed → Isodense to brain parenchyma Chronic bleed → Hypodense | |

| SDH | EDH |
|--|---|
| <ul style="list-style-type: none"> • Shear type injury • <i>Crescent shaped collection</i> • Not limited by sutures • Limited by dural reflection—does not cross the midline • Bridging veins (source) | <ul style="list-style-type: none"> • Assc with skull fractures • Biconvex collection • Limited by sutures • Not limited by dural reflection—can cross the midline • Middle meningeal artery (source) |

Acute SAH—Liner Hyperdensities along Sulci, (IMAGE) Fissure Space for any other CSF Space

DAI—Best sequence to pick DAI → **Gradient sequence/susceptibility imaging**

Uncal herniation → compression of C/L cerebral peduncle against tentorium → (Kernohan’s notch)

Deep Venous sinus Thrombosis—Nonenhancing hypodense triangular density- Empty Delta sign-(Only on Contrast Enhanced CT and MRI of Superior Sagittal Sinus) **Delta sign**-hyperdense triangular shadow in superior sagittal sinus. (IMAGE) on noncontrast CT.

Common Skull Appearances on X-ray

Hemolytic anemia

(most common)

Thalassemia)

Raised ICT

Growing fracture

Eosinophilic granuloma

Multiple myeloma

Hyperparathyroidism

Craniolacunias

(lacunar skull)

Cotton wool skull

• Wormian bones:

- Cleidocranial dysostosis
- Osteogenesis imperfecta
- Hypothyroidism
- Pycnodysostosis

Physiological Intracranial Calcification

- Pineal gland (MC)
- Habenular commissure → 'c'-shaped open posteriorly
- Choroid plexus
- Interhemispheric falx
- Anterior petroclinoid ligaments
- Basal ganglia/dentate nucleus (5% of normal population)
- Pacchionian bodies

**pituitary/lens

- Hair on end appearance

- Silver/copper beaten appearance

- Skull in pediatric patient with trapped leptomeninges (the leptomeninges does not let fracture unite and with formation of leptomeningeal cyst cause expansion of fracture-growing fracture)

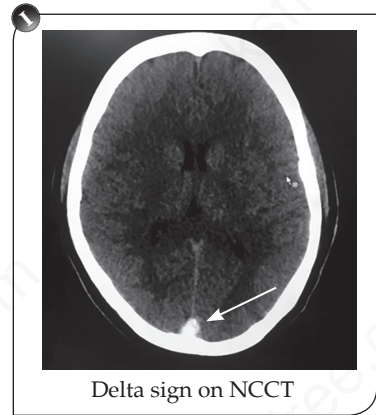
- Geographic lytic lesion with bevelled edge

- Punched out lytic lesions

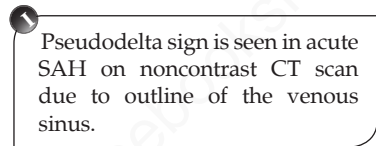
- Salt and pepper/mottled skull

- defect in ossification of the bones (membranous) (no significance) but generally associated with Myelomeningocele or encephalocele

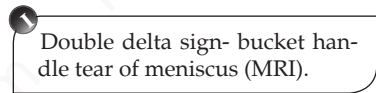
- **Paget's disease (IMAGE)**



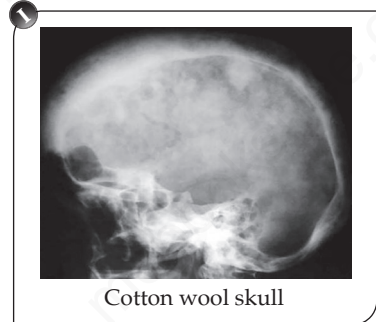
Delta sign on NCCT



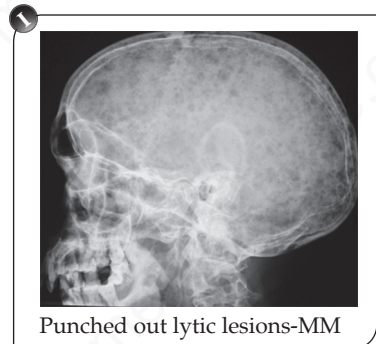
Pseudodelta sign is seen in acute SAH on noncontrast CT scan due to outline of the venous sinus.



Double delta sign- bucket handle tear of meniscus (MRI).



Cotton wool skull

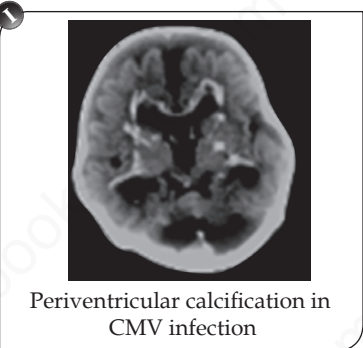


Punched out lytic lesions-MM

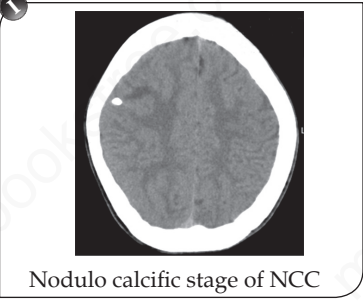
- Vein of Galen Malformation
 - Child with hydrocephalus congestive cardiac failure
 - Large arc like calcification in the region of pineal gland
 - Midline Hypochoic tubulocystic lesion with high velocity turbulent bidirectional Flow on cranial USG in pediatric population.

• *Gold standard for evaluation of SAH four vessel angiography [by transfemoral catheterization of both ICA and one vertebral with other filled by reflex].

- Six Vessel Angiography
 - B/L ICA
 - B/L ECA
 - B/L VA
 - [Via puncture of R femoral artery]



• Rich focus → small subpial subependymal cortical focus of infection (TB).



Abnormal Calcification

- Periventricular calcification
 - Cytomegloviral infection
- Diffuse nodular pattern
 - Toxoplasmosis
- Subependymal calcified nodules
 - Tuberos sclerosis (candle dripping appearance)
- Bracket calcification
 - Corpus callosal lipoma
- Tram track pattern of gyral calcification
 - Sturge Weber syndrome
- Starry sky pattern
 - Neurocysticercosis

Basal Ganglia → Calcification

- Idiopathic
- Thyroid dysfunction
- CO/lead poisoning
- Toxoplasmosis
- Cockaynes
- Fahr's

Infections

Triad of acute tubercular meningitis

- Basilar/basal meningitis (IMAGE)
- Hydrocephalus
- Vasculitic infarcts

Chronic tubercular meningitis → en plaque dural thickening and popcorn-like dural calcification

Peripheral/Ring Enhancing Lesions (MAGIC DRT)

- M → Metastasis
- A → Abscess [with Restricted diffusion]
- G → glioma/high grade glioma
- I → Infection-Tuberculomas/toxoplasmosis
- C → cysticerci → NCC
- D → Demyelination → acute phase with incomplete rim
- R → Radiation necrosis
- Thrombosed aneurysm

Pachymeningitis

- TB
- Meningioma
- Lymphoma
- Sarcoidosis

NCC Escobar's Four Pathologic Stages

- **1st vesicular stage**—Non-enhancing/**no edema**
- **IInd colloid vesicular**—Thick Rim enhancement/edema/enhancing eccentric mural nodule
- **IIIrd Granular nodular**—Thick Rim enhancement/calcified mural nodule large edema
- **IVth nodular calcified** → **calcified nodule/ no edema, may be seen in context of seizure activity** [Stary sky on NCCT]

Encephalitic form—multiple small enhancing lesions with diffuse cerebral edema. (IMAGE)

Intraventricular NCC → MC in 4th ventricle.

Racemose variety—cisternal location with **lack of mural nodule**, multilobulated large cysts of CSF signal + hydrocephalus

- because no host response in basal cisterns [Scolex never being formed]
- **Peas in a pod appearance** → **cysticercosis in extra-ocular muscles.**

Hydatid

Calcification of wall is rare in brain.

HSV-1

- Basifrontal (orbital surface) and temporal lobe [Inferomedial]
- Cingulate gyrus
- Hemorrhagic encephalitis
- Relative sparing of basal ganglia/thalami/posterior fossa structures.

HIV can involve basal ganglia, periventricular and subcortical white matter, but no involvement of cingulate gyrus.

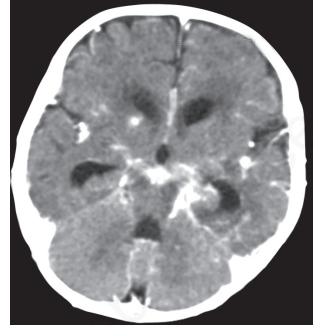
Cryptococcus [AIDS] →

- Non-enhancing dilated perivascular spaces (**cryptococcomas**)
- Gelatinous pseudocyst
- Basal exudates present (**Basal meningitis**)

JE → Japanese encephalitis

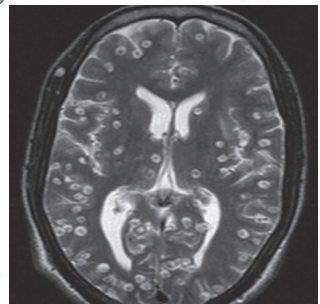
- Isolated T2W Hyperintensity in the substantia nigra and B/L thalami
- Hemorrhage in the B/L thalami.

Cryptococcal meningitis can also show basal meningitis however differentiating feature from tubercular meningitis is prominent Virchow-Robin spaces.



Basilar meningitis and hydrocephalus in TB

Pineal gland is most common site of normal calcification in the brain but if >1 cm can be due to pinealoma.



Encephalitic form of NCC

- No inflammatory reaction if the parasite is live as in vesicular stage and hence no inflammatory reaction- no edema
- Nodular calcified lesion can have residual edema

| HIV encephalitis | Progressive multifocal leuco encephalopathy (PML) |
|--------------------------------|---|
| <i>Dementia</i> | <i>Focal deficit /cognitive/speech</i> |
| <i>Symmetric</i> | <i>Asymmetric</i> |
| Cortical atrophy (MC) | Periventricular and subcortical |
| Periventricular Diffuse | Multifocal- |
| <i>Mild T1W hypointense</i> | <i>Scalloped lesion</i> |
| | <i>Mild to severe T1W, hypointense</i> |

PML–involvement of subcortical white matter

With Grey-White interface (Scalloped appearance)

- No mass effect in (PML or HIV)
- **Relative sparing of cortical ribbon**
- “Heart of the Gyrus Sign”

LEUKODYSTROPHIES OR WHITE MATTER DISEASES

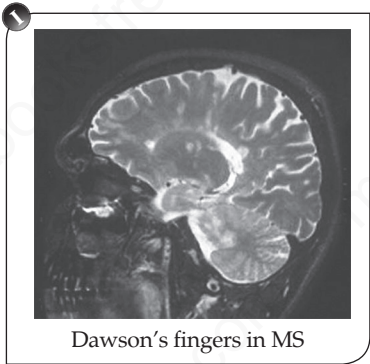Multiple Sclerosis Relapsing-remitting (McDonald’s Criteria)

1. Demyelinating lesions disseminated in space
2. Demyelinating lesions disseminated in time
3. Exclusion of alternative explanation for clinical presentation.

MRI features

- **Dawson’s fingers**
 - [along periventricular veins] right angle to lateral ventricles
 - Focal areas along calloso-Septal interface [highly sensitive and specific] Specifically at inferior margin of Corpus Callosum Earliest indication of MS
 - Spared in ischemic demyelination
- Dot and dash sign all Flair MRI
- In acute phase → Homogenous enhancement → ring like enhancement (also in acute on chronic reactivation)
- **Black hole** → T2W hyper and T1W hypo → **(severely injured white matter)**
- Atrophy (severely injured brain)

1 Number and size of lesions increase with increase in dose of contrast in MS.



Other Leukodystrophies

- **Adreno cortico leukodystrophy** → Splenium and peritrigonal white matter (Triple layers on post gado)

- **Alexander's disease** → frontal and periventricular white matter and involvement of caudate nuclei/ Macrocephaly
- **Krabbe's disease:**
 - Increase density in **basal ganglia and Thalamus**
 - Cerebellar white matter and pyramidal tracts.
- **Pelizaeus-Merzbacher disease** → Diffuse periventricular and subcortical white matter with atrophy (**tigroid pattern**)
- **Metachromatic leukodystrophy** → (MC) confluent symmetric B/L peripheral supratentorial white matter
- **MLC (Megalencephalic leukodystrophy with subcortical cysts)** → B/L symmetrical Globus pallidus with sparing of rest (also seen in Kernicterus and Kearn sayre synderom)
- **Glutaric acid uric** → subcortical 'U' fibers and basal ganglia involvement and spare thalami
- **Schilder's disease** (diffuse sclerosis) from corpus collosum to B/L parieto occipital region
- **Marchiafava-Bignami** → mainly corpus callosum
- **Central pontine Myelinolysis** → pontine white matter only
- **Extrapontine** → Midbrain, thalami and subcortical white matter
- **Canavan's disease** → Diffuse white matter involvement/macrocephaly/↑↑NAA on spectroscopy.
- **Leigh's disease** (Mitochondrial)
 - Brainstem
 - Deep cerebellar grey matter
 - Subthalamic nucleus
 - Basal ganglia

Hallervorden-Spatz Disease

Eye of tiger appearance, involvement of B/L globus pallidus.

Humming bird sign-progressive supra nuclear palsy

Bat wing and molar tooth appearance-Joubert's syndrome.

Double panda sign

Face of giant panda - mid brain

Face of miniature panda- pons on (T2W) MRI- Wilson disease

Wilson's Disease 'Panda face' → Due to involvement of substantia nigra and tegmentum.

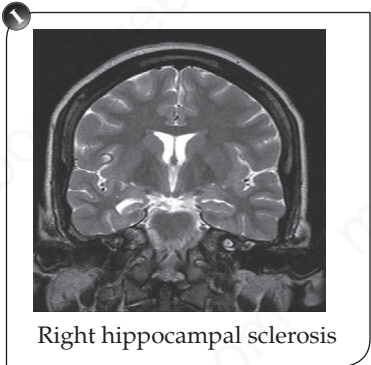
Causes of Macrocephaly

- **Canavans (only disease which shows raised NAA peak on Spectroscopy)**
- GM2 Gangliosidosis
- MLC
- Alexander's
- Glutaric acid urea

Globus Pallidus involvement seen in:

- MLC
- Kernicterus
- Kearns Sayre syndrome
- Hallervarden Spatz disease

1 Intracarotid amobarbital test [Wada's Test] → to test hemispheric functions in patients undergoing epilepsy surgery → helps in language lateralization and predicts for global amnesia.



1 Meningioma bone-en plaque type invade bone-causing hyperostotic thickening and sclerosis.

1 MIS ME lesions
NF-2 → Multiple inherited schwannoma, meningioma, Ependyoma)

EPILEPSY

MTS (mesial temporal sclerosis) Most Common Cause of Medically Intractable Seizures [surgical resection possible]

Primary MRI features →

- Atrophy, Hippocampal (**IMAGE -R**)
- ↑ T2W signal

Secondary Features

Excitotoxicity induced neuronal death (as hippocampus is most sensitive structure in brain to ischemia)

- Temporal horn dilatation (**IMAGE-R**)
- Loss of hippocampal signal on T1 W images.
- **Loss of hippocampal head digitations. (IMAGE-R)**
- Loss of collateral white matter
- Poor parahippocampal grey-white matter differentiation
- I/L atrophy of temporal lobe, thalamus, fornix and mammillary body

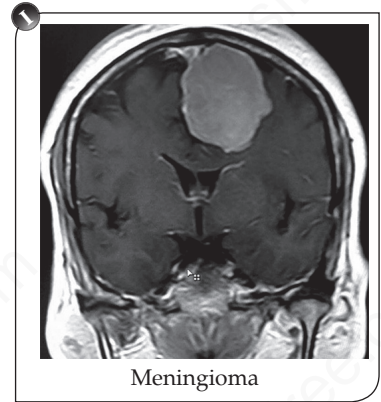
TUMORS

- Most common primary brain tumor—Meningioma (35%)
- Most common primary intraparenchymal brain tumor—Glioma (30%)
- Most common brain tumor to show calcification—Craniopharyngioma
- Most common intraparenchymal brain tumor to show calcification—Oligodendroglioma (highest propensity to calcify)
- Most common brain tumor—Metastasis
- Hemorrhagic metastasis → Choriocarcinoma/ Kidney
- Leptomeningeal metastasis → Breast/lung/melanoma
- Calvarial metastasis → Breast > lung
- Dural metastasis → Breast/lung/kidney
- Solitary metastasis → Lung > Kidney
- T1W hyperintense metastasis → Melanoma

Meningioma → MC tumor brain (IMAGE)

If Multiple → neurofibromatosis-II

- **X-ray:**
 - Hyperostosis (MC)/erosion(unlikely) of overlying bones
 - Tumor calcification (Psammoma/sand bodies)
 - Enlarged vascular grooves
 - Pneumosinus dilatans
- **Angio:**
 - Dual vascular supply (Mother in law lesions/ spoke wheel) (contrast comes early and stays for long) [sunburst pattern of enlarged dural feeders]
- **CT:**
 - Hyperdense
 - Enhance intensely
 - Calcification [20–30%]
 - Degenerative parvenchymal cyst/trapped arachnoid
 - 60% perilesional edema
- **MRI:**
 - Buckling of Grey-white matter interphase
 - CSF cleft/or pseudocapsule
 - Pseudocapsule due to vessels surrounding mass and CSF
 - Dural tail (60%) [not pathognomonic]
 - Iso intense to grey matter on all pulse sequences



Meningioma

Spinal meningioma →
Myelography → Intradural-extradural mass

- Vestibular schwannoma from inferior vestibular nerve
- Ice cream cone appearance

Spectroscopy -to differentiate rim enhancing lesions

- Necrotic tumor → only lactate peak
- Tuberculoma → only lipid lactate [cho/cr>1]
- Pyogenic abscess → Lactate + other amino acids
- NCC → Non-specific/very Less lipid

Spectroscopic findings

- Myotinositol peak → low grade tumors/Gliomatosis cerebri
- Tumors → choline
- Meningioma- Alanine peak

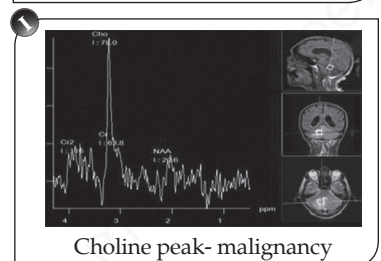
Pineal germinoma

- Hypedense on CT with homogenous contrast enhancement
- Engulf calcified masses

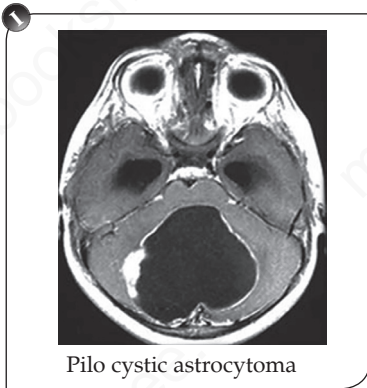
Schwannoma

- MC-8th > 5th > 7th CN
- Ist and IInd nerve not involved (lack Schwann sheath)

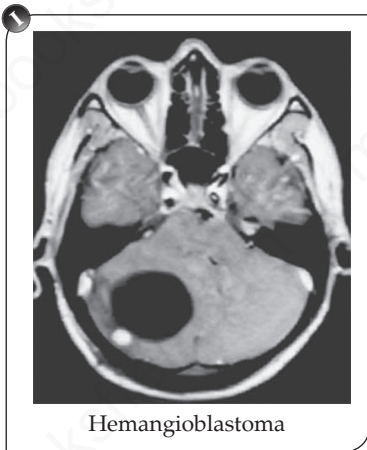
| Meningioma | Schwannoma |
|---|--|
| <ul style="list-style-type: none"> • Obtuse angle with dura • Ca⁺⁺ common • Homogenous • Not common at CP angle • Hyperostosis of IAC • Homogeneous with broad dural base enhancement | <ul style="list-style-type: none"> • Acute angle with dura • Ca⁺⁺ Rare • Heterogenous usually • MC CP angle mass • Widening of IAC comma shaped or ice cream cone appearance • Heterogenous enhancement |



Choline peak- malignancy



Pilo cystic astrocytoma



Hemangioblastoma

- IOC for microadenoma-dynamic MRI
- If no microadenoma on MRI in pituitary
- Next IOC → Inferior petrosal sinus venous sampling

- Pituitary Hypoplasia → kissing carotid sign
- Tuber cinereum Hamartoma → gelastic seizures

Pilocytic Astrocytoma

- Associated with NF-1
- Cystic lesion with intensely homogeneously enhancing mural nodule but no enhancement of cyst wall

Hemangioblastoma

- Associated with VHL
- Large avascular posterior fossa mass with a small highly vascular mural nodule (pial nodule) showing prolonged stain (mother in law phenomenon)
- Prominent serpentine flow voids due to enlarged vessels in the wall

Craniopharyngioma

- From Rathke's pouch
- Solid cystic – suprasellar mass
- Most common variant - adamantinomatous (90%)
- 80% cases – calcification
- [papillary variety usually does not calcify and is solid in adults].

Petrous/CP Pangle Paraganglioma

- Salt and pepper appearance (salt- blood, pepper-flow void)

Pituitary Macroadenoma

- > 1 cm
- figure of '8' (ballooning of sella)

Pituitary Microadenoma

- (< 1 cm) - most common is prolactionoma
- IOC dynamic CEMRI were microadenoma shows delayed enhancement

| Medulloblastoma | Ependymoma |
|--|-------------------------|
| From vermis | From 4th ventricle |
| Solid-hyperdense on CT | Solid cystic-Hypo on CT |
| Necrosis/Ca⁺⁺ -not common | Common |
| Foraminal extension-not common | Common |
| Subependymal spreads/ drop metastasis | |

Features of High Grade Malignancy

- ↑ tumoral necrosis
- Intratumoral hemorrhage
- Peritumoral edema
- Appearance of contrast enhancement
- **PET-IOC** to differentiate b/w tumor recurrence vs radiation changes.
- **Butterfly Glioma**—Glioblastoma multiforme—due to spread along corpus callosum to opposite side

1 *Double ring sign on CT around cochlea otosclerosis.
*Optic foramen projection Rhese projection.

- 1
- Heavy/streaky/ribbon like Ca++ → oligodendroglioma (70-90% cases)
 - Dense punctate Ca++ → Ependymoma

MR Features of Tumoral Hemorrhage (to Differentiate from Bleed)

- Heterogeneous signal/mass around bleed
- Eccentric location of bleed
- Tumor enhancement
- Hemorrhagic component of various ages/variable hemosiderin rim
- Delay in temporal evolution of hemorrhage
- Surrounding vasogenic edema

1 Tumors to calcify
COME Ca++
C-craniopharyngioma
O-oligodendroglioma
M-Meningioma
E-Ependymoma
C-Choroid plexus papilloma
A-astrocytoma

Brain Tumors which Spread Along CSF Flow/ Drop Metastasis

- Medulloblastoma
- Germ cell tumor/Germinoma)
- Lymphoma
- Ependymoma (after local recurrence)
- Pineocytoma/pineoblastoma-?
- Primitive neuroectodermal tumor (PNET)
- Anaplastic glioma/glioblastoma multiforme

| Epidermoid cyst | Arachnoid cyst |
|---|--|
| FLAIR- Mixed Iso/Hypo signal DWI (diffusion weighted)- High ADC- low (Show restricted diffusion) Encase vessels | Follow CSF signal on all sequences Low High (No restricted diffusion) Displace vessels |

| Dermoids (if pure fat) | Lipomas |
|--|---------------------------------------|
| Less lobulated Displaced blood vessels and Neural structure Chemical meningitis when rupture | Non lobulated encase blood vessels |

Raised ICT

Earliest

- **Adults** → Erosion of dorsum sella.

- Loss of lamina dura (later)
- Pineal displacement

Pediatric population → sutural diastasis [as unfused bones give way]

Copper beaten skull (later)

IOC for hydrocephalus → MRI

Ist IOC for hydrocephalus in child → USG [open fontanelle].

Retinal Detachment

- **Posterior hyaloid detachment** → fluid-fluid level
- **Retinal Detachment** → 'V' shaped with apex at optic disk
- **Hemorrhagic choroidal detachment** → Lentiform
- **Serous choroidal detachment** → Crescent/Ring

Graves Ophthalmology

- Enlargement of extraocular muscle but sparing tendinous insertion (MRI) (Cock bottle appearance)
- Order of involvement of muscles -IMS (Inferior, medial and superior rectus)

Golf hole appearance-TB involvement of vesicoureteric junction.

Pseudotumor

- Involve both muscle and tendinous insertion

Some Important Signs

- **AVM**-bag of Worm-like enhancement
- **Plunging Ranula**—Toil sign
- **Neurofibroma** → Target sign on T2W images
- **Paragangliomas/Glomus vagale** → Salt and pepper on T1W (Flow void-pepper and Hemorrhage) → Salt
- **Cementoblastoma** → Golf ball appearance
- **Calcifying epithelial odontogenic tumor [COET]** [Pind borg tumor] → Driven Snow
- **Odontogenic myxoma** → 'Tennis Racquet' appearance

Jaw Cysts

- Radicular cyst
 - cyst near root of carious tooth
- **Dentigerous cyst**
 - cyst related to crown of unerupted tooth
- **Ameloblastoma**
 - Thinning of cortex in buccolingual cortex
 - Multilocular cystic/soap bubble/honey comb lesion



MRI is IOC for

- **Juvenile angiofibroma**
→ To assess Intracranial extension
- Laryngeal Malignancy

Initial IOC

OPG – orthopantomogram X-ray

NEURO CUTANEOUS SYNDROMES

VHL

- Heart → rhabdomyoma
 - Pancreas → Islet cell tumor
 - Endolymphatic sac neoplasm
 - Hemangioblastoma
 - Cerebellar
 - Spinal
 - Retinal
- + cystic lesions of kidney, pancreas, liver, and epididymis
- + Pheochromocytomas
+ RCC

Gorlin's syndrome

- [basal cell nevus syndrome] → Medulloblastoma

Li-fraumeni-syndrome

- Medulloblastomas, gliomas APC,

Gardner's syndrome

- Medulloblastomas' Glioblastoma, Craniopharyngioma, **osteomas**

MEN-1 (Werner's syndrome)

- Malignant schwannoma, pituitary adenoma parathyroid and pancreatic islet cell tumor

Blood oxygenation level dependent contrast mechanism-BOLD
For functional imaging of brain.

Cavernous angioma → popcorn like lesion (MR)
venous angioma → medusa head appearance (venous phase)

Tram track pattern in MCQs

- MPGN
- CRAO
- Optic nerve sheath meningioma
- Bronchiectasis (HRCT)
- Sturge-Weber synd (X-ray)
- AS
- H Ducreyi

Lateral Meningoceles are seen in

- NF-1
- Marfan's syndrome
- Ehlers-Danlos syndrome

NF-1

- Schwannoma, astrocytoma, meningioma's, optic nerve gliomas, Neurofibromas (Dumbbell tumors), neuro fibro sarcomas.

NF-2 (MISME)

- **MIS** → Multiple Inherited Schwannomas
- **M** → Meningiomas
- **E** → ependymomas
- **Misnomer** → as No neurofibromas

Cowden's Syndrome

- Dysplastic cerebellar gangliocytoma (Lhermitte duclos disease), Meningioma, Astrocytoma

Osseous Lesions of NF-1

- Widening of neural foramina
- Hypoplastic sphenoid wing
- Sutural defects
- Kyphoscoliosis
- Dural ectasia
- Meningoceles
- Ribbon ribs
- Tibial bowing
- Pseudoarthrosis
- Focal overgrowth of digit
- Multiple ossifying fibroma
- Absent/small fibula
- Scalloping of post border of vertebral body

Eye in NF-1 →

- Optic glioma
- Lisch nodule of iris
- Buphthalmos
- Plexiform neurofibroma
- Empty orbit/Bare orbit
- Harlequin appearance of orbit
- Concentric enlargement of optic foramen [sclerosis in O.P. N. Sheath meningioma]

Sturge-Weber/Encephalotrigeminal Syndrome

- Capillary/cavernous hemangioma

- Tram track calcification
- Atrophy
- Scleral/choroidal angioma

Tuberous sclerosis

EPI- loi-a → epilepsy/low IQ/Adenoma sebaceum

- Cortical tubers-candle drippings
- Subependymal nodules in lateral ventricles
- Retinal phakomas
- Subependymal giant cell astrocytoma at foramen of Monro
- Skin → facial angiofibroma, shagreen patch
- Kidneys → Renal cysts and angiomyolipoma
- Cardiac rhabdomyomas, honeycomb lung (cysts)
- Adenomas

SEGA–Subependymal Giant Cell Astrocytoma

- At foramen of Monro
- In Patients with tuberous sclerosis
- Heavy intratumor calcification common
- Strong heterogeneous contrast enhancement
- (obstructive hydrocephalus with dilated lateral and normal 3rd and 4th ventricles)

Crouzon syndrome →

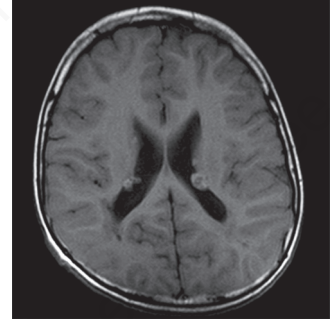
- Brachycephaly
- Parrot beak, maxillary hyperplasia, proptosis
- Ocular hypertelorism
- Hydrocephalus
- Chronic tonsillar herniation (MRI)

Apert Syndrome →

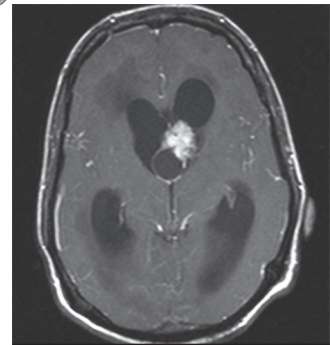
(Acrocephaly syndactyly)

- Brachycephaly
- Small cranial base
- Syndactyly [IIInd–IIIrd and IVth finger] [Mitten hand]
- Radially deviated broad thumb.
- Toe syndactyly [sock toes]
- Fusion of C5-C6 bodies
- Low IQ

1
Angiomyolipoma- kidney
(Lesions of mean attenuation -50 to -100 HU on CT)



Subependymal nodules -TS



SEGA- TS

1
SEGA-Causes obstructive hydrocephalus with dilatation of bilateral lateral ventricles and normal 3rd and 4th ventricles.

Histiocytosis [LCH]

- Geographical lytic lesion with bevelled edges
- Button Sequestrum (Skull)
- Floating teeth if (mandible)
- Vertebra plana
- Cysts in lung (bizarre) – honeycomb lesion

Malformations of Cortical Development

- **Abnormal neuronal-glial proliferation or apoptosis**
 - Microcephaly
 - Megalencephaly
- **Abnormal neuronal migration**
 - Periventricular nodular heterotopia
 - Lissencephaly/subcortical band heterotopia
 - Cobblestone cortex/congenital muscular dystrophy
- **Abnormal cortical organization**
 - Polymicrogyria
 - Focal Cortical Dysplasia

Five outcomes are possible in the MCDs:

1. Fewer or more than normal neurons are produced (microcephaly, megalencephaly).
2. Neurons do not migrate at all from the ventricles (periventricular heterotopia) or migrate half way (subcortical band heterotopia).
3. Some neurons reach the cortex but large numbers do not. No normal cortical layers are formed (lissencephaly, pachygyria, cobblestone cortex).
4. Neurons over-shoot the cortex and end up in the subarachnoid space (marginal-leptomeningeal glioneuronal heterotopia, cobblestone cortex).
5. The late stage of migration and cortical organization is disrupted (polymicrogyria).

Craniosynostosis

- **Brachycephaly:** Bicoronal and/or lambdoid sutures
- **Scaphocephaly/dolichocephaly:** Sagittal suture
- **Plagiocephaly:** Unilateral coronal and lambdoid sutures
- **Trigonocephaly:** Metopic suture

- **Pachycephaly:** Lamdoid suture
- **Oxycephaly/turriccephaly:** Sagittal, coronal and lambdoid sutures (tower-like skull) combined synostosis
- **Cloverleaf skull:** Intrauterine sagittal, coronal, lambdoid sutures (most severe).

CJD

MRI findings may be bilateral or unilateral and symmetric or asymmetric, and include:

- **T2:** hyperintensity
 - Basal ganglia (putamen and caudate)
 - Thalamus (hockey stick sign and pulvinar sign)
 - Cortex: most common early manifestation
 - White matter
- **DWI/ADC:** persistent restricted diffusion (**considered the most sensitive sign**)

Review of sequential studies also typically demonstrates rapidly progressive cerebral atrophy.

Nuclear Medicine

- Hypometabolism on ^{18}F FDG-PET studies.

Myelography

- Extradural block → feathered appearance
- Intradural extramedullary → meniscus sign (widening of CSF space)
- Intramedullary → trouser leg appearance.

QUESTIONS

1. **Bracket calcification on skull X-ray is seen in:**
 - a. Tuberculosis
 - b. Sturge-Weber Syndrome
 - c. Corpus callosum lipoma
 - d. Meningioma
2. **Puff of smoke appearance on cerebral angiography is seen in:**
 - a. ACA aneurysm
 - b. Cavernous sinus thrombosis
 - c. Moyamoya disease
 - d. Vein of Galen malformation
3. **A 7-year-old patient presents with severe headache, paralysis of upward gaze, loss of light perception and accommodation, nystagmus and failure of convergence. CT scan showed homogenous hyperdense lesion above the sella and in the posterior part of the third ventricle. MRI showed that the lesions were homogenous and isointense on T1 weighted imaging, and isointense on T2 weighted imaging with intense contrast enhancement. The most likely diagnosis is:**
 - a. Teratoma
 - b. Germinoma
 - c. Dermoid
 - d. Choroid plexus carcinoma
4. **Which of the followings is used to differentiate between the epidermoid cyst and arachnoid cyst?**
 - a. Contrast enhancement
 - b. Restricted diffusion
 - c. CSF signals on FLAIR
 - d. Smooth margin
5. **Investigation of choice for leptomeningeal carcinomatosis:**
 - a. PET
 - b. SPECT
 - c. Gadolinium enhanced MRI
 - d. CT scan
6. **A middle aged female presents with slowly progressive weakness of lower limbs, spasticity and recent onset hesitancy of Micturition. On neurological examination there is evidence of dorsal myelopathy. MRI scan of spine reveals mid dorsal intradural contrast enhancing mass lesion. Diagnosis is:**
 - a. Intradural lipoma
 - b. Dermoid cyst
 - c. Meningioma
 - d. Epidermoid cyst
7. **A patient was diagnosed with intracranial cavernous angioma on MR scan. MRI finding characteristic of the lesion is:**
 - a. Well defined nidus
 - b. Well defined arterial feeders
 - c. Phlebectasis
 - d. Reticulated 'popcorn-like' configuration
8. **Which of the following is the investigation of choice for evaluation of acute head injury?**
 - a. NCCT Head
 - b. CECT Head
 - c. MRI Brain
 - d. PET scan
9. **Posterior scalloping of vertebral bodies is seen in:**
 - a. Aortic aneurysm
 - b. Neurofibromatosis
 - c. Lymphadenopathy
 - d. Cretinism
10. **Meningiomas occur at all the following sites except:**
 - a. Lateral cerebral convexities
 - b. Basal ganglia

- c. Cerebello pontineangles
 - d. Foramen magnum
11. **On MRI, the differential diagnosis of spinal cord edema is:**
- a. Myelodysplasia
 - b. Myelomalacia
 - c. Myeloschisis
 - d. Cord tumors
12. **Insult during neuronal migration results in delayed neuronal migration and organization, which results in certain disorders. The least likely possibility is:**
- a. Polymicrogyria
 - b. Schizencephaly
 - c. Lissencephaly
 - d. Focal cortical dysplasia without balloncells
13. **A middle aged man presents with progressive atrophy and weakness of hand and forearms. On examination he is found to have slight spasticity of the leg, generalized hyperreflexia and increased signal in the cortico-spinal tracts on T2 weighted MRI. The most likely diagnosis is:**
- a. Multiple sclerosis
 - b. Amyotrophic lateral sclerosis
 - c. Subacute combined degeneration
 - d. Progressivespinalmuscularatrophy
14. **All except are true about MS:**
- a. Corpus callosum lesions are characteristic
 - b. Periventricular white matter distribution with decreased CT attenuation
 - c. T1 WI are most diagnostic for acute plaques
 - d. 4th ventricle, 5th nerve entry site and brachium pontis are involved
 - e. Hyperintense T2WI'
15. **The MRI Imaging in multiple sclerosis will show lesions in:**
- a. White matter
 - b. Grey matter
 - c. Thalamus
 - d. Basal ganglia
16. **A child presented with clinical features of demyelination. The chances of progression to MS is least with which of the following:**
- a. Absent oligoclonal band
 - b. Bilateral visual loss
 - c. Poor recovery
 - d. Cord complete transaction
17. **Extensive involvementto deep white matter with bilateral hyperdense thalami on non-contrast CT scan of the brain is virtually diagnostic of:**
- a. Alexander's disease
 - b. Krabbe's disease.
 - c. Canavan's disease
 - d. Metachromatic leukodystrophy
18. **Which of the following is not a MRI feature of mesial temporalsclerosis:**
- a. Atrophy of mammillary body
 - b. Atrophy offornix
 - c. Blurring of grey and white matter junction of ipsilateral temporallobe
 - d. Atrophy of hippocampus
19. **A new born presents with congestive heart failure resistant to treatment, on examination has bulging anterior fontanelle with a bruit on auscultation. Transfontanellar USG shows hypoechoic midline mass with dilated lateral ventricles. Most likely diagnosis is:**
- a. Encephalocele
 - b. Medulloblastoma
 - c. Arachnoidcyst
 - d. Vein of Galen malformation
20. **All are the characteristics of raised ICP on plain radiology except:**
- a. Erosion of dorsum sella
 - b. Ballooning of sella
 - c. Increased convolutions
 - d. Sutural diastasis

21. A male was brought unconscious to the hospital with external injuries. Cf shows nomidlineshift, but basal cisterns were compressed with multiple small hemorrhages. The most probable diagnosis is:
- Brain contusion
 - Diffuse axonal injury
 - Subdural hemorrhage
 - Multiple infarct
22. A 15-year-old boy had 10-12 partial complex seizures per day inspite of adequate 4 drug antiepileptic regime. He had history of repeated high grade fever in childhood. MRI for epilepsy protocol revealed normal brain scan. What should be the best non-invasive strategy to make a definite diagnosis so that he can be prepared to undergo epilepsy surgery:
- Interictal scalp EEG
 - Video EEG
 - Interictal 18F-FDG PET
 - Video EEG with Ictal 99m Tc-HMPAO Brain SPECT
23. Basal exudates, infarcts and hydrocephalus on computed tomography are seen in:
- Tuberculous meningitis
 - Viral meningitis
 - Herpes simplex encephalitis
 - Cerebralmalaria/neurocysticercosis
24. Focal cerebral lesion with ring on CT scan is caused by:
- Toxoplasmosis
 - Intracranial hemorrhage
 - Cysts
 - Hamartoma
25. Suprasellar calcification is characteristic of:
- Medulloblastoma
 - Craniopharyngioma
 - Meningioma
 - Ependymoma
26. Suprasellar calcification with growth retardation:
- Pineal body tumor
 - Pituitary tumor
 - Thalamic tumor
 - Craniopharyngioma
27. Which of the following is the most common mixed cystic and solid suprasellar mass seen on scan of a 10-year-old child:
- Pituitary adenoma
 - Craniopharyngioma
 - Optic chiasmoglioma
 - Germinoma
28. A 6-year-old boy has been complaining of ignoring to see the objects on the side for 4 examination, he is not mentally retarded, school are good and visual acuity is diminished eyes, visual charting showed significant field scan of the head showed supra sellar mass with <AUCDI Which of the following is the most probable?
- Astrocytoma
 - Craniopharyngioma
 - Pituitary adenoma
 - Meningioma
29. Tumor associated with extra cranial spread:
- Ependymoma
 - Medulloblastoma
 - Glioblastomamultiforme
 - Choroid plexuspapilloma
30. In 7-year-old boy presented with posterior fossa mass with cyst formation, hypodense on CT, hyper intense on T2WI and showing post gadolinium nodule enhancement is:
- Medulloblastoma
 - Ependymoma
 - Astrocytoma
 - Cysticercosis

31. 35-year-old patient presents with complaints of headache, vomiting (raised ICT) and ataxia. MRI findings are well demarcated cystic lesion with a mural nodule in the right cerebellar hemisphere with homogeneous contrast enhancement. The most likely diagnosis is:
- Ependymoma
 - Hemangioblastoma
 - Pilocytic astrocytoma
 - Medulloblastoma
32. Which of the following tumor is typically associated with VLH:
- Hemangioblastoma
 - Hemangioendothelioma
 - Neurofibroma
 - Glioma
33. All is true about von Hippel Lindau syndrome except:
- Hemangioblastomas seen in craniospinal axis
 - Multiple tumors common
 - Tumors of Schwann cells are common
 - Supratentorial lesions are uncommon
34. A child presents with raised ICT. On CT scan, a lesion is seen around foramen of Monro with multiple periventricular calcific foci. What could be probable diagnosis?
- Subependymal giant cell astrocytoma (SGCA)
 - Subependymoma or ependymoma
 - Pilocytic astrocytoma
 - Neurocytoma
35. Investigation of choice for a lesion of temporal bone:
- CT
 - MRI
 - USG
 - Plain X-ray
36. Wide neural foramina is associated with:
- Neurofibromatosis type 1
 - Sturge-Weber syndrome
 - Von Hippel Lindau disease
 - Tuberous sclerosis
37. True about MRI/CT appearance of lateral meningocele are all except:
- Solid dural masses
 - Usually outside the spinal canal
 - Widened neural foramen
 - Generally there is no spinal cord compression and deformity
38. Mesencephalo-oculo-facial angiomatosis is seen in:
- KTW syndrome
 - NF-1 and 2
 - Sturge-Weber syndrome
 - Wyburn-Mason syndrome
39. Tram-track appearance on CT scan of head is seen in:
- Sturge Weber syndrome
 - Von Hippel Lindau syndrome
 - Tuberous sclerosis
 - Neurofibroma
40. Vertical linear striations are typically seen in
- Vertebral myeloma
 - Vertebral lymphangiomas
 - Vertebral metastasis
 - Vertebral hemangiomas
41. Earliest sign of raised ICT is:
- Erosion of dorsum sellae
 - Copper beaten appearance
 - Silver beaten appearance
 - Displacement of pineal gland
42. Intracranial calcification with cystic lesion in plain X-ray skull is seen in:
- Meningioma
 - Glioma
 - Craniopharyngioma
 - Medulloblastoma

43. **Basal ganglia calcification is seen in all except:**
- Hypoparathyroidism
 - Wilson's disease
 - Perinatal hypoxia
 - Fahr's syndrome
44. **In children raised ICT is manifested by:**
- Lytic lesions in skull
 - Rarefaction of dorsum of sella
 - Sutural diastasis
 - None of the above
45. **Finding in meningioma are all except:**
- Vascular markings around falx
 - Calcification
 - Erosions
 - Osteosclerosis
46. **Characteristic features of meningioma are all except:**
- Dural tail sign
 - Hyperostosis
 - Prominent vascularity
 - Intra-axial tumor
47. **A 20-year male patient with 6th cranial nerve palsy on T2 weighted MRI shows a markedly hyperintense lesion in cavernous sinus which shows intense homogenous contrast enhancement. Most probable diagnosis:**
- Schwannoma
 - Meningioma
 - Cavernous sinus hemangioma
 - Astrocytoma
48. **Periventricular calcification is often due to:**
- Toxoplasmosis
 - CMV infection
 - Congenital syphilis
 - All of the above
49. **Subdural hematoma most commonly results from:**
- Rupture of intracranial aneurysm
 - Rupture of cerebral AVM
 - Injury to cortical bridging veins
 - Hemophilia
50. **Which of the following is classic CT appearance of acute subdural hematoma?**
- Lentiform-shaped hyperdense lesion
 - Crescent-shaped hypodense lesion
 - Crescent-shaped hyperdense lesion
 - Lentiform-shaped hypodense lesion
51. **CT scan of a patient with history of head injury shows a biconvex hyperdense lesion displacing the grey-white matter interface. The most likely diagnosis:**
- Subdural hematoma
 - Diffuse axonal injury
 - Extradural hematoma
 - Hemorrhagic contusion
52. **Which tumor is suggested by "Trouser leg Appearance" on an ascending myelogram?**
- Extradural
 - Extramedullary
 - Intramedullary
 - Vertebral
53. **The first investigation of choice in a patient with suspected subarachnoid hemorrhage should be:**
- Non-contrast computed tomography
 - CSF examination
 - Magnetic resonance imaging (MRI)
 - Contrast-enhanced computed tomography
54. **The best investigation to diagnose a case of acoustic neuroma is:**
- Gadolinium enhanced MRI
 - CT scan
 - Audiometric analysis
 - PET scan

55. Which of the following is the best choice to evaluate radiologically a posterior fossa tumor?
- CT scan
 - MRI
 - Angiography
 - Myelography
56. Parameningeal Rhabdomyosarcoma is best evaluated by:
- MRI
 - CT scan
 - SPECT
 - PET
57. Cerebral blood flow in an asphyxiated child is best measured by:
- NIRS
 - PET
 - Radionuclide imaging
 - MIU angiography
58. Investigation which should not be done in a patient with brain tumor:
- CT Scan
 - Lumber puncture
 - MRI
 - X-ray
59. All are X-ray findings of retinoblastoma except:
- Widening of optic canal
 - Intracerebral calcification
 - Intraocular calcification
 - Secondaries in cranial bones
60. Investigation of choice in parathyroid pathology is
- CT Scan
 - Gallium Scan
 - Thallium Scan
 - Tc - Thallium subtraction scan
61. Best view for visualizing sella turcica on X-ray:
- AP View
 - Town's view
 - Lateral view
 - Open mouth view
62. 30-year-old man presents with 6 month history of nasal discharge, facial pain and fever. On antibiotic therapy, fever subsided. After 1 month again had symptoms of mucopurulent discharge from the middle meatus and the mucosa of the meatus appeared congested and oedematous. Next best investigation would be:
- MRI of the sinuses.
 - Non-contrast CT of the nose and para-nasal sinuses
 - Plain X-ray of the paranasal sinuses
 - Inferior meatus puncture
63. Basal skull view (submentovertical view) X-ray is best to visualize:
- Ethmoid sinus
 - Frontal sinus
 - Sphenoid sinus
 - Maxillary sinus
64. Rabbit ear sign is seen in:
- Bilateral subdural hematoma in CT
 - Unilateral subdural hematoma in CT
 - Bilateral subarachnoid hemorrhage
 - Unilateral subarachnoid hemorrhage
65. Bat wing deformity of cerebral ventricles on CT/MRI is seen in:
- bilateral subdural hematoma
 - bilateral subarachnoid hemorrhage
 - agenesis of corpus callosum
 - agenesis of cerebral ventricles
66. "Face of giant panda" sign on MRI brain is seen in:
- Wilson's disease
 - Japanese encephalitis
 - Rasmussen's encephalitis
 - Wernicke's encephalopathy
67. The markedly hypointense globus pallidus on T2W MRI surrounding a higher-intensity center due to excess iron accumulation and central gliosis is characteristic of:
- Krabbe's disease
 - Joubert syndrome
 - Lhermitte-Duclos disease
 - Hallervorden-Spatz disease

68. **Abnormal signals in bilateral thalami on MRI brain is seen in:**
- Wilson's disease
 - Japanese encephalitis
 - Wernicke's encephalopathy
 - Rasmussen's encephalitis
69. **Following tumors are known to occur with VHL disease except:**
- Endolymphatic sac tumors
 - Pheochromocytomas
 - Mandibular osteomas
 - Islet cell tumors
70. **A 16-year-old girl with complex partial seizures and mild mental retardation has an area of deep red discoloration (port-wine nevus) extending over her forehead and left upper eyelid. A CT scan of her brain would be likely to reveal:**
- Hemangioblastoma
 - Charcot-bouchard aneurysm
 - Arteriovenous malformation
 - Leptomeningeal angioma
71. **Tests for suspected cases of cerebrovascular syncope include the following except:**
- Carotid Doppler
 - MRI brain
 - EEG
 - MRA
72. **The 'Light-bulb' sign on DWMRI?**
- Agarwal's disease
 - Hyperacute stroke
 - Vanishing bone disease
 - Marchiafava-Bignami disease
73. **High-signal, oblong, elliptical lesions at the calloseseptal interface and subependymal periventricular white matter oriented perpendicular to the ventricular surface on FLAIR and T2W MR images are diagnostic of:**
- Multiple sclerosis
 - Moya Moya disease
 - Periventricular leukomalacia
 - Posterior reversible encephalopathy syndrome
74. **The "salt-and-pepper" appearance on T1MRI is hallmark of paragangliomas. The 'salt' and 'pepper' of which represent respectively.**
- Zallbens and multiple flow voids
 - Zallbens and discrete calcific foci
 - Subacute hemorrhages and calcific foci
 - Subacute hemorrhages and flow voids
75. **A 33-year-old woman has the acute onset of right orbital pain. On examination, she has a mild right ptosis and anisocoria. The right pupil is 2 mm smaller than the left, but both react normally to direct light stimulation. Visual acuity, visual fields, and eye movements are normal. Magnetic resonance imaging (MRI) in this patient would be expected to show which of the following?**
- Increased t2 signal in a periventricular distribution
 - Contrast enhancement along the tentorial margin
 - Increased t1 signal in the wall of the right carotid artery
 - Enlarged optic nerve in the orbit
76. **A 75-year-old man with a history of recent memory impairment is admitted with headache, confusion, and a left homonymous hemianopsia. He has recently had two episodes of brief unresponsiveness. There is no history of hypertension. CT scan shows a right occipital lobe hemorrhage with some subarachnoid extension of the blood. An MRI scan with gradient echo sequences reveals foci of hemosiderin in the right temporal and left frontal cortex. The likely diagnosis is:**
- Gliomatosis cerebri
 - Multi-infarct dementia
 - Mycotic aneurys
 - Amyloid angiopathy

77. **Transfemoral angiogram is most useful in diagnosis of:**
- Cerebral aneurysms
 - Gliomas
 - Multiinfarct dementia
 - Venous sinus thrombosis
78. **A 73-year-old man with a history of hypertension complains of a transient 10-min episode of left-sided weakness and slurred speech. On further questioning, he relates three brief episodes in the last month of sudden impairment of vision affecting the right eye. His examination now is normal. Which of the following would be the most appropriate next diagnostic test?**
- Holter monitoring
 - Spect scan
 - Carotid doppler study
 - Cerebral angiography
79. **"Eye of tiger" sign on brain mri is characteristic of:**
- Krabbe's disease
 - Joubert syndrome
 - Lhermit duclos disease
 - Hallervorden-spatz disease
80. **The most definitive test for identifying intracranial aneurysms is:**
- MRI scanning
 - CT scanning
 - Positron emission tomography
 - Cerebral angiography
81. **Corpus callosum lesions are characteristically seen in the following conditions:**
- Spe
 - Krabbe's disease
 - Phytanic acid deficiency
 - Butterfly glioma
82. **The location of the cerebellar tonsil in the MRI scan is helpful in diagnosis of:**
- Arnold-chiari type 1 malformation
 - Neurofibromatosis type 2
 - Giant cisterna magna
 - Dandy-walker syndrome
83. **The tentorium cerebelli which separates the superior cerebellum from the cerebrum is a common site of origin for:**
- Meningiomas
 - Ependymomas
 - Hemangioblastomas
 - Medulloblastomas
84. **Radiological findings in meningioma include all of the following except:**
- Calcification
 - Vascular markings
 - Hyperostosis
 - Absent dural-tail sign
85. **Which one of the following brain tumors is highly vascular in nature?**
- Glioblastoma
 - Meningiomas
 - C p angle epidermoid
 - Pituitary denomas
86. **A 43-year-old man experiences dizziness and tinnitus. CT shows enlarged internal acoustic meatus. What is the diagnosis?**
- Vestibular schwannoma
 - Arachnoid cyst
 - Pituitary adenoma
 - Medulloblastoma
87. **"Ice-cream cone" sign on MRI brain is seen in:**
- Pilocytic astocytoma
 - Acoustic neuroma
 - Glomus jugulare
 - Meningioma
88. **In skull X-ray commonest cause of intracerebral calcified shadow is:**
- Pituitary adenoma
 - Oligodendroglioma
 - Astrocytoma
 - Glioma
89. **Which of the following variety of craniopharyngioma characteristically occurs in childhood?**

- a. Cellular
 - b. Melanotic
 - c. Tanycytic
 - d. Admantinomatous
90. **Premature closure of coronal, sagittal, and lambdoid sutures results in:**
- a. Oxycephaly
 - b. Turricephaly
 - c. Plagiocephaly
 - d. Trigenocephaly
91. **In the diffuse axonal injury, the typical location of lesions in the brain include:**
- a. Parasagittal region
 - b. Cerebral cortex
 - c. Ventricles
 - d. White matter of cerebral hemispheres, corpus callosum and the upper brain stem
92. **'Tear-drop' appearance on PNS X-ray is seen in:**
- a. Fracture of medial wall of the orbit
 - b. Fracture of maxillary sinus
 - c. Fracture of ethmoidal sinus
 - d. Fracture floor of the orbit
93. **"Hair on end" appearance in skull X-ray is characteristic of:**
- a. Sickle cell anemia
 - b. Thalassemia
 - c. Megaloblastic anemia
 - d. Hemochromatosis
94. **Imaging tool of choice for cjd:**
- a. Dwmri with adc mapping
 - b. Hmpao spect scan
 - c. Mr spectroscopy
 - d. Pet scan
95. **A patient with 2 months history of trauma to eye. Now he presents with ocular damage, multiple cranial nerves involvement, what is the best investigation?**
- a. MRI
 - b. CT
 - c. DSA
 - d. MRA
96. **Investigation of choice for meningeal carcinomatosis:**
- a. Non contrast CT
 - b. Contrast MRI
 - c. SPECT
 - d. PET
97. **A 21-year-old woman presents with right arm loss of sensation that has been progressive over a few days. Her physician is concerned that this might be some type of demyelinating disorder. A relatively small plaque of demyelination, should be evident on which of the following?**
- a. T1-weighted MRI
 - b. T2-weighted MRI
 - c. Precontrast CT
 - d. Diffusion-weighted MRI
98. **Calcification around foramen of monro with raise ICT; periventricular calcification with mass below 3rd ventricle:**
- a. Ependymoma
 - b. subependymal-astrocytoma
 - c. medulloblastoma
 - d. DNET
99. **Frontal Sinus can be best visualized by:**
- a. Caldwell's view
 - b. Water's view
 - c. Towne's view
 - d. Schüller's view
100. **The nodular pattern often seen in the lungs post transplantation is thought to be due to:**
- a. Tuberculosis
 - b. Infarcts
 - c. Cytomegalovirus
 - d. Autoimmune reaction
101. **Which of the following feature of thyroid nodule on Ultrasonogram is not suggestive of malignancy?**
- a. Hyperechogenicity
 - b. Hypoechogenicity
 - c. Nonhomogeneous
 - d. Microcalcification

102. **Empty delta sign is seen in:**
- Dissecting aortic aneurysm
 - Jugular venous thrombosis
 - Superior sagittal sinus thrombosis
 - Deep venous thrombosis
103. **First sign of hydrocephalus in children is:**
- Post clinoid erosion
 - Large head
 - Sutural diastasis
 - Thinned out vault
104. **Punctuated lesions and floating teeth are seen in:**
- Metastasis
 - Osteitis fibrosa
 - Histiocytosis
 - Asbestosis
105. **Hyperintense corticospinal tract on T2WIMRI is/ are seen in:**
- Astrocytoma
 - Amyotrophic lateral sclerosis
 - Hemochromatosis
 - Wilson disease
106. **Epidermoid cyst can be differentiated from arachnoid cyst by:**
- MRI
 - USG
 - Myelography
 - CT scan
107. **Prevertebral space thickness in adult is:**
- 7 mm
 - 14 mm
 - 22 mm
 - 30 mm
108. **'Thumb print' sign seen in:**
- Candida
 - Aspergillus
 - Thermomyces
 - Epiglottitis
109. **Dawson finger in brain seen in which condition?**
- Cortical vein thrombosis
 - Multiple sclerosis
 - Lacunar infarcts
 - Alzheimer's disease
110. **Normal brain calcifications are present in:**
- Pineal gland
 - Choroidsplexus
 - Thalamus
 - Duramater
 - Hypothalamus
111. **Bare orbitals/are seen in:**
- Metastasis
 - Neuroblastoma
 - Optic nerve glioma
 - Osteomyelitis
 - Pseudotumor cerebri
112. **J-shaped sella is/are seen in:**
- Mucopolysaccharidoses
 - Achondroplasia
 - Optic chiasm glioma
 - Neurofibromatosis
 - Hydrocephalus
113. **Physiological calcification of skull in X-ray is seen in:**
- Pineal gland
 - Choroid plexus
 - Red nucleus
 - Basal ganglion
 - Habenular
114. **Which one of the following tumors shows calcification on CT scan?**
- Ependymoma
 - Medulloblastoma
 - Meningioma
 - CNS lymphoma
115. **Ring enhancing lesion in brain is/are seen in:**
- Brain abscess
 - Resolving hematoma
 - Primary CNS lymphoma
 - Encephalopathy
 - Infarction
116. **Caldwell view (occipito-frontal) can visualize:**
- Sphenoid sinus
 - Nasal bone
 - Maxillary sinus
 - Ethmoid sinus
 - Frontal sinus

Multiple Correct Answers

110. **Normal brain calcifications are present in:**
- Pineal gland
 - Choroidsplexus

ANSWER KEYS

1. **Ans. c.** Corpus callosumlipoma
2. **Ans. c.** Moyamoyadisease
3. **Ans. b.** Germinoma
4. **Ans. b.** Restricted diffusion
5. **Ans. c.** Gadolinium enhanced MRI
6. **Ans. c.** Meningioma
7. **Ans. d.** Reticulated popcorn-like configuration
8. **Ans. a.** NCCT Head
9. **Ans. b.** Neurofibromatosis
10. **Ans. b.** Basalganglia
11. **Ans. b.** Myelomalacia
12. **Ans. b.** Schizencephaly
13. **Ans. b.** Amyotrophic lateral sclerosis
14. **Ans. c.** T1 WI are most diagnostic for acute plaques
Ref: Dahnert Wolfgang 7/e p3131.
15. **Ans. a.** White matter
Ref. Dahnert Wolfgang 7 Iep 313.
16. **Ans. a.** Absent oligoclonal band
Natural history studies have shown that a younger age at disease onset is associated with a higher risk of conversion to clinically definite multiple sclerosis (CDMS) and that male gender is associated with a greater accumulation of disability according to the Kurtzke Expanded Disability Status Scale (EDSS) (Kurtzke, 1983; Weinshenker et al., 1989a, b; Confavreux et al., 2003; Confavreux and Vukusic, 2006a, b; Tremlett et al., 2006; Leray et al., 2010; Scalfari et al., 2010). Regarding the clinical characteristics, patients with CIS presenting with optic neuritis exhibit a lower risk of developing both multiple sclerosis and disability accumulation compared with CIS patients displaying other topographic characteristics (Weinshenker et al., 1989a; Runmarker and Andersen, 1993; Confavreux et al., 2003). Regarding biological factors, a recent meta-analysis showed that the presence of IgG oligoclonal bands increases both the risk of experiencing a second attack and the risk of disability accumulation (Dobson et al., 2013). To date, brain MRI remains the most reliable tool to predict future conversion to multiple sclerosis or the accumulation of disability. In this context, it has been demonstrated that a larger number of brain T2 lesions or Barkhof criteria based on a baseline MRI correlates with an increased risk of developing multiple sclerosis and disability in the mid- to long-term
17. **Ans. b.** Krabbe's disease.
18. **Ans. c.** Blurring of grey and white matter junction of ipsilateral temporal lobe
19. **Ans. d.** Vein of Galen malformation
20. **Ans. b.** Ballooning of sella
21. **Ans. b.** Diffuse axonal injury
22. **Ans. d.** Video EEG with Ictal 99m Tc-HMPAO Brain SPECT
23. **Ans. a.** Tuberculous meningitis
24. **Ans. a.** Toxoplasmosis
25. **Ans. b.** Craniopharyngioma
26. **Ans. d.** Craniopharyngioma
27. **Ans. b.** Craniopharyngioma
28. **Ans. a.** Craniopharyngioma
29. **Ans. b.** Ependymoma
30. **Ans. c.** Astrocytoma
31. **Ans. b.** Hemangioblastoma
32. **Ans. a.** Hemangioblastoma
33. **Ans. c.** Tumors of Schwann cells are common

34. **Ans. a.** Subependymal giant cell astrocytoma (SGCA)
35. **Ans. a.** CT
36. **Ans. a.** Neurofibromatosis type 1
37. **Ans. a.** Solid dural masses
38. **Ans. d.** Wyburn-Mason syndrome
Sturge-Weber syndrome or encephalotrigeminal or encephalotrigeminal angiomatosis a cutaneous, facial angioma in the distribution of the trigeminal nerve, and an ipsilateral, distribution of the trigeminal nerve, and an ipsilateral, parietal parietal-occipital vascular malformation. occipital vascular malformation.
Rendu-Osler-Weber syndrome (hereditary (hereditary hemorrhagic telangiectasia) is an autosomal hemorrhagic telangiectasia) is an autosomal-dominant dominant syndrome of multiple visceral, mucosal and cerebral syndrome of multiple visceral, mucosal and cerebral vascular malformations. vascular malformations.
Wyburn-Mason (Bonnet-Blanc- Dechaume syndrome) Dechaume syndrome) or mesencephalo or mesencephalo-oculo-facial angiomatosis corresponds facial angiomatosis corresponds to the association of unilateral retinal angiomatosis and a to the association of unilateral retinal angiomatosis and a cutaneous hemangioma in an ipsilateral trigeminal cutaneous hemangioma in an ipsilateral trigeminal distribution with an AVM located in the midbrain
39. **Ans. a.** Sturge Webersyndrome
40. **Ans. d.** Vertebralhemangiomas
41. **Ans. a.** Erosion of dorsumsella
42. **Ans. c.** Craniopharyngioma
43. **Ans. b.** Wilson's disease
44. **Ans. c.** Suturaldiastasis
45. **Ans. c.** Erosions
46. **Ans. d.** Intra-axialtumor
47. **Ans. c.** Cavernous sinus hemangioma
48. **Ans. b.** CMV infection
49. **Ans. c.** Injury to cortical bridgingveins
50. **Ans. c.** Crescent-shaped hyperdenselesion
51. **Ans. c.** Extraduralhematoma
52. **Ans. c.** Intramedullary
53. **Ans. a.** Non-contrast computed tomography
54. **Ans. a.** Gadolinium enhanced MRI
55. **Ans. b.** MRI
56. **Ans. a.** MRI
57. **Ans. a.** NIRS
58. **Ans. b.** Lumbar Puncture
59. **Ans. b.** Intracerebral calcification
60. **Ans. d.** Tc-Thallium subtraction scan
61. **Ans. c.** Lateral view
62. **Ans. b.** Non-contrast CT of the nose and para-nasal sinuses
63. **Ans. c.** Sphenoid sinus
 Skull-SMV (Submentovertex) (also called Basal)
 Area Covered: This view looks at the base of the skull, including structures such as the foramen ovale, foramen spinosum, and sphenoid sinuses
64. **Ans. a.** bilateral subdural hematoma in CT
65. **Ans. c.** Agenesis of corpus callosum
66. **Ans. a.** Wilson's disease
67. **Ans. d.** Hallervorden-Spatz disease
68. **Ans. b.** Japanese encephalitis
69. **Ans. c.** Mandibular osteomas
70. **Ans. d.** Leptomeningeal angioma
71. **Ans. c.** EEG
72. **Ans. b.** Hyperacute stroke
73. **Ans. a.** Multiple sclerosis

74. **Ans. d.** Subacute hemorrhages and flow voids
75. **Ans. c.** Increased t1 signal in the wall of the right carotid artery
76. **Ans. d.** Amyloid angiopathy
77. **Ans. a.** Cerebral aneurysms
78. **Ans. c.** Carotid doppler study
79. **Ans. d.** Hallervorden-spatz disease
80. **Ans. d.** Cerebral angiography
81. **Ans. d.** Butterfly glioma
82. **Ans. a.** Arnold-chiari type 1 malformation
83. **Ans. a.** Meningiomas
84. **Ans. d.** Absent dural-tail sign
85. **Ans. b.** Meningiomas
86. **Ans. a.** Vestibular schwannoma
87. **Ans. b.** Acoustic neuroma
88. **Ans. b.** Oligodendroglioma
- *Most common intra axial brain tumor to show calcification is oligodendroglioma*
 - *90% of Oligodendroglioma show calcification when only 20% of astrocytoma shows calcification*
 - *Most common brain tumor to show calcification is Craniopharyngioma however, it is extra axial*
89. **Ans. d.** Adamantinomatous
- *Adamantinomatous (paediatric) ~90% 9*
 - *Papillary (adult) ~10 %9*
 - *Mixed: ~15%, but share imaging and prognosis similar to adamantinomatous*
90. **Ans. b.** Turricephaly
91. **Ans. d.** White matter of cerebral hemispheres, corpus callosum and the upper brain stem
92. **Ans. d.** Fracture floor of the orbit
93. **Ans. b.** Thalassemia
94. **Ans. a.** Dwmri with adc mapping
95. **Ans. a.** MRI
96. **Ans. b.** Contrast MRI
97. **Ans. b.** T2-weighted MRI
98. **Ans. b.** Subependydomal-astrocytoma
99. **Ans. a.** Caldwell's view
100. **Ans. c.** Cytomegalovirus
101. **Ans. a.** Hyperechogenicity
102. **Ans. c.** Superior sagittal sinus thrombosis
103. **Ans. c.** Sutural diastasis
104. **Ans. c.** Histiocytosis
105. **Ans. b.** Amyotrophic lateral sclerosis
106. **Ans. a.** MRI
107. **Ans. b.** 14 mm
108. **Ans. d.** Epiglottitis
109. **Ans. b.** Multiple sclerosis

Multiple Correct Answers

110. **Ans. a.** Pineal gland, **b.** Choroids-plexus
111. **Ans. a.** Metastasis, **b.** Neuroblastoma
112. **Ans. a.** Mucopolysaccharidoses, **b.** Achondroplasia, **c.** Optic-chiasm glioma, **d.** Neurofibromatosis, **e.** Hydrocephalus
113. **Ans. a.** Pineal gland, **b.** Choroid plexus, **d.** Basal ganglion, **e.** Habenular
114. **Ans. a.** Ependymoma, **c.** Meningioma
115. **Ans. a.** Brain abscess, **b.** Resolving hematoma, **c.** Primary CNS lymphoma
116. **Ans. b.** Nasal bone, **d.** Ethmoid sinus, **e.** Frontal sinus

3

Cardiothoracic Radiology

Normal Chest X-ray

- Film focus distance is 100 cm for all X-rays except **chest X-ray** → 180 cm/6 feet
- **PA view** → 40% of lungs are covered by ribs and soft tissue
- Exposure made by centering at T5, full inspiration and breasts compressed to avoid obscuration of lungs.

Signs of AP X-ray

- Scapulae overlie the lungs
- Ribs move horizontally
- Stomach bubble usually absent
- Clavicles project over the apices.

High KVP—Preferred to reduce visibility of bony rib cage (120–170 KVP) → Penetrate even mediastinum/heart to see retrocardiac areas.

Low KVP → To see miliary nodules and calcifications

Best views:

- Right lung → Left anterior oblique
- Left lung → Right anterior oblique

Contributors of Normal Hilum

- **Upper lobe veins and pulmonary arteries (major contribution)**
- Lower lobe veins do not contribute
- Left hilum is higher as left pulmonary artery pass above bronchus
- Lymphatics and lymph nodes do not contribute in normal hilar shadow

Thymus

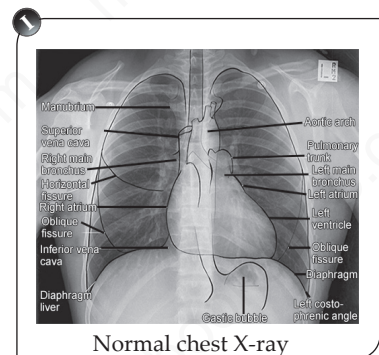
- By the age of 40 years, replaced by fat except for a few streaks/nodules of residual thymus
- **Sail sign** → Triangular shape of thymus.

FFD is 180 cm in CXR to reduce magnification of heart shadow.

Hilar point—where superior pulmonary veins cross the descending lower lobe artery. (Left at a bit higher level than right)

Transverse diameter of lower lobe arteries before their segmental division is 9–16 mm on PA view.

On right side, the P. artery and vein can give density as if mass while on Left, there is bronchus in between the two.

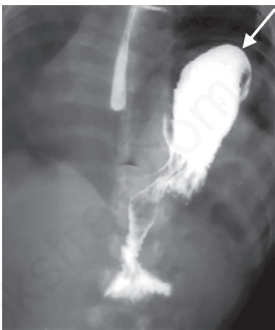


Normal chest X-ray

If thickening or fat in lower part of oblique fissure/inferior pulmonary ligament-juxtaphrenic peak sign.

- Right hemidiaphragm is higher than left due to slight depression of left by heart
- In dextrocardia; hence, Right hemidiaphragm is lower

- Diaphragmatic movement better by fluoroscopy but if patient is sick—usg
- Paralyzed diaphragm does not thicken during inspiration.



Bochdalek's hernia with herniation of stomach into thorax with contralateral mediastinal shift on barium meal study

- **Wave sign of Mulvey** → indentations on thymus by ribs
- **Notch sign** → Indentation due to heart
 - Shape of thymus change with respiration and position.

Facts

- Calcifications common in benign lesion
- Midline nodes considered ipsilateral in malignant spread
- Blunting of c.p. angle can be Normal in athletes
- In few, the Left hemidiaphragm can be higher up to 1.0 cm normally (due to gaseous abdomen) but to call it abnormal, it should be > 3.0 cm higher.

Causes of Bilateral Symmetrical Elevation of Diaphragm

- Diffuse pulmonary fibrosis
- Lymphangitis carcinomatosa
- Abdominal causes (obesity, pregnancy, ascites)
- Bilateral diaphragmatic paralysis
- Bilateral basal pulmonary emboli
- Unequal excursions of diaphragm usually < 10 mm.

| Bochdalek hernia | Morgagni hernia |
|--|---|
| <ul style="list-style-type: none"> • Congenital/childhood • Posterior aspect on left • Defect through pleurop-eritoneal canal • Retroperitoneal fat, spleen, kidney • BPL (Bochdalek's → Posterior and left) | <ul style="list-style-type: none"> • Adults • Anterior at Right cardio-phrenic angle • Omentum and gut • May be through esopha-geal hiatus • MAR (Morgagni → anterior and right) |

Acute Phase Diaphragmatic Rupture

Chest X-ray Normal in 1/4th cases

- Gas and fluid shadows
- Localized density in close relation to diaphragm
- Alteration in diaphragmatic shape.

Barium → Diagnostic but cannot be used in emergency

Better two create artificial pneumoperitoneum if it turns into pneumothorax suggests diaphragmatic rupture.

USG—Diagnostic if both diaphragm and herniated bowels can be seen

MDCT–Diagnostic (IOC)

- Visualization of defect
- Stomach in contact with posterior ribs (**Dependent viscera sign**)
- Thickening of crus (**Thick crus sign**)
- Constriction of stomach/bowel (**collar sign**)
- Active contrast extravasation near diaphragm on CECT studies.

1 Normally CT and MRI cannot see diaphragm in contact with spleen and liver.

HEART

Normal Heart Borders

- **Right**
 - SVC
 - Right lateral aspect of ascending aorta (old age) sometimes Right brachiocephalic trunk
 - Right atrium
 - IVC
- **Left**
 - Aortic knuckle/knob ± Left subclavian vein
 - Pulmonary conus (MPA)
 - Left atrial appendage
 - Left ventricle

1 Left atrium and right ventricles do not contribute in formation of heart borders.

Signs of Left Atrial Enlargement (Mitral Stenosis)

- Posteriorly–Indentation of esophagus (earliest) but seen only on barium/CT
- Superiorly–Elevation of Left main bronchus (earliest to be seen on radiograph)
- Splaying of carina (n ≈ 60–70°) (X-ray)
- Laterally
 - Right–double contour/double right heart border/double atrial shadow
 - Left–Prominent left atrial appendage below pulmonary conus- causes straightening of left heart border.

1 LA forms the base of Heart, opposite to apex.

1 Lateral displacement/indentation on descending thoracic aorta toward left by enlarged LA-**Bedford Sign**.

1 In some of the medicine books, straightening of left heart border is given as the earliest sign which is not described in radiology.

Right Atrial Enlargement

- Convex Right margin >3 cm from Right lateral vertebral border
- Enlargement of SVC
- ↑ **Height of Right atrium (MOST RELIABLE)**
[Top of A. arch to SVC/RA junction distance is < height of RA (Normally vice-versa)]

Left Ventricle Enlargement

- Prominent Left heart border with rounding
- **Inferolateral shift of apex**

Right Ventricle Enlargement

- Elevation of cardiac apex
- Less prominence of aortic knuckle

Unilateral Translucent/opaque Hemithorax

| Unilateral Translucent/Radiolucent Hemithorax | |
|---|---|
| Due to ↑ air | <ul style="list-style-type: none"> • Pneumothorax • Emphysema • Pneumatocele • Bullae • Macleod's syndrome (Swayer James syndrome) |
| Due to ↓ soft tissue/↓ blood | <ul style="list-style-type: none"> • Mastectomy • Poland's syndrome (absent pectoralis major) • Polio (atrophy of muscles) • Pulmonary embolism (Westermarck's sign) (due to reduced flow) (Focal oligemia) |
| Due to tilted patient | <ul style="list-style-type: none"> • Scoliosis • Positional • (most common-Rotation) |

Translucency is proportional to air and inversely to soft tissue and blood flow.

Opacity is inversely proportional to air and proportional to soft tissue, consolidation, effusion, blood flow.

Poland's syndrome → Absence/hypoplasia of pectoralis major + i/l hand and arm anomalies (syndactyly) ± p. Minor/± rib anomalies ± hypoplasia of breast and nipple.

| Unilateral Radiopaque Hemithorax | |
|----------------------------------|---|
| No Mediastinal Shift | <ul style="list-style-type: none"> • Consolidation • Small effusion • Mesotheliomas |
| Contralateral Shift | <ul style="list-style-type: none"> • Massive Pleural effusion (Figure) • Diaphragmatic hernia • Massive tumor |
| Ipsilateral shift (↓ air) | <ul style="list-style-type: none"> • Collapse • Pulmonary agenesis • Pneumonectomy • Lymphigitis carcinomatosa • Fibrothorax |

Plural Effusion

Minimum amount required to be detected on

- **Lateral view** – 75 mL
- **PA view** – 100–200 mL
- **Lateral decubitus** – < 10 mL

(best view to detect minimal effusion)

- **USG** – ≈ 1 mL (best Inv/IOC to detect minimum pleural effusion)
- when posterior and lateral CP angles are blunted—200–500 mL

Massive p. Effusion cause → C/L mediastinal shift and depression of diaphragm.

If no shift—rule out associated obstructive collapse of lung/pleural malignancy/mesothelioma/metastatic disease.

***Subpulmonic effusion**

- fluid b/w base of lung and diaphragm
- IOC → CT/USG
- On X-ray → High hemidiaphragm with lateral shift of peak contour.

***Lamellar effusion**

- Effusion between visceral pleura and lung

***Vanishing/pseudotumor**

- Loculated effusion in fissur

Lordotic View—for

- Interlobar effusion (Reverse Lordotic view)
- Middle lobe pathologies.

Bilateral Exudative Pleural Effusion

- Pulmonary embolism
- Lymphoma
- Metastasis
- RA, SLE
- Postcardiac injury syndrome
- Myxoedema

Right-sided Pleural Effusion

- Liver abscess
- Ascites
- Heart failure

Left-sided Pleural Effusion

- Pancreatitis
- Pericarditis
- Aortic dissection
- Esophageal rupture

If plural effusion is with air-shows air fluid level-
Hydropneumothorax (Figure)

On supine X-ray → veil like haziness with preserved vascular markings

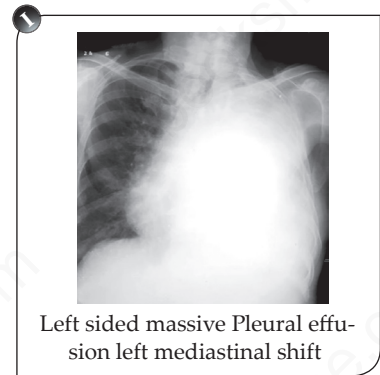
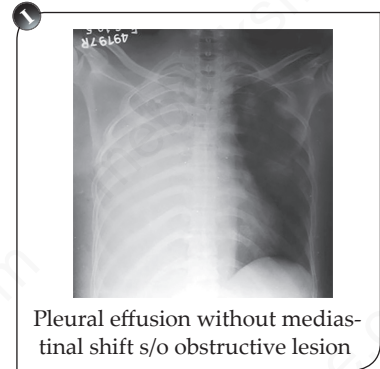
USG:

- Transudate-echo free
- Exudative-echoes (change shape with breathing) septae. Solid lesion does not change shape)

MRI:

- Limited role-Triple echo pulse sequence can differentiate exudative from transudative

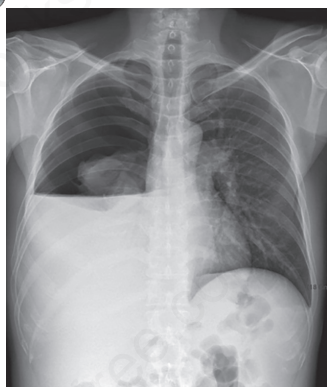Chylous effusion → high signal on T1W (normally fluid low on T1W)



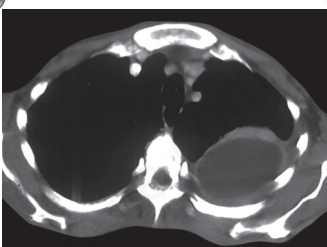
***Vanishing/pseudotumor**-loculated effusion in fissure (CHF).
***Lamellar effusion**-effusion b/w visceral pleura and lung (not between visceral and parietal pleura).

Encysted/ loculated-b/w visceral and parietal pleura.
Interlobar-b/w visceral and visceral pleura.

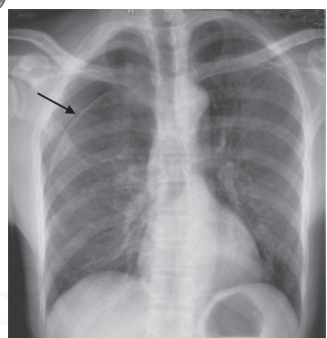
Infective effusions/empyema shows enhancing visceral and parietal pleura giving **split pleura sign**.



(R) Hydropneumothorax



Split pleura sign (empyema)



Pneumothorax with visceral pleura sign

Pneumothorax

- Best X-ray PA-Expiratory
- Best investigation-NCCT
- **USG** →
 - **Sea shore sign** on **M mode** USG suggests motion b/w visceral and parietal pleura. **Absent in Pneumothorax. (Straosphere sign)**
 - (sliding pleura sign on 'B' mode normally)
Absent in pneumothorax.

Pneumothorax-Signs on X-ray

- **Visceral pleura sign** with lung laterally devoid of vascular markings
- Ipsilateral transradiancy
- Deep finger-like costophrenic sulcus (deep sulcus sign)
- Visible anterior costophrenic recess/**double diaphragm sign**
- **Visualization of undersurface of heart-continuous diaphragm sign**
- Diaphragm depression

Tension Pneumothorax

Life-threatening condition as it causes adverse effects on gas exchange (intra-pleural pressure +ve relative to atmosphere)

Signs on X-ray

- Contralateral mediastinal shift
- Depressed diaphragm (more reliable sign) (Figure)

Pneumo-mediastinum-Signs on X-ray

- Undue clarity of mediastinal border
- Air outlining **thymus (Spinnaker sail sign)**
- Air around pulmonary artery (**ring sign**)
- Air around bronchi (**double bronchial wall sign**)

Pneumopericardium

- Gas does not go beyond pericardial reflections superiorly (aortic knuckle) and changes position with position of patient.

Pleural Thickening

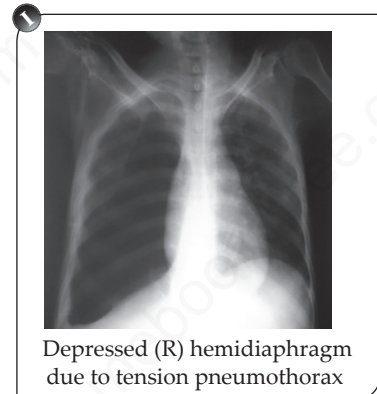
- USG-Unreliable until >1 cm (CT more sensitive)

- Fibrous pleural thickening and pancoast tumors can be indistinguishable (CT/MRI can differentiate)
- **Fibrothorax/diffuse pleural thickening**—smooth uninterrupted pleural thickening which extends over at least one quarter of chest wall or > 8.0 cm in craniocaudal direction on CT, 5.0 cm laterally and thickness > 3 mm.

1 Immediate chest tube drainage required for tension pneumothorax, which can cause **Reexpansion edema**, which progresses for 1–2 days and clears within a week.

Calcified Pleural Thickening

- Asbestosis (parietal and diaphragmatic pleura classical)
- Empyema (TB)
- Sequelae of Hemothorax (visceral pleura).



Malignant Pleural Thickening

- Mesothelioma—CT—circumferential, nodularity, parietal thickening of more than 1 cm and involvement of mediastinal pleura.

1 *MRI is better than CT for malignant mesothelioma if extension into diaphragm and chest wall suspected.

Funnel chest/Pectus excavatum → (lower ½ of sternum)

- Isolated
- Marfan's
- Heart disease (ASD)
 - Left shift of heart
 - Straightening of Left heart border
 - Prominence of main pulmonary artery segment
 - Loss of descending aortic interface
 - Increased opacity of Right cardiophrenic angle
 - Loss of clarity of Right heart border—mimicking Right middle lobe disease.
 - Steep inferior slope of anterior ribs
 - Undue clarity of the lower dorsal spine seen through the heart.

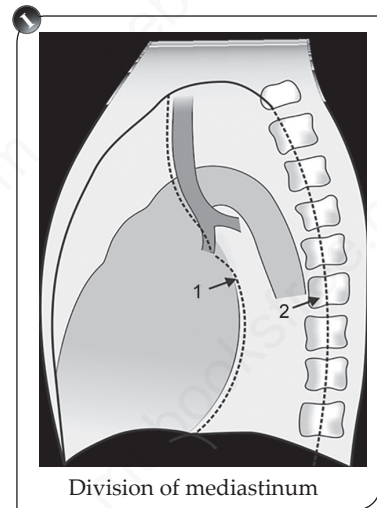
1 *Most common benign tumor of sternum – chondrosarcoma
*Pleural metastasis – most common pleural neoplasm

Pigeon Chest (Pectus Carinatum)

MEDIASTINUM

Division of Mediastinum

- Anterior (anterior to 1st line)
 - Middle (b/w 1st and 2nd line)
 - Posterior (posterior to 2nd line)
- On Lateral X-ray 1st line passing from anterior wall of trachea and then posterior surface of heart.



2nd line—Line passing 1 cm behind the anterior margin of vertebral bodies.

Anterior Mediastinal Masses

(4Ts)-Terrible tetrad

- **Thyroid**
- **Thymic:** thymomas (most common)
- **Germ cell tumors/teratomas**
- **Lymphadenopathy/Terrible lymphoma**

Middle Mediastinal Masses

(ABCDE)

- Vascular masses Aneurysm (most common)
- Bronchogenic cyst (2nd most common)
- Carcinoma bronchus
- Distant metastasis/lymph nodes
- Enteric cyst

Posterior Mediastinal Tumors

Neurogenic (most common)

Adults

- Neurogenic 17-23%
- Thymic 20-25%
- Nodal

Pediatric

- **Neuroblastoma/ganglioneuroma**
- Foregut cysts
- Germ cell tumors

MDCT → IOC for most mediastinal pathologies

MRI → IOC for

- For suspected neurogenic tumors with intraspinal extension
- Distinguishing solid mass and vessel
- Relationship with pericardium and vessels/diaphragmatic invasion

USG → Echo/endoscopic

- **Solid vs cystic diff (Most important indication)**
- Cardiac vs paracardiac mass diff
- **Guided mediastinal biopsy**

1 *Uni/biplanar fluoroscopy—1st imaging technique to guide percutaneous pleural interventions.

- 1
- Remote pleural metastasis from transpleural spread—invasive thymoma.

1 CT more useful than radionuclide studies for intrathoracic thyroid masses.

PET-CT-better for

- Lymph node metastasis
- Neuroendocrine tumors

Thymomas

- Most common tumors of thymus in adults
- CT most sensitive to detect thymoma

Features on CT

- Cyst
- Round/oval
- Punctate/curvilinear calcification
- Enhancement

Rebound thymic hyperplasia

- Poststress/Poststeroid/antineoplastic drug
- Difficult to differentiate from tumor recurrence

Germ Cell Tumor

- Mediastinum mc extragonadal site of germ cell tumors usually anterior to thymus
- Seminoma most common-malignant GCT
- Mature Teratomas are MC Mediastinal GCT-Most are Cystic
- Usually stable but hemorrhage and infection—rapid increase in size
- Fat and Ca⁺⁺ are present

Nodal Ca⁺⁺

- TB
- Fungal
- Sarcoidosis
- Amyloidosis
- **Metastasis from Pri. calcifying tumors**
 - Osteosarcoma
 - Chondrosarcoma
 - Mucinous colorectal
 - Ovarian tumor

LN calcification is rare in metastatic neoplasm otherwise.

Fat in Nodes

- Fatty replacement of inflammatory nodes
- Whipple's disease

1 **Foamy appearance** of LN in PCP in AIDS patients and metastasis from mucinous tumors.

1 **Egg Shell Calcification**

- TB
- Lymphoma after RT
- **Sarcoidosis**
- **Silicosis (most common)**
- Coccidioidomycosis
- Histoplasmosis
- Pneumoconiosis

IOC for nodes- CECT

Most common tumor of posterior mediastinum is neurogenic tumor
MRI-IOC

Posterior mediastinum is most common location of extra-abdominal neuroblastoma.

Strikingly Enhancing Nodes

- Highly Vascular Tumor Metastasis
 - Melanoma
 - Carcinoid
 - Leiomyoma/sarcoma
 - Renal
 - Thyroid
- Rarely-Castleman's disease

Investigation of choice for nodes-CECT

Foregut Duplication Cyst

- **Bronchogenic**
 - **Thin respiratory lining and cartilage** (Ca ++ - rare/displace carina anteriorly and esophagus posteriorly-like **thyroid and aberrant Left p. artery-pulmonary sling**)
- Enteric (Esophageal Duplication Cyst)
 - Can have hemorrhage/thicker walls
 - Barium: extrinsic/intramural compression
 - More intimate contact with esophagus
- Neurenteric cyst
 - Usually have a fibrous connection to intraspinal contents
 - Wall: both gastrointestinal and neural elements
 - Nearly always associated with vertebral body defects.
 - IOC-MRI

Mediastinal pseudocyst

- post. Mediastinal-CECT-IOC
- Continuity with pancreas/any peripancreatic collection

Peripheral neurogenic tumor (neurofibroma)

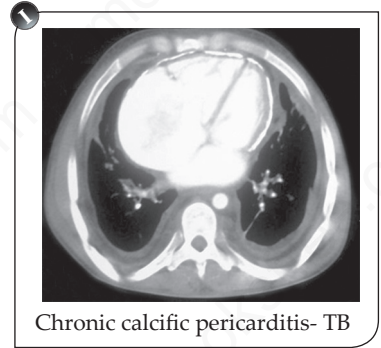
- In intercostal/paraspinal space with scalloping adjacent bones
- Punctate foci of calcification
- **Target sign on T2W images**
- **Dumb bell shape**
- Differential diagnosis- lateral meningocele

Ganglioneuroma/ganglioneuroblastoma

- Elliptical orientation vertical in paravertebral location anterolateral to 3-5 vertebral bodies.
- Homogenous intermediate signal on both T1 and T2

Parangliomas →

- Chemodectomas-most common—close to arch of aorta
- Pheochromocytomas (functional)-Post. mediastinum (Close to Left atrium or interatrial septum)
- Imaging features
 - **Rounded-very vascular**
 - Enhance intensely
 - **MRI-high signal on T2 (light bulb sign) (IOC for adrenal paraganglioma)**
 - **MIBG/somatostatin receptor scintigraphy-IOC for extraadrenal pheochromocytoma (DOPA-PET if given in the option is the best answer)**



Chronic calcific pericarditis- TB

Extramedullary Hematopoiesis

- Expansion of marrow /bone—lace like trabeculae
- Masses in paravertebral gutter of lower thorax usually. Bilateral, symmetrical, smooth.

Substernal fluid collections and dots of air are (n) in 1st 20 days following sternotomy.

Fibrosing Mediastinitis

- Infiltrative soft tissue with calcification
- IOC-CT > MRI
- MRI cannot pick calcifications (required to differentiate from lymphoma and metastasis which usually do not have Ca⁺⁺)

PERICARDIUM

USG-most common investigation for initial assessment of pericardium

Best – CT

Flask or water bottle configuration → pericardial effusion

Mach effect → abrupt change in the density b/w the lung and adjacent heart and mediastinum-pneumomediastinum.

Constrictive Pericarditis

- Predominantly anterior to RV
- ≥ 4 mm → MRI ≈ CT but CT is better for calcific pericarditis. (ECHO – most sensitive)
- ECHO and clinical details: IOC for diagnosis of cardiac tamponade
- CT and MRI: IOC for the diagnosis of cause of cardiac tamponade

Malignant mesothelioma is most common primary pericardial neoplasm

Finding a (N) pericardium excludes a diagnosis of constrictive pericarditis. However, finding of thickened pericardium does not necessarily imply presence of constriction.

Metastatic melanoma to pericardium neoplasm, Hyper on T1 and hypo on T2W.

Echo-initial IOC MRI → IOC

Hypertrophic Cardiomyopathy (HOCM)

Echocardiography

- Asymmetric septal hypertrophy
- Banana-like left ventricular cavity
- Abnormal systolic anterior motion (SAM) of mitral valve

Causes of Massive Cardiomegaly

- Multiple valvular disease
- Dilated cardiomyopathy
- Pericardial effusion
- Ebstein's anomaly
- ASD

Small Heart

- Normal
- Emphysema
- Addison's disease
- Malnutrition (PEM)
- Constrictive pericarditis

Cardiothoracic Ratio

- Largest transverse diameter of heart/widest internal diameter of thorax

Cardiomegaly if

- Ratio >50% (adults)
- >60% (infants)

LUNG PARENCHYMAL PATHOLOGIES

Consolidation → air space/alveoli opacification with obliteration of vascular markings

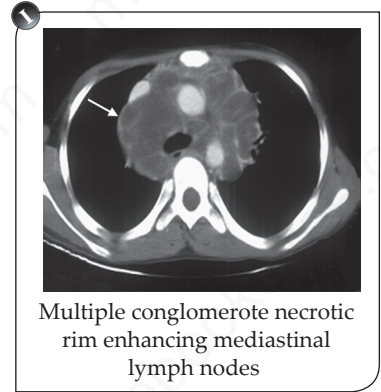
- **Depending upon contents consolidations can be**
 - *Infective exudates* → Pneumonia
 - Fluid-pulmonary edema
 - Blood → contusion
 - Tumor cells → malignancy
 - Pus cells → abscess

Ground glass opacification → If air space opacifies, without obliteration of vessels (Active and reversible stage of disease- alveolitis)

- Initial stages of
 - pneumonia
 - ILDs
 - PCP

Primary TB

- Homogenous opacity mimics community acquired (Multifocal involvement and cavitation) rare
- Lymphadenopathy is hallmark with or without pneumonia (Ipsilateral hilar and mediastinal) (also in TB with AIDS)
- Cavitation-Progressive pri and sec. TB
- Nodal pressure and erosion can cause segmental collapse (ante. Seg. of RUL and middle lobe)
- Bronchial perforation → Endobronchial spread → Tree in bud (like broncho-pneumonia)
- Hematogenous spread – miliary TB (uncommon in primary TB)



*Pleural effusion is also common in children
 *Peripherally enhancing conglomerate-Necrotic lymph nodes on CT

Pri TB-Focus → Ghon focus/lesion (commonly subpleural perifissural)

Usually resolves completely but 1/3rd cases may have well-defined rounded or irregular/linear with or without calcification (Ghon focus).

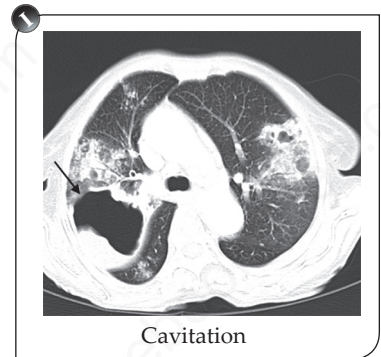
Postprimary TB (PPT)

Either due to previous infection or due to BCG vaccination hypersensitivity to tubercular proteins

Greater inflammatory reaction and caseous necrosis most common sites → Apicoposterior of upper and superior segments of lower lobes. (Poorly margined nodular and linear opacities)

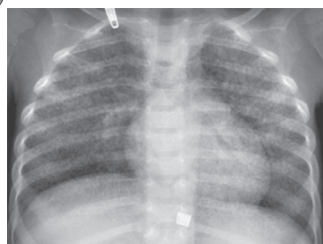
Features

- Cavitation: Rasmussen aneurysm-Rare life-threatening complication of cavitary tuberculosis caused by granulomatous weakening of pulmonary arterial wall
- Endobronchial spread → Tree in bud (Figure)
 Tree in bud also seen in
 - Bronchiolitis
 - PCP (AIDS)

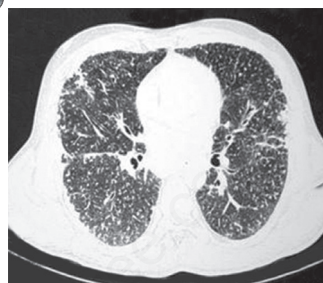

(Ghon focus) + calcified nodes (I/L) ± draining lymphatic = **Reinke's complex** (s/o prior-pri. TB)

*Isolated involvement of anterior segment (except in contiguous spread) excludes the diagnosis of tuberculosis.



Miliary shadow of TB



Miliary shadows on CT

- **TB (most common)**
- Pseudomonas aeruginosa
- **P. effusion** → more likely empyema
- **Miliary pattern**-Hematogenous spread (more common than Pri)
- **Healing by fibrosis** → Nodular linear fibrosis, volume loss, bronchiectasis, cyst, bullae, lung distortion.

*Hemoptysis → First vessel to be studied however in bronchial artery

Miliary shadows

- More typical of progressive pri in older
- Multiple small (2 to 2 mm) discrete nodules scattered randomly and evenly throughout both the lungs
- Usually do not reach beyond 5 mm size (death) –
- Usually seen in
 - TB,
 - Sarcoidosis,
 - Pneumoconiosis,
 - Silicosis,
 - Metastasis,
 - Chickenpox (Ca⁺⁺),
 - Histoplasmosis,
 - Hemosiderosis (MS),
 - Oil embolism,
 - Alveolar microlithitisis (sand-like calculi in alveoli-familial).

Tuberculomas (Pri/post pri)

- Localized parenchymal disease that alternatively activates and heals show → satellite lesions and **calcifications (features of benign disease)**
- IOC-CECT for both Pri and Post Pri

Activity/Features

- Ill-defined coalescing nodules
- Poorly marginated linear opacities
- Cavitory disease.

D/d of Cavitory Lesion on Chest X-Ray

- Wegener's granulomatosis
- Septic emboli

- Infections-TB, anaerobes, pneumocystis/staph. (pneumatoceles)
- RA
- LCH
- LAM
- Sarcoid
- Metastatic/malignant
- Developmental (sequestration)

Nontubercular mycobacteria-M. kansasii → like post. pri.

Mycobacterium avium complex → Multiple nodules with bronchiectasis in lingula and middle lobes Right

*P. effusion and nodes are (Rare)

Other Infections

Alveolar (lobar) or Interstitial (bronchopneumonia) pattern

- **Lobar pneumonia**
 - Unifocal, distal air space near visceral pleura,
 - Spread via col-lateral air drift (homogenous)
 - As airways are patent → (air-bronchogram) → Little to no volume loss
- Bronchopneumonia
 - Causes multifocal, distal airway,
 - e.g. atypical pneumonia/viral → Reticular/reticulonodular (mycoplasma pneumonia)

Other Causes of Air Bronchogram (arrow in Figure)

- Pneumonic consolidation (contusion)
- Pulmonary edema
- Hyaline membrane disease (HMD)
- ARDS
- Bronchioalveolar carcinoma
- Round pneumonia (in children due to collateral spread via canals of Lambert)

Bulging Fissure Sign

- Klebsiella pneumonia (due to very exudative response)
- Lung abscess and tumor (due to direct mass effect)

Lobar Collapse

Causes increased opacity of lung and features of volume loss.

Tree in bud appearance after bone marrow transplant

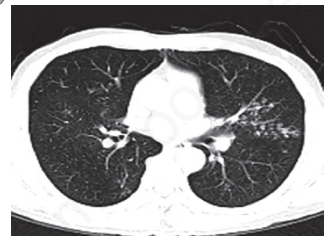Early (< 1 month)

- Aerobic bact
- Candida
- HSV

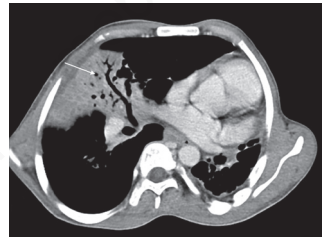
Middle (1-4 months)

- CMV
- RSV

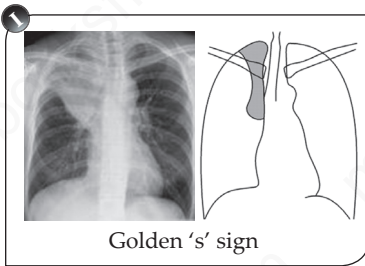
Late (> 6 months)
PCP



Endobronchial spread tree in bud



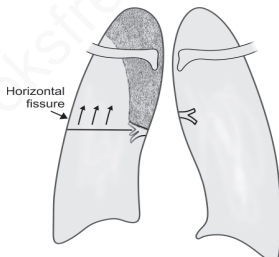
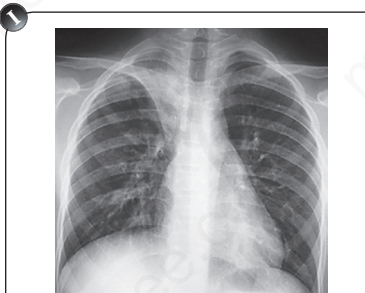
Golden 'S' sign → central mass compressing bronchus with collapse distal lung with inferior bulge of medial horizontal fissure due to mass and superior bulge/convexity of lateral fissure due to collapse.



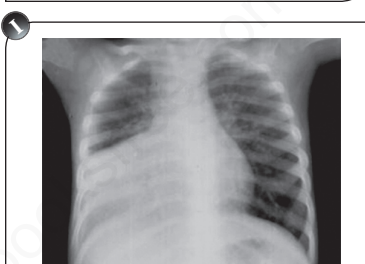
Golden 's' sign

CECT is IOC for both collapse and consolidation.

Collapse shows relative homogenous enhancement unlike pneumonia (due to crowding of vessels and obliteration of airspace).



Right upper lobe collapse



Middle lobe consolidation silhouetting the right heart border

Direct Signs of Collapse

- Displacement of interlobar fissure, P. vessels and bronchi (Most Reliable)
- Hilar elevation upper lobe collapse
- Depression → Lower lobe collapse

Indirect Signs

- Compensatory shift-hyperinflation of other lobes
- Crowding of ribs
- Mediastinal shift

Other Indirect Signs

- Shifting granula sign
- **Luftsichel sign (air crescent)** → overinflation of superior segment of Ipsilateral lower lobe with paramediastinal translucency
- Displacement of anterior junctional line
- Divergent or parallel pattern of vessels in upper lobe collapse
- Tracheal shift
- Diaphragm shift

*Least mediastinal shift with → Middle lobe collapse

*Maximum mediastinal shift with → Lower lobe collapse

Silhouette Sign

- Given by Felson
- When there is density/collapse/consolidation in lung, it obliterates that part of SVC/aorta/heart/diaphragm, which is in direct anatomical contact. e.g. Middle lobe → Right heart border, lingular Left heart border basal lung → diaphragm

| Silhouette structure | Contact with lung |
|---|-----------------------------------|
| Upper right heart border/ ascending aorta | Anterior segment of RUL |
| Right heart border | RML (medial) |
| Left heart border | Lingua (anterior) |
| Aortic knob | Apical portion of LUL (posterior) |
| Anterior hemidiaphragms | Lower lobes (anterior) |

Middle lobe syndrome → Collapsed Right middle lobe with bronchiectasis due to focal bronchostenosis secondary to pulmonary TB.

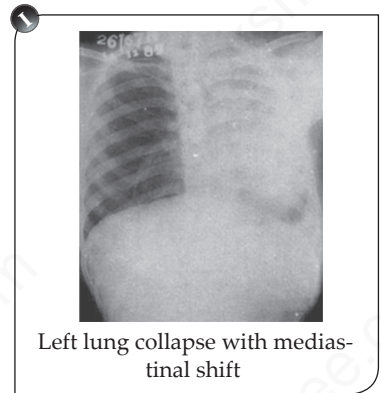
Superior triangular sign → Triangular density to Right of mediastinum in Right lower lobe collapse due to displacement of junctional line.

Flat waist sign → Extensive collapse of Left lower lobe (flattening of aortic and pulmonary knuckle due to rotation of heart and shift)

Staph → Pneumatocele (Figure) and septic emboli in drug addicts

PCP → Pneumatocele/tree in bud in AIDS/GGO/ no lymphadenopathy or effusion perihilar opacification

Pseudomonas A. → Tree in bud/GGO



Left lung collapse with mediastinal shift

Anaerobic Infections

- Due to aspiration in ventilated patients
- **Apicoposterior of upper lobe**
- **Superior/posterior basal of lower lobes.**

Histoplasmosis

- Nodule with central calcification → **Target lesion (specific)**

Coccidioidomycosis

- Miliary nodules.

North American Blastomycosis

- Mimics-Progressive pri TB → fibrocavitary

Aspergillus

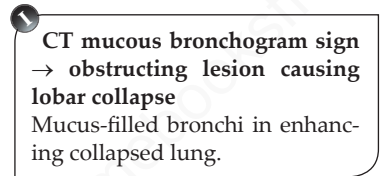
Aspergilloma → air crescent around a freely mobile ball in a cavity (most common-old TB cavities) (Figure)

D/d of Air Crescent

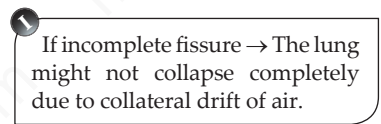
- Aspergilloma/fungal ball
- Inspissated pus in a cavity
- Tumor in a cavity
- Hematoma in old cavity due to bleed
- Hydatid cyst

ABPA (Allergic Bronchopulmonary Aspergillosis)

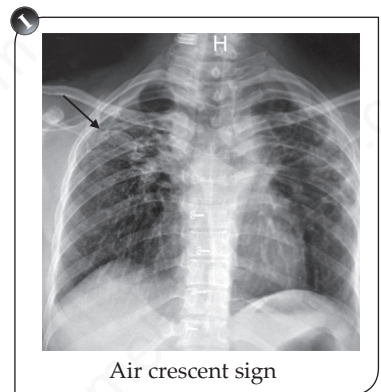
- Branching thick tubular opacities
- Bronchiectasis (central)
- Finger in glove (due to mucous impaction)
- Type-III immune reaction



CT mucous bronchogram sign → **obstructing lesion causing lobar collapse**
Mucus-filled bronchi in enhancing collapsed lung.



If incomplete fissure → The lung might not collapse completely due to collateral drift of air.



Air crescent sign

Chronic Necrotizing (semi-invasive) → Like TB Invasive (Immunocompromised)

- One or more poorly marginated homogenous areas
- Cavities
- Wedge-shaped infarct
- Miliary nodules

IOC-CECT-Ground glass halo around nodules (hemorrhage)

HRCT → angioinvasive nature with occluded vessels

Atoll/Reverse halo sign → Cryptogenic organizing pneumonia.

(Ring shadow of consolidation around GGO)

Hydatid Cyst of Lung

CX R

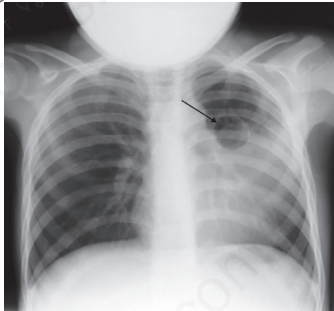
- Homogenous Roughly Spherical/Oval
- Sharply demarcated
- No/Rarely calcify (as no stable nidus due to breathing)
- Air crescent [(If pericyst Ruptures-Due to fibrous host Reaction (Not a true membrane))]
- Complex Rupture (Rupture of cyst walls endo/ectocyst)

CT- IOC

- Air fluid level (floating membranes/water lily/camalote sign (Figure))
- Double wall
- Dry cyst with crumpled membranes (Rising sun sign)
- Empty cyst (If contents expectorated out if communication with bronchus)
- Air bubble sign (perforated hydatid)

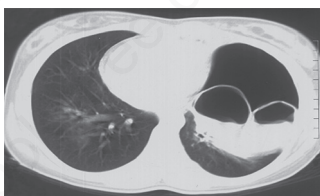
Pulmonary Complications of HIV and AIDS Infections

- PCP
- TB
- Cryptococcus
- Kaposi sarcoma
- LIP (lymphocytic interstitial pneumonia)
- CMV



Pneumatocele in staph infection

If collapse of both (R) middle and lower lobe S/o → obstruction of bronchus in- termedius.



Water-lily/Camalote sign

Pneumocystis Jirovecii Pneumonia

CXR

- Bilateral Reticular opacities and GGOs
- Miliary
- Cavitory nodules
- **P. Eff./L.N. rare**
- **Pneumatoceles/Pneumothorax**
- Bronchopleural fistulas

*Pentamidine aerosol causing increased frequency in upper lobes

IOC-CT → Unilateral/Bilateral-GGO or homogenous opacities in geographical distribution

Cryptococcus Neoformans

- Diffuse reticular opacities
- **P. Effusion** Contrary to PCP
- **Lymphadenopathy** Contrary to PCP
- Cavitation

Kaposi sarcoma

- Coarse linear opacities in perihilar region, pleural/pericardial effusion, mediastinal lymphadenopathy (most common AIDS associated malignancy).

CMV

- Most common cause of pneumonia in renal transplant
- **Most common cause of chorioretinitis in AIDS.**

AIRWAY

Post-tracheostomy Stenosis

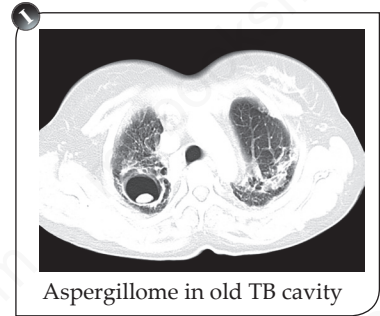
- Typically begins at 1–1.5 cm distal to the inferior margin of tracheostomy stoma.

Relapsing Polychondritis

- Posterior wall of trachea in early stage but involved in later stages.
- Flaccid which collapses on expiration.

Tracheobronchopathia Osteochondroplastica

- Multiple cartilaginous nodules and bony submucosal nodules on inner surface of trachea.



Aspergillome in old TB cavity

ABPA → most common acute changes → transient consolidation mucoid impaction and atelectasis
Permanent → bronchiectasis

Sabre Sheath Trachea (Reduced coronal diameter)

- Diffuse narrowing (COPD)
- Intrathoracic trachea narrowing with abrupt normal caliber at thoracic inlet

Tracheobronchomegaly (Mounier-Kuhn disease)

- Marked dilatation of trachea and main branch
- Tracheal diverticulosis

Tracheobronchomalacia (weakened cartilage)

- Radiographs → with almost 300% reduction in **AP diam on exp.** on CT- narrowing of > 50% on exp.
- Coronal diameter '↑' → lunate configuration-lunate/crescentic → due to bowing of postmembranous trachea.

Bronchiectasis

CxR-thickened bronchial walls

- Parallel → tramlines or tramtract
- End on → signet ring/oval opacity
- Cystic bronchiectasis → multiple thin-walls ring shadows → bunch of grapes [Figure]

HRCT Findings of Bronchiectasis

- Dilatation of bronchi
- With or without bronchial wall thickening
- Lack of tapering of bronchial lumen (cardinal sign)
- Internal diameter greater than adjacent p. artery (signet ring sign)
- Visualization of bronchus within 1 cm of costal pleura
- Abutting mediastinal pleura
- Mucus filled dilated bronchi

Varicose bronchiectasis → beaded appearance → (string of beads)

- Mucus-filled lobulate 'V' or 'Y'-shaped densities → glove finger
- End on-homogenous nodular opacities adjacent to vessels
- Infectious bronchiolitis → **tree in bud** (linear branching)

Bilateral Upper Lobe → cystic fibrosis and ABPA severity
→cystic > varicoid > cylindrical
Unilateral-UL → TB
Lower lobes → viral infections (childhood)

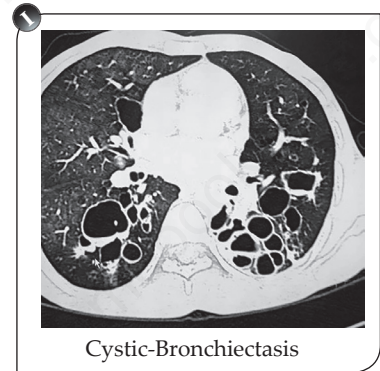
*****IOC → MDCT with thin collimations > HRCT misses within interval of slices**

Broncholithiasis CxR

- Disappearance of previously identified calcified nidus.
- Change in position of a calcified nidus.
CT and fiberoptic bronchoscopy—evidence of airway obstruction, atelectasis, mucoid impaction, obstructive pneumonitis.

Emphysema

- **Barrel-shaped kyphotic chest**
- Increased intercostal space
- Tubular Heart-
- **Imaging feature**
 - **Overinflation (best predictors of severity)**
 - **Height of Right lung > 29.9 cm**
 - Location of Right hemidiaphragm at or below 7th rib anteriorly
 - Flattening of diaphragm (**Terrace pattern**)
 - Enlargement of retrosternal space
 - Widening of sternodiaphragmatic angle
 - **Narrowing of transverse cardiac diameter**
 - Reduced vessels in affected lung.
- Large progressive upper lobe bullae occupy significant vol. of hemithorax
- CT-IOC
- Four types
 - Paraseptal
 - Centrilobular
 - Panacinar/panlobular
 - Irregular/paracicatricial



1 Giant bullous emphysema/
vanishing lung syndrome/
pri. bullous disease

Assessment of Air-Trapping by

- **Expiratory MDCT/HRCT** → in obliterative bronchitis
- Texture analysis technique
- CT densitometer by calculating Pixel Index (objective)

1 Central (sq cc/small cc)
peripheral (adenocarcinoma)

1 Bulky mediastinal adenopathy
and fastest rate of growth—Small
cell carcinoma

Lung Malignancy (WHO)

- Sq. c ca
- Adenocarcinoma
- Small cell ca
- Large cell ca

1 Squamous cell carcinoma →
More likely to cavitate

Bullae > 1 cm thin but perceptible wall
cyst → imperceptible wall

- Density mask technique by CT → for emphysema
- **Expiratory HRCT is superior to inspiratory**
- Increased lung markings → 'dirty chest' → bronchitis (loss of clarity of lung vessels)

Diagnosis of chest wall extension is unreliable on CT even if mild-thickened pleura

- Local chest wall pain remains the single-most specific indicator of whether or not the tumor has spread to the parietal pleura or chest wall
- On CT → only if bone destruction or large soft tissue.

Benign

- Uniform cavitation
- Smooth margin/sharply defined
- **Central/lamellated Ca⁺⁺**
- **Popcorn Ca⁺⁺ hamartoma (fat)**
- **Very long doubling time**
- No enhancement in soft tissue nodule
- Pleural tail

Malignant Nodules

- Doubling time 1–18 months
- Amorphous cloud like dystrophic/eccentric/stippled calcification (metastasis from cartilage or bone forming tumors)
- Umbilicated border
- Thick irregular inner wall of cavity (SCC-most common)
- Lobulated spiculated margins
- Sub solid nodules- GGO nodules/partly solid and GGO
- Corona radiate-highly suggestive but nonspecific (fibrotic nodules) (Figure)

CECT-IOC

PET:

- Indeterminate nodule/staging
- **False negative in**
 - <1 cm
 - Carcinoid
 - Low-grade adenocarcinoma.

Bronchial carcinoids (central)

- **May calcify or ossify**
- Often large tumor outside bronchus (iceberg lesions)
- **Chest radiography would remain the initial investigation in all patients suspected of lung cancer.**
- **Staging IOC-CECT**
- **MRI**
 - **For superior sulcus tumor/brachial plexus**
 - Diaphragmatic integrity and thoracic/chest wall invasion
 - Hilar lymphadenopathy (Fe₂O₃) (superoxide/iron contrast very specific)

But because of MDCT routine MRI not required for these except in few cases.

Signs of Mediastinal invasion on C×R

- If phrenic nerve involvement-elevated hemidiaphragm
- Collapsed lung
- Subpulmonic effusion

There is very high likelihood of respectability even if tumor had crossed into mediastinum and showing following features on CT

- < 3 cm of contact with mediastinum
- < 90° of circumferential contact with aorta
- Visible mediastinal fat plane

Most tumor conforming to this description had no mediastinal invasion at surgery

PET-CT → now investigation of choice for distant spread (but outside the CNS)

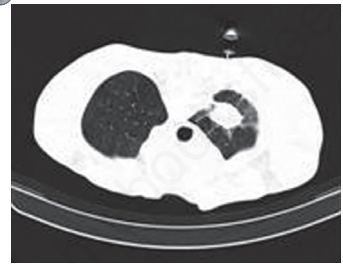
Cavitating Metastasis

- Sq cc Head and Neck
- Ca cervix
- osteosarcoma
- TCC
- RCC (rare)

Solitary Metastasis

- Colon
- Kidney
- Breast
- Testicular tumors
- Bone sarcomas
- Malignant melanoma

1 Size—most benign nodule < 2 cm
Subpleural-lymphoid Straight/
concave margin-benign.



Malignant nodules showing corona Radiata appearance

1 **Black bronchus sign** (seen in GGO)—more black air in bronchus than lobule which is usually more in secondary lobule.

INTERSTITIAL LUNG DISEASE

ILD Interstitial shadows

Fine inter-/intra-lobular septal thickening/GGO

Coarse → Reticular

- IPF → mediastinal lymphadenopathy
- **Sarcoidosis** → **Hilar and mediastinal nodes** > skin > peripheral nodes > eyes > spleen > central nervous system > parotid > **bones (least)**

Stage-I → only L.N. (lambda sign/ panda sign)

II → L.N. + lung parenchyma

III → only lung parenchyma

IV → pulmonary fibrotic nodules-irreversible

Bilateral symmetrical → as evenly distributed throughout mediastinal and hilar

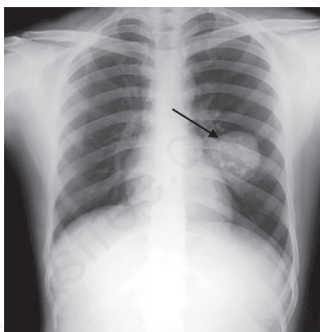
Nodular sarcoidosis → galaxy sign → confluent nodules

if very small nodules below resolution of HRCT → GGO (alveolar sarcoidosis)

Parenchymal consolidation and GGO → Reversible

while reticulation and architectural distortion → nonreversible

- **RA** → Intrathoracic manifestations
 - Pleural effusion (most common)
 - UIP-pattern ILD
 - Constrictive obliterative bronchiolitis
 - Bronchiectasis
 - Organizing pneumonia
 - Follicular bronchiolitis
 - **Necrobiotic nodules (uncommon)**
 - May cause pneumothorax
 - **FDG-uptake**
- **SLE**
 - Pleuritis → with pain → P. effusion (most common)
 - Diaphragmatic dysfunction (shrinking lung syndrome) → ↓ Lung vol
 - Restricted diaphragmatic movement → band atelectasis
- **SJS**
 - Most common lung manifestation is NSIP
- **Asbestosis (Predilection for lower lobes)**
 - Parietal pleural plaque (most common) (does not cause significant impairment of lung function)
 - Diaphragmatic
 - Paravertebral (most common to get miss on CxR)
 - Spares → apices, CP angles and visceral pleura
 - Pleural calcification - Round atelectasis (Pseudotumor)
 - Round-Atelectasis/**Crow's feet sign/Vacuum cleaner sign**/Swiss cheese air bronchogram/**Folded Lung/comet tail sign**: crowding of bronchi and blood vessels that extend



Popcorn calcification in a nodule- pulmonary hamartoma

from border of mass till hilum) Strong and homogenous enhancement after i/v inj of contrast (indicative of atelectasis rather than neoplasm)

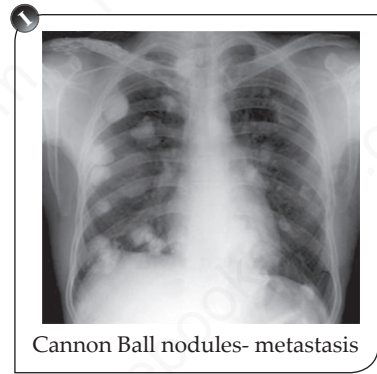
*Pneumothorax → seen with metastasis from osteosarcoma

Upper Lobe Involvement (BREAST)

- Beryllium (Barytosis)
- Radiation
- Extrinsic allergic alveolitis
- AS
- Silicosis/Sarcoidosis
- TB

Lower Lobe Involvement (FAIL)

- Fibrosing alveolitis
- Asbestosis
- Idiopathic pulmonary fibrosis
- Lymphangiomyomatosis



Cannon Ball nodules- metastasis

ACUTE THORACIC CONDITIONS

Pulmonary Embolism

CXR- Normal in 30% →

- Westermark's sign (area of focal peripheral oligemia) (most specific)
- **Knuckle sign/Palla's sign** → enlarged Right descending pulmonary artery
- **Hampton's hump**-peripheral wedge-shaped opacity with convexity toward hilum
- **Melting sign** → infarcts show rapid clearing contrary to pneumonic consolidation
- **Fleischner's lines** → long curvilinear densities reaching pleural surface

Fleischner's sign → elevated hemidiaphragm

Felson's sign-pleural effusion L > R

- Initial Screening-D-Dimers
- IOC → CECT > V/Q scanning
- Gold standard → Pulmonary angiography/arteriogram (most specific) However, CT pulmonary angiography has virtually replaced the invasive angiography-hence IOC

CTPA-Signs of RV Strain

- Dilatation of RV
- Left shift of -septum
- Reflux in IVC
- Enlarged central P. artery

Ventilation Agents

- Xe-133

TB → only draining nodes involved → asymmetrical

Nodal enlargement does not appear after parenchymal opacities have developed in sarcoid.

While in lymphoma-both progress in unison.

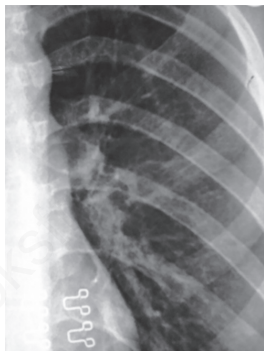
Honey combing

Histiocytosis
Sarcoidosis
Scleroderma
Pneumoconiosis
RA
UIP
Fibrosing alveolitis

Upper lobe venous diversion (MS/Pulmonary venous hypertension) → **Stag-antler's sign**
Reverse moustache sign
Cephalization of pulmonary veins

T/t → Pulmonary edema in 1st 3 days of treatment resolution with diuretic (leads to worsening of C × R in 1st 3 days).

- P edema: Very rapid change in opacity (clearing) (fastest) (in a matter of hours)
- IInd fastest to get clear → P. hemorrhage (few days).



Stage 1 pulmonary edema
Cephalization

- Kr-81
- Technegoc

Perfusion

- Tc99MAA (macroaggregates of albumin)
V/P mismatch - sign of emboli

Reverse mismatch → COPD (abnormal ventilation)
V/Q scanning (IInd line) when one cannot tolerate i/v contrast

- **CEMRI-Excellent for diagnosis of DVT (MR venography)**
- Can detect large proximal PE but unreliable for smaller segmental PE
- **D-dimer → High negative predictive value to exclude PTE**

Pulmonary Edema: (Excess of extravascular lung water)

- **Cardiogenic**-(due to ↑ hydrostatic pressure LVF, MS, atrial myxoma)
- **Noncardiogenic** (↑ vascular permeability)
 - Volume overload due to renal failure
 - Increased capillary permeability

Stages

***Earliest is equalization of vessels (13–15 mm Hg)**

- **16–19 mm Hg → upper lobe diversion of blood (cephalization)/reverse moustache sign**
- **20–24 mm Hg → interstitial peribronchial cuffing edema/pleural effusion/kerly lines**
- **> 25 mm Hg (acute) alveolar edema → perihilar fluffy opacities (Bat wing on X-ray or white out)**
- **> 30–35 (in chronic phase) (due to thickening of lymphatics/connective tissue)**
 - Kerley A → Thickened deep interlobular septae (2–6 cm long) from hilum (nonbranching)**
 - Kerley B → Nonbranching transverse (1–3 cm) perpendicular to pleura**
 - Thick interlobular septae Kerley-KerlyC → Spider web appearance**

Causes

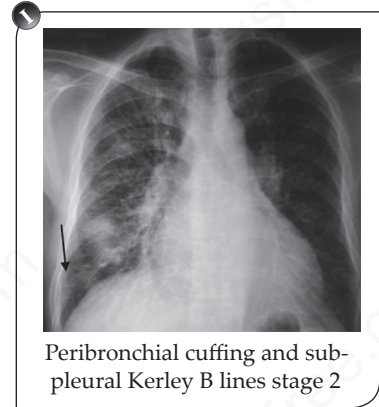
- LVF
- MS

- Pneumoconiosis
- Lymphagitic carcinomatosis
- Interstitial fibrosis, sarcoidosis, alveolar cell carcinoma, lymphoma, lymphatic obstruction, lymphangiectasia, lymphangiomyomatosis

Causes of ARDS

- Trauma, septicemia, shock, fat embolism, burns, pancreatitis near drowning, Mendelson’s syndrome, oxygen toxicity.

| Cardiogenic (LVF) | Noncardiogenic (ARDS) |
|---|--|
| <ul style="list-style-type: none"> • Central • Upper lobe veins prominent • Cardiomegaly • Enlarged mediastinal nodes • ↑ attenuation of mediastinal fat | <ul style="list-style-type: none"> • Peripheral • Nearly symmetrical • Heart usually Normal |



Pneumomediastinum

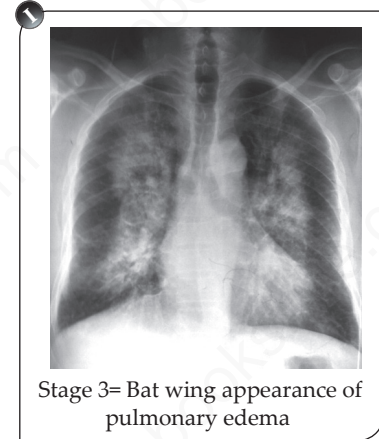
- Air around pulmonary artery → Ring shadow
- Along bronchi → double bronchial wall sign
- Over diaphragmatic surface → continuous diaphragm sign.

Pneumothorax

- USG has been shown to be more sensitive than radiography and as sensitive as CT assuming the expertise is available.

Pneumopericardium

- Outlining of superior pericardial reflection around the great vessels with air and visualization of main pulmonary artery.



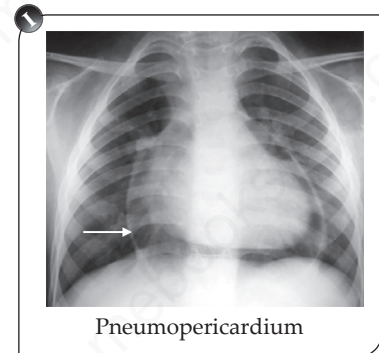
Pulmonary Arterial Hypertension (PAH)

Mean pulmonary arterial pressure

- > 30 mm Hg during exercise
- > 25 mm Hg at rest in systole

Vascular Signs

- Enlargement of central and segmental pulmonary arteries and tapering of peripheral arteries (**peripheral pruning**)
- Diameter ratio of MPA/ascending aorta > 1
- Max. diameter of descending branch of pulmonary artery (1 cm medial and 1 cm lateral to hilar point) > 16 mm (M), > 15 (F)



- **Disproportionately small peripheral arteries**
- Subplural pulmonary infarct
- Calcified plaques of central p. arteries (**pathognomonic**)

Mediastinal and Cardinal Signs

- Cardiac enlargement right sided with hypertrophy
- Dilatation of IVC, SVC, and coronary sinus
- Mosaic perfusion without dilatation of bronchi

Pulmonary Venous Hypertension (PVH)

- LVF, MS, Left atrial myxoma
- **Long-standing PVH** → Fine miliary calcification or fine nodular pattern scattered throughout lung (**pulmonary hemosiderosis**)
- **Severe long-standing PVH** → (**pulmonary ossicles**)
- Opacification pattern
 - Perihilar bat-wing
 - Right upper zone alveolar edema in severe MR.

Trauma

FAST → focussed assessment with sonography for trauma.

Stable-fast helical MDCT is the most useful imaging investigation.

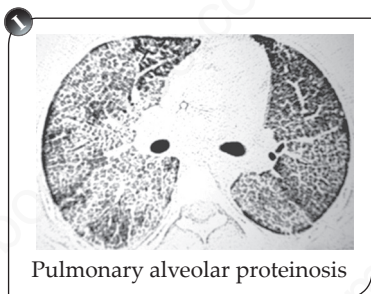
Two-phase intravenous contrast-enhanced single CT data acquisition-from skull base to mid-femur-dilute contrast in portovenous phase and then high concentration contrast agent injected later, providing arteriographic image in the same examination.

For metallic beam-hardening artefacts

- High Kv CT
- Alternating the angle of acquisition (either by gantry or position of patient)

Majority of acute traumatic aortic injury (ATAI)

- At aortic isthmus (2.0 cm distal to origin of Left SCA)
- Aortic root (5%)
- **Osseous Pinch**→Thoracic spine and sternoclavicular junction
- **Water hammer effect**→ Increased intravascular pressure within aorta



Mediastinal Hematoma

- Mediastinal widening ($> 25\%$ of chest width)
- Blurring of margins of the aortic arch
- Loss of definition of aortopulmonary window

Indirect

- Deviation of trachea and NG tube
- Widening of paratracheal stripe

Direct

- Intimal Flap
- Pseudoaneurysm
- Pseudocoarctation (sudden change in caliber)
- Contained ruptures



Photographic negative of pulmonary edema.

Patchy opacities are peripheral and seen parallel to chest wall in chronic eosinophilic pneumonia.

Tracheobronchial Injury →

- Pneumothorax persistent to treatment by chest drain
- **Fallen lung sign** (parenchyma in dependent part)

Esophagus → Mostly Iatrogenic Injury

- **Pneumothorax on supine film**
 - Deep costophrenic sulcus
 - Hyperlucency over the hemidiaphragm
 - Well-defined mediastinal or cardiac border
- **Sucking chest wound**
 - Wound with flutter valve
 - unilateral air flow
 - pneumothorax resistant to treatment

Lung injury

- Most common-parenchymal injury is → contusion
- **Delay of 6 hours for it to be visible on X-ray immediate on CT**
- Blast lung (survivors of near proximity explosive)
 - Bilateral diffuse pulmonary infiltrates in butterfly pattern on CxR
- Multiple fractures in '3' contiguous ribs-flail chest
- Injury to upper '3' ribs-most dangerous due to involvement of
 - Brachial plexus
 - Sub clavian vessel
 - Trachea
 - spine

Dia Phragmatic Injury

- Hour glass/collar sign → on CT in case of diaphragmatic rupture
- Dependent viscera sign → due to lack of support from torn diaphragm

RADIOLOGICAL APPROACH

Chest

Investigations

| | | |
|-------------|---|--|
| Chest X-ray | – | Initial/first investigation to be done for common symptoms like cough, pain, dyspnea |
| CT | – | IOC for most chest and mediastinal pathologies |
| HRCT | – | IOC for ILD/bronchiectasis/Miliary nodules |
| USG | – | Very sensitive to detect noninvasively a small (pregnant/child) pleural effusion |
| MRI | – | IOC for pancoast tumor/neurenteric cyst |
| PET | – | IOC for nodal metastasis/myocardial viability |
| Angiography | – | Gold standard for pulmonary embolism |

Additional views

Lateral decubitus view

- Recommended by American Thoracic Society guidelines for all patients presenting with community-acquired pneumonia (if thickness of effusion < 1 cm, it does not require intervention)
- To check movement of fluid

Expiratory film

- To demonstrate small pneumothorax and obstruction of airflow in FB inhalation

CT Reformat Techniques

| | | |
|---|---|-----------------------------------|
| Multiplanar and curved multiplanar reconstruction | – | Airway and PE |
| MIP (max intensity projection) | – | vascular and micronodular disease |

- Min IP – Air trapping/emphysema
- Shaded surface display – Airway abnormalities
- Volume rendering – Angiographic examination/
large airway abnormalities
- Virtual bronchoscopy – For endoluminal pathology

USG

- Guided Aspiration in ICU
- Real time diaphragmatic paralysis
- Absence of sliding pleura sign in pneumothorax
- Absence of echogenic line when infiltrated by tumor
- Transesophageal EUS-for staging of mediastinal node.

MRI

- Heart and Great Vessels
- PE if radiation and contrast to be avoided
- Cystic nature of mediastinal lesions (non-serus fluid solid on CT).

PET

- False (-ve)
 - < 1 cm lesion
 - Carcinoid
 - Broncho alveolar carcinoma (BAC)

Multicystic Air-Filled/Radiopaque (Intrathoracic Lesions)

A. Respiratory distress with Contralateral mediastinal shift

- *Congenital lobar emphysema (CLE)*
 - Most commonly found in infants and presents with progressive respiratory distress + progressive cyanosis within first 6 months of life.
 - Associated with VSD, TOF, PDA
 - Left upper lobe > Right middle lobe > Right upper lobe whole lung usually not involved
 - CxR → Initially radiopaque → then air-trapping and hyperlucent expanded lobe (after clearing of fluid)
- *Congenital cystic adenomatoid malformation (CCAM)*

- Communicating with bronchi and Normal pulmonary vascular supply (unlike sequestration)
- CxR- Contralateral mediastinal shift by radiopaque/cystic mass
- Congenital diaphragmatic hernia
 - Bochdalek
 - Morgagni
 - Eventration of diaphragm

B. No Respiratory Distress and No Mediastinal Shift

- Esophageal duplication cyst
- Bronchogenic (lung) cyst (do not communicate with tracheobronchial tree-most common intrathoracic foregut cyst)
- Bronchopulmonary sequestration
- Pneumatocele formation

Esophageal Markings on Barium Column

Normal

- Aortic arch and main bronchus
- Impression by LA in front
- At entry into diaphragm

Abnormal

- Right-sided aortic arch indents the esophagus on Right
- Coarctation of aorta → **Reverse '3' sign** (due to pre- and poststenotic dilatations)
- *Aneurysms of aortic arch and descending aorta (dysphagia aortica → dysphagia in old due to unfolding of aorta)
- ***Aberrant Right subclavian A** → **Indentation on posterior wall (Dysphagia lusoria)**
- **LA/LV enlargement (MS)** → **Anterior impression on esophagus**

Causes of Expansile Rib Lesions

Non-neoplastic

- FD
- Paget's
- Brown tumor
- OM
- Gaucher
- Thalassemia

Benign

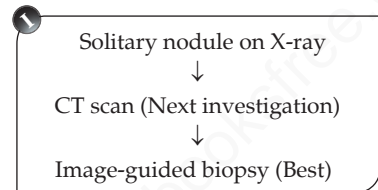
- **FD (most common)**
- Exostosis, Enchondroma
- LCH
- GCT, ABC
- Neurofibroma
- Osteblastoma
- Chondroblasto

Neoplastic

- Metastases (bronchus, kidney, prostate, breast)
- Lymphoma
- **Ewing's (most common malignant tumor of ribs)**
- **Neuroblastoma**
- Osteosarcoma MM/Plasmacytoma
- **Chondrosarcoma (calcified matrix) (most common)**
- PNET

Foreign Body Inhalation

- Enter commonly in Right bronchus (wide and vertical orientation)
- **Peanuts - (most common)**
- **Expiratory – CxR - best**
 - Hyperinflation due to air-trapping (most common) (50%)
 - Atelectasis (collapse) → Radiopaque
 - Recurrent pneumonia (5%)



Congenital Heart Diseases

Indications of MDCT

- **Vascular rings-as assessment of airways is necessary**
- **MAPCAS-major aorto pulmonary collateral arteries**
- **Abnormal pulmonary venous return**
- **Vascular stents**
- **Coronary artery disease assessment**
- **Contraindication to MRI**

| Causes of increased pulmonary flow-plethora (L to R shunt) | Reduced pulmonary flow- oligemia |
|--|--|
| ASD (most common detected in adults) VSD PDA TGA TAPVC Vein of galen malformation Truncus arteriosus | Ebstein's anomaly Triscupid atresia Tetralogy Of Fallot TGA with stenosis of pulmonary artery |

Acynotic Heart Diseases

Septal Defects

- Normal left atrium-ASD (dilated RA and RV)
- Dilated left atrium-VSD, PDA

Coarctation of Aorta

- Inferior rib notching of bilateral 3rd to 9th ribs due to dilated intercostals collateral vascular channels.
- Inferior rib notching of right 3rd to 9th rib- if pre isthmic coarctation (before origin of left SCA)
- Inferior rib notching of left 3rd to 9th rib – if aberrant origin of right SCA from post isthmic area
- Reverse '3' sign on X-ray due to impression by left SCA and post-stenotic dilatation

Cyanotic Heart Diseases

Increased Pulmonary Vascularity

- Total anomalous pulmonary venous return (TAPVR) (types I and II)
- Transposition of the great arteries (TGA)
- Truncus arteriosus (TA)

Decreased Pulmonary Vascularity

- Tetralogy of Fallot (normal heart size)
- Double outlet right ventricle (DORV) with pulmonary stenosis
- Ebstein anomaly with atrial septal defect

Tetralogy of Fallot (Most Common Cyanotic Congenital Heart Disease)

- Infundibular pulmonary stenosis
- Hypertrophy of right ventricle

- VSD
- Overriding of aorta over right ventricle

Pentalogy of Fallot

- Ventricular septal defect (VSD)
- Right ventricular outflow tract narrowing or complete obstruction
- Right ventricular hypertrophy
- Over riding aorta
- **Atrial septal defect (ASD) or patent ductus arteriosus (PDA)**

Ebstein's Anomaly

- Apically shifted septal and mural valves
- Atrialization of ventricle
- Gross enlargement of the heart (Box shaped heart)
- Functional pulmonary stenosis
- Right to left shunt

Pentalogy of Cantrell

- Omphalocele
- Ectopia cordis (abnormal location of heart)
- Diaphragmatic defect
- Pericardial defect or sternal cleft
- Cardiovascular malformations

Radiological Appearance of Heart in Various Diseases

*Fallot's Tetralogy: Boot shaped heart

*Tricuspid Atresia: Box shaped heart

*TAPVC (total anomalous pulmonary venous connection): Snow man appearance, 8 shaped heart, cottage loaf appearance.

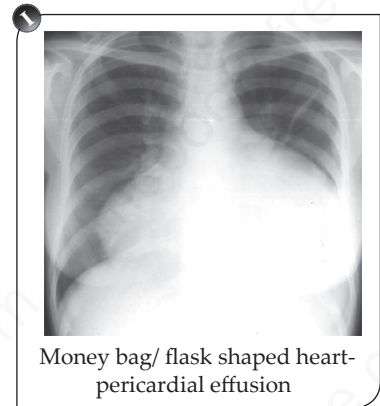
*Constrictive pericarditis: Egg in cup

*Pericardial effusion: water bottle, pear shaped.

*Pulmonary hypertension: Jug handle

*Transposition of vessels: egg shell cracking/egg on side

*Hilar dance on fluoroscopy is seen in cases of ASD and Bronchiectasis



Coronary Calcium Score-Agatston Scoring

- Calcifications as densities ≥ 130 HU

| Score | > | < |
|-------|-----|-----|
| 1 | 130 | 199 |
| 2 | 200 | 299 |
| 3 | 300 | 399 |
| 4 | 400 | |

Total score by summing scores from all the slices →

Indicate risk of cardiovascular events

Total score: 10 → no risk, 1-10 Symbol minimal, 11-100
- mild, 101-400 = moderate, > 400 = severe

*Presence of large amount of calcification does not indicate the presence of significant stenosis.

QUESTIONS

1. **Radiological features of left ventricular heart failure are all, except:**
 - a. Kerley B lines
 - b. Cardiomegaly
 - c. Oligemic lung fields
 - d. Increased flow in upper lobe veins
2. **A patient presents with cough and fever. On X-ray examination, a homogenous opacity silhouetting the right heart border with ill-defined lateral margins is seen. What would be the most probable diagnosis?**
 - a. Pneumonia affecting medial zone of right middle lobe
 - b. Pneumonia affecting superior zone of right lower lobe
 - c. Loculated pleural effusion
 - d. Pneumonia of anterior zone of right middle lobe
3. **Patient with h/o tachyarrhythmias is on implantable cardioverter defibrillator. He develops shock. Best method to know the position and integrity of ICD is to do:**
 - a. Contrast CT
 - b. MRI
 - c. USG
 - d. Plain radiograph
4. **Best noninvasive investigation to check for viability of myocardium is:**
 - a. Echocardiogram
 - b. FDG-18 PET CT
 - c. MIBI Scintigraphy
 - d. Thallium Scintigraphy
5. **Water lily sign is seen in:**
 - a. Hydatid cyst of lung
 - b. Aspergilloma lung
 - c. T.B
 - d. Silicosis
 - e. Hemartoma lung
6. **Left border of heart on chest X-ray is formed by:**
 - a. Left Pulmonary artery
 - b. Right atrium
 - c. Left ventricle
 - d. Right ventricle
7. **Ground glass appearance is not seen in:**
 - a. Hyaline membrane disease
 - b. Left to right shunts
 - c. Pneumonia
 - d. Obstructive TAPVC
8. **All of the following are true about loculated pleural effusion except:**
 - a. It makes an obtuse angle with the chest wall
 - b. The margins are diffuse when viewed end on
 - c. Not confined to any bronchopulmonary segment
 - d. Air bronchograms are seen within the opacity
9. **A patient presented with minimal Rt. sided pleural effusion. The best method to detect this would be:**
 - a. Right lateral
 - b. Left lateral
 - c. Left lateral decubitus
 - d. Right lateral decubitus
10. **Extensive pleural thickening and calcification especially involving the diaphragmatic pleura are classical features of:**
 - a. Coal worker's pneumoconiosis
 - b. Asbestosis
 - c. Silicosis
 - d. Siderosis

11. The most likely diagnosis in a newborn who had a radiopaque shadow with an air fluid level in the chest along with hernivertebrae of the 6th thoracic vertebra on plain X-ray is:
 - a. Congenital diaphragmatic hernia
 - b. Oesophageal duplication cyst
 - c. Bronchogenic cyst
 - d. Staphylococcal pneumonia
12. Pappu 3-year-old boy presents in the causality with H/O sudden onset of respiratory difficulty and stridor on auscultation, decreased breath sound and wheeze on the RT side. The X-ray shows right opaque hemothorax what will be the diagnosis:
 - a. Pneumothorax
 - b. Acute epiglottitis
 - c. Massive pleural effusion
 - d. Foreign body aspiration
13. A child with acute respiratory distress and hyperinflation of unilateral lung in X-ray is due to:
 - a. Staphylococcal bronchopneumonia
 - b. Aspiration pneumonia
 - c. Congenital lobar emphysema
 - d. Foreign body aspiration
14. A neonate presents with respiratory distress, contralateral mediastinal shift and multiple cystic air filled lesion chest. Most likely diagnosis is:
 - a. Pneumonia
 - b. Congenital lung cyst
 - c. Congenital diaphragmatic hernia
 - d. Congenital lobar emphysema
15. A 3-year-old female child developed fever, cough respiratory distress. On chest X-ray consolidation is in right lower lobe. She improved with antibiotics but follow up at 8 weeks was again found to have consolidation in right lower lobe. Your next investigation would be:
 - a. Bronchoscopy
 - b. Bacterial culture of the nasopharynx
 - c. CT scan of the chest
 - d. Allergen sensitivity test
16. A 55-year-old man who has been on bed rest for the past few days, complains of breathlessness and chest pain. The X-ray is normal. The next step in investigation should be:
 - a. Lung ventilation - perfusion scan
 - b. Pulmonary arteriography
 - c. CT angiography
 - d. Echocardiography
17. In pulmonary embolism, findings in perfusion scan is:
 - a. Perfusion segmental defect
 - b. Perfusion defect with normal lung scan and radiography
 - c. Tenting of diaphragm
 - d. Normal chest scan
18. Hampton hump is feature of:
 - a. Pulmonary tuberculosis
 - b. Pulmonary embolism
 - c. Pulmonary hemorrhage
 - d. Bronchogenic carcinoma
19. A 25-year-old man presented, with fever, cough, expectoration and breathlessness of 2 months duration. Contrast enhanced computed tomography of the chest showed bilateral upper lobe fibrotic lesions and mediastinum had enlarged necrotic nodes with peripheral rim enhancement. Which one of the following is the most probable diagnosis?
 - a. Sarcoidosis
 - b. Tuberculosis
 - c. Lymphoma
 - d. Silicosis

20. A patient suffering from AIDS presents with history of dyspnea and non-productive cough X-ray shows bilateral perihilar opacities without pleural effusion and lymphadenopathy. Most probable etiological agent is:
- Tuberculosis
 - CMV
 - Kaposi's sarcoma
 - Pneumocystis carinii
21. A bone marrow transplant recipient patient, developed chest infection. On CT scan, tree in bud appearance is present. The cause of this is:
- Klebsiella
 - Pneumocystis
 - TB
 - RSV
22. A 35-year-old with a history of asbestos exposure presents with chest pain. X-ray shows a solitary pulmonary nodule in the right lower zone. CECT reveals an enhancing nodule adjoining the right lower costal pleura with comet tail sign and adjacent pleural thickening. The most likely diagnosis is:
- Mesothelioma
 - Round atelectasis
 - Pulmonary sequestration
 - Adenocarcinoma
23. Which of the following organs should always be imaged in a suspected case of bronchogenic carcinoma.
- Adrenals
 - Spleen
 - Kidney
 - Pancreas
24. Tumor sensitive to chemotherapy is:
- Pancreatic cancer
 - Renal carcinoma
 - Small cell Ca of lung
 - Melanoma
25. Which of the following is not a cause of an elevated dome of the diaphragm?
- Diaphragmatic paralysis
 - Pulmonary and lobar collapse
 - Subphrenic abscess
 - Large pleural effusion
26. Which among the following is a cause of posterior mediastinal opacity on posterior-anterior (PA) and lateral view of chest radiograph:
- Tortuous innominate artery
 - Bochdalek's hernia
 - Enlarged pulmonary artery
 - Thymoma
27. For chest X-ray best view is:
- PA view
 - kP view
 - Lateral view
 - None
28. Decubitus view is useful in diagnosing:
- Pleural effusion
 - Pleural effusion with dependent hemithorax
 - Pericardial effusion
 - Middle lobe consolidation
29. Minimal pleural effusion is best detected by which X-ray view:
- AP
 - PA
 - Lateral decubitus
 - Oblique
30. What minimal amount of pleural fluid is seen on chest radiograph PA view?
- | | |
|-----------|-----------|
| a. 10 ml | b. 150 ml |
| c. 500 ml | d. 800 ml |
31. Best view to diagnose pneumothorax:
- Lateral oblique
 - PA view in full expiration
 - PA view in full inspiration
 - AP view in full expiration

32. **Air bronchogram may be seen in the following except:**
- Consolidation of lung
 - Lung collapse
 - Bronchoalveolar Ca
 - Normal variant
33. **Silhouetting of left border of heart (silhouette sign positive) on chest radiograph indicates what pathology:**
- Upper lobe
 - Hilar
 - Lingular
 - Lower lobe
34. **Base of heart is formed by:**
- Rt. ventricle
 - LV
 - LV+RV
 - RA+RV
 - RA+LA
35. **Consolidation of which portion of the lung is likely to obliterate the Aortic knuckle on X-ray chest:**
- Apicoposterior segment of Left upper lobe
 - Lingula
 - Right upper lobe
 - right middle lobe
36. **A triangular opacity with clear borders, base towards midline and obliterating right heart border on a chest radiograph suggest that the pathology is likely to be in:**
- Apical segment of right lower lobe
 - Medial segment of right lower lobe
 - Right middle lobe
 - Any of the above
37. **Bulging fissures in lungs in seen in:**
- Klebsiella pneumonia
 - Staphylococcal pneumonia
 - Pulmonary odema
 - Pneumoconiosis
38. **Floating water lily sign is a feature of:**
- Lung hydatid
 - Bronchial adenoma
 - Lung abscess
 - Aspergilloma
39. **Which of the following is a cause of unilateral. Hyperlucent lung on chest radiography?**
- Poland syndrome
 - Asthma
 - Acute bronchiolitis
 - Pleural effusion
40. **The cause of homogenous opacity on X-ray is all except:**
- Pleural effusion
 - Diaphragmatic Hernia
 - Massive consolidation
 - Emphysema
41. **Solitary nodule in lung cannot be:**
- Tuberculoma
 - Neurofibroma
 - Bronchogenic carcinoma
 - Lymphoma
42. **Which of the following signs suggest benign nature in the evaluation of solitary pulmonary nodule on CT scan?**
- Air-bronchogram in nodule
 - Presence of amorphous calcification
 - Fat density within the lesion
 - Spiculated outline
43. **A patient presents with a solitary pulmonary nodule (SPN) on X-ray. The best investigation to come to a diagnosis would be:**
- MRI
 - CT Scan
 - USG
 - Image-guided biopsy

44. **Popcorn calcification is characteristically seen in:**
- TB
 - Metastasis
 - Pulmonary hamartoma
 - Fungal invagination
45. **Characteristics of BENIGN tumour of lung in X-ray:**
- Size > 5 cms diameter
 - Cavitation
 - Peripheral location
 - Concentric dense calcification
46. **Features of pneumothorax are all except:**
- Devoid of lung markings
 - Hypertranslucency
 - Shift of mediastinum to same side
 - Collapse of ipsilateral lung
47. **All of the following are indirect radiological signs of collapse of lung except:**
- Mediastinal displacement
 - Hilar displacement
 - Compensatory hyperinflation
 - Loss of aeration
48. **In patient with high clinical suspicion of pulmonary thromboembolism, best investigation would be:**
- D-dimer
 - CT angiography
 - Ventilation perfusion scan
 - Color Doppler
49. **Gold standard for diagnosing pulmonary embolism is:**
- X-ray chest:
 - Ventilation perfusion scan
 - Blood gas analysis
 - Pulmonary catheter angiography
50. **A 40 years old man presents with a recurrent hemoptysis. X-ray was found to be normal. The next investigation done to aid in diagnosis is:**
- MRI
 - Bronchoscopy
 - HRCT
 - CT-guided biopsy
51. **The following is not the differential diagnosis of an anterior mediastinal mass:**
- Teratoma
 - Neurogenic tumor
 - Thymoma
 - Lymphoma
52. **Commonest mass in the middle mediastinum is:**
- Lipoma
 - Aneurysm
 - Lymph node mass
 - Congenital cysts
53. **Soft tissue mass in chest with rib erosion in X-ray is seen in all except:**
- Leukemia
 - Ewing's sarcoma
 - Multiple myeloma
 - Osteosarcoma
54. **In all of the following increased cardiac silhouette size is seen except:**
- Tetralogy of Fallot's
 - Pericardial effusion
 - Aortic regurgitation
 - Ebstein anomaly
55. **Sequestered lung is most commonly supplied by:**
- Bronchial artery
 - Subclavian artery
 - Pulmonary artery
 - Aorta
56. **Which among the following is not a chest radiographic feature of left atrial enlargement?**
- Double left heart border
 - Elevated left main bronchus
 - Splaying of carina
 - Enlargement of left atrial appendage

57. **Earliest sign of left atrial enlargement is:**
- Posterior displacement of esophagus
 - Widening of carinal angle
 - Elevation of left bronchus
 - Double shadow of right heart border
58. **High resolution computed tomography of the chest is the ideal modality for evaluating:**
- Pleural effusion
 - Interstitial lung disease
 - Lung mass
 - Mediastinal adenopathy
59. **Best method to diagnose Bronchiectasis is:**
- X-ray
 - Bronchography
 - MRI
 - HRCT
60. **All are radiological features of Mitral stenosis except:**
- Straight left border of heart
 - Oligemia of upper lung fields
 - Pulmonary hemosiderosis
 - Lifting of left bronchus
61. **Earliest radiological sign of pulmonary venous hypertension in chest X-ray is:**
- Cephalization of pulmonary vascularity
 - Pleural effusion
 - Kerley B lines
 - Alveolar pulmonary edema
62. **Earliest of venous hypertension is:**
- Upper lobar vessel dilatation
 - Kerley B lines
 - Left atrial enlargement
 - Pleural effusion
63. **All are seen in congestive cardiac failure except:**
- Kerley- B lines
 - Prominent lower lobe vessel
 - Pleural effusions
 - Cardiomegaly
64. **Egg-on-side appearance on X-ray chest is seen in:**
- Tetralogy of Fallot
 - Uncorrected TGA
 - Tricuspid atresia
 - Ebstein's anomaly
65. **Pruning of pulmonary arteries is seen in:**
- Pulmonary hypertension
 - Chronic bronchitis
 - Pulmonary infections
 - Pulmonary transplant
66. **In which of the following a 'Coeur en Sabot' shape of the heart is seen?**
- Tricuspid atresia
 - Ventricular septal defect
 - Transposition of great arteries
 - Tetralogy of fallot
67. **Which is the objective sign of identifying pulmonary plethora in a chest radiograph?**
- Diameter of the main pulmonary artery >16 mm
 - Diameter of the left pulmonary artery > 16 mm
 - Diameter of the descending right pulmonary artery >16 mm
 - Diameter of the descending left pulmonary artery >16 mm
68. **Which of the following is the most common feature of Aortitis on chest X-ray?**
- Calcification of ascending aorta
 - Calcification of descending aorta
 - Calcification of pulmonary artery
 - Calcification of abdominal aorta
69. **Drug used to perform stress ECHO:**
- Thallium
 - Dobutamine
 - Adrenaline
 - Adenosine

70. **Investigation of choice for Aortic dissection is:**
- Aortography
 - CT scan
 - MRI
 - X-ray chest
71. **Isotope used in myocardial perfusion scan is:**
- Technetium
 - Thallium
 - Stannous pyrophosphate
 - Gallium
72. **Test of choice for Reversible myocardial Ischemia:**
- Thallium scan
 - MUGA scan
 - Resting ECHO
 - Coronary arigiography
73. **Which of the following is not true regarding myocardium?**
- Late enhancement on Gd MRI is suggestive of scar
 - Akinetic does benefit by revascularization
 - Low dose dobutamine may be used in hibernating myocardium
 - Rest stress thallium is used to evaluate hibernating myocardium
74. **In a Down's syndrome patient posted for surgery, the investigation to be done is:**
- CT Brain
 - Echocardiography
 - Ultrasound abdomen
 - X-ray cervical spine
75. **The most accurate investigation for assessing ventricular function is:**
- Multislice CT
 - Echocardiography
 - Nuclear scan
 - MRI
76. **Most sensitive investigation for air embolism is:**
- Decreased tidal volume of CO₂
 - Decreased tidal volume of NO₂
 - Doppler ultrasound
 - Central venous pressure
77. **Which one of the following investigations is considered to be "Gold standard" technique for diagnosis of arterial occlusive disease?**
- Doppler ultrasound blood flow detection
 - Duplex imaging
 - Treadmill
 - Digital subtraction angiography (DSA)
78. **Inferior rib notching is seen in:**
- Coarctation of aorta
 - Rickets
 - ASD
 - Multiple myeloma
79. **Bilateral rib notching is seen in:**
- Coarctation of aorta
 - PDA
 - TAPVC
 - All of the above
80. **A child presents with respiratory distress. A vascular ring is suspected. Investigation of choice is:**
- PET
 - CT
 - MRI
 - Angiography
81. **An asymptomatic old patient presents With bruit in the carotid artery. Which of the following is the investigation of choice?**
- Doppler ultrasonography
 - Internal carotid angiography
 - Aortic arch angiography
 - Spiral CT angiography
82. **A young man with pulmonary tuberculosis presents with massive recurrent hemoptysis. For angiographic treatment, which vascular structure should be evaluated first?**
- Pulmonary artery
 - Bronchial artery
 - Pulmonary vein
 - Superior vena cava

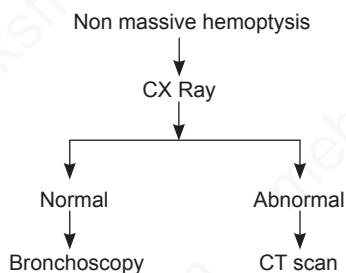
83. A young man with tuberculosis presents with massive recurrent hemoptysis. Most probable cause would be:
- Pulmonary artery
 - Bronchial artery
 - Pulmonary vein
 - Superior vena cava
84. Increased radiolucency of one sided hemithorax may be caused by all except:
- Obstructive emphysema
 - Pneumothorax
 - Expiratory film
 - Patient rotation
85. All are true regarding emphysema finding in X-ray except:
- Low flat diaphragm - Tarrace pattern
 - Tubular heart
 - Decreased intercostal space
 - Increased radiolucency
86. All are true about thymus swelling except:
- Widening of mediastinum on X-Ray
 - Sharp border with shail like appearance
 - Steroid administration reduces size of swelling
 - Shift of trachea on X-ray
87. About diagnosing air embolism with transesophageal echocardiography, which of the following is false:
- It can quantify the volume of air embolised
 - It is a very sensitive investigation
 - Continuous monitoring is needed to detect venous embolism
 - Interferes with Doppler when used together
88. Best investigation for cardiac tempomade is:
- 2D Echocardiography
 - M-Mode Echocardiography
 - Real time echocardiography
 - USG
89. Characteristic X-ray finding in ASD is:
- Enlarged left ventricle
 - Enlarged left atria
 - Pulmonary pletheora
 - PAH
90. A patient is having Mitral stenosis. His X-ray will show all of the following finding except:
- Lifting up of left bronchus
 - Double atrial shadow
 - Obliteration of retrosternal shadow on lateral X-rays
 - Posterior displacement of esophagus on barium swallow
91. Earliest CXR feature of left atrial enlargement is:
- Elevation of the left main bronchus
 - Double cardiac shadow
 - Widening of carina
 - Pericardial effusion
92. Plethoric lung fields are seen in all of the following conditions, except:
- Atrial septal defect (ASD)
 - TAPVC (total anomalous pulmonary venous connection)
 - Ebsteins' anomaly
 - Ventricular septal defect
93. Investigation of choice for pericardial effusion is:
- CT Scan
 - MRI
 - Echocardiography
 - X-ray chest
94. Cardiotoxicity caused by radiotherapy and chemotherapy is best detected by:
- ECHO
 - ECG

- c. Radionuclide scan
d. Endomyocardial biopsy
95. In patient with high clinical suspicion of pulmonary thromboembolism, best investigation would be:
- D-dimer
 - CT angiography
 - Catheter angiography
 - Color Doppler
96. Investigation of choice for pulmonary embolism:
- CT scan
 - Contrast CT
 - Ventilation-Perfusion Scan
 - MRI
97. Pulmonary embolism is best diagnosed by:
- USG
 - X-ray chest
 - Ventilation - Perfusion Scan
 - CT Scan
98. Air bronchogram on chest X ray denotes:
- Intrapulmonary lesion
 - Extrapulmonary lesion
 - Intrathoracic lesion
 - Extrathoracic lesion
99. Calcified pulmonary metastasis is seen in which carcinoma
- Pancreatic carcinoma
 - Thyroid carcinoma
 - Endometrial carcinoma
 - Osteosarcoma
100. Radiological feature of sarcoidosis:
- Hilar lymphadenopathy
 - Hilar lymphadenopathy with parenchymal lung changes
 - No hilar lymphadenopathy with parenchymal lung changes
 - All of the above
101. Water-Lily sign on chest X-ray is seen in:
- Primary TB
 - Aspergillosis
 - Hydatid cyst
 - Cryptococcosis
102. Kerley B lines are seen in which part of chest X- ray?
- Upper portion
 - Mid portion
 - Peripheral lower zone
 - Upper peripheral zone
103. Water bottle heart is seen in
- PDA
 - Chronic emphysema
 - Pericardial effusion
 - Constrictive pericarditis
104. Thick cavity in lung is caused by all except:
- Lung abscess
 - TB
 - Emphysematous bulla
 - Hamartoma
105. Egg on side appearance of heart is seen in the radiograph of?
- TAPVC
 - TGA
 - ASD
 - VSD
106. The following will be most helpful radiological investigation in a patient suspected of left pleural effusion:
- Right lateral decubitus
 - Left lateral decubitus
 - Left lateral erect
 - Right lateral erect
107. Gold standard for pulmonary thromboembolism:
- CT angiography
 - USG
 - Plethysmography
 - Ventilation perfusion scan
108. Differential diagnosis of solitary pulmonary nodule are all *except*:
- Bronchogenic carcinoma
 - Mycetoma
 - Tuberculoma
 - Hamartoma
109. Which of the following causes rib notching on X-ray?
- Coarctation of aorta
 - SVC occlusion

- c. Modified blalock taussig shunt
 - d. All of the above
- 110. Double shadow behind right atrium and- elevation of left main bronchus indicates:**
- a. Right atrium enlargement
 - b. Right ventricle enlargement
 - c. Left atrium enlargement
 - d. Left ventricle enlargement
- 111. Best view for right pleural effusion in X-ray chest:**
- a. Supine
 - b. Prone
 - c. Right lateral decubitus
 - d. Left lateral decubitus
- 112. Radiological feature(s) of mitral stenosis is/are all except:**
- a. Double atrial shadow
 - b. Straightening of left heart border
 - c. Splaying of bronchi
 - d. Prominent aortic knuckle
 - e. Kerley B lines
- Multiple Correct Answers**
-
- 113. Structure forming right border of heart:**
- a. SVC
 - b. IVC
 - c. Rt. atrium
 - d. Lt. atrium appendage
 - e. Pulmonary vessels
- 114. Kerley's 'B' lines are found in:**
- a. Interstitial edema
 - b. Pulmonary venous congestion
 - c. Pericardial effusion
 - d. Mitral stenosis
 - e. Interstitial lung disease
- 115. "Miliary shadow" on chest X-ray is seen in:**
- a. Tuberculosis
 - b. Rheumatoid arthritis
 - c. Pneumoconiosis
 - d. COPD
- 116. Egg Shell calcification is found in:**
- a. Silicosis
 - b. Sarcoidosis
 - c. Metastatic node
 - d. Lymphomafollowingradiotherapy
 - e. Tuberculosis
- 117. Radiological feature of mitral stenosis is/are:**
- a. Double contour of right heart border
 - b. Straightening of left heart border
 - c. Splaying of carinal angle
 - d. Prominent aortic knuckle
- 118. Features of pulmonary venous hypertension are A/E:**
- a. Perihilar haze
 - b. Peribronchial cuffing
 - c. Upper lobar diversion
 - d. Uniformly branching lines parallel to pleura
 - e. Pulmonary ossicles and fine nodular pattern
- 119. Rib notching is found in:**
- a. Neurofibromatosis
 - b. Lymphangioloio-myomatosis
 - c. Aortic aneurysm
 - d. Taussig-Bing operation
 - e. Aortic obstruction
- 120. X-ray picture of VSD:**
- a. Small Lt. ventricle
 - b. Small Rt. Ventricle
 - c. Dilated Lt. atrium
 - d. Dilated pulmonary veins
 - e. Dilated pulmonary arteries

ANSWER KEYS

1. **Ans. c.** Oligemic lung fields
2. **Ans. a.** Pneumonia affecting medial zone of right middle lobe
3. **Ans. d.** Plain radiograph
4. **Ans. b.** FDG-18 PET CT
5. **Ans. a.** Hydatid cyst of lung
6. **Ans. c.** Left ventricle
7. **Ans. c.** Pneumonia
8. **Ans. d.** Air bronchograms are seen within the opacity
9. **Ans. d.** Right lateral decubitus
10. **Ans. b.** Asbestosis
11. **Ans. b.** Oesophageal duplication cyst
12. **Ans. d.** Foreign body aspiration
13. **Ans. d.** Foreign body aspiration
14. **Ans. c.** Congenital diaphragmatic hernia
15. **Ans. c.** CT scan of the chest
This is a case of foreign body aspiration and the best step is to do bronchoscopy and remove the foreign body however with modern imaging techniques with low dose CT scanner, A CT scan is usually done for location
16. **Ans. c.** CT angiography
17. **Ans. b.** Perfusion defect with normal lung scan and radiography
18. **Ans. b.** Pulmonary embolism
19. **Ans. b.** Tuberculosis
20. **Ans. d.** Pneumocystis carinii
21. **Ans. d.** RSV
Though the most common cause of tree in bud opacities is TB. In bone marrow transplant recipient, RSV is a very common infection which give rise to free in bud pattern
22. **Ans. b.** Round atelectasis
23. **Ans. a.** Adrenals
24. **Ans. c.** Small cell Ca of lung
25. **Ans. d.** Large pleural effusion
26. **Ans. b.** Bochdalek's hernia
27. **Ans. a.** PA view
28. **Ans. b.** Pleural effusion with dependent hemithorax
29. **Ans. c.** Lateral decubitus
30. **Ans. b.** 150 ml
31. **Ans. b.** PA view in full expiration
32. **Ans. b.** Lung collapse
33. **Ans. c.** Lingular
34. **Ans. e.** RA+LA
Base of heart is opposite to apex formed by RA + RV
35. **Ans. a.** Apicoposterior segment of Left upper lobe
36. **Ans. c.** Right middle lobe
37. **Ans. a.** Klebsiella pneumonia
38. **Ans. a.** Lung hydatid
39. **Ans. a.** Poland syndrome
40. **Ans. d.** Emphysema
41. **Ans. b.** Neurofibroma
It is extra parenchymal
42. **Ans. c.** Fat density within the lesion
43. **Ans. d.** Image-guided biopsy
44. **Ans. c.** Pulmonary hamartoma
45. **Ans. d.** Concentric dense calcification
46. **Ans. c.** Shift of mediastinum to same side
47. **Ans. d.** Loss of aeration
It is a direct sign
48. **Ans. b.** CT angiography
49. **Ans. d.** Pulmonary catheter angiography
50. **Ans. b.** Bronchoscopy



51. **Ans. b.** Neurogenic tumor
 52. **Ans. c.** Lymph node mass
 53. **Ans. a.** Leukemia
 54. **Ans. a.** Tetralogy of Fallot's
 55. **Ans. d.** Ascending aorta
 56. **Ans. a.** Double left heart border
 57. **Ans. a.** Posterior displacement of esophagus
 58. **Ans. b.** Interstitial lung disease
 59. **Ans. d.** HRCT
 60. **Ans. b.** Oligemia of upper lung fields
 61. **Ans. a.** Cephalization of pulmonary vascularity
 62. **Ans. a.** Upper lobar vessel dilatation
 63. **Ans. b.** Prominent lower lobe vessel
 64. **Ans. b.** Uncorrected TGA

65. **Ans. a.** Pulmonary hypertension
 66. **Ans. d.** Tetralogy of fallot
 67. **Ans. c.** Diameter of the descending right pulmonary artery >16 mm
 68. **Ans. a.** Calcification of ascending aorta
 69. **Ans. b.** Dobutamine
 70. **Ans. b.** CT scan
 71. **Ans. b.** Thallium
 72. **Ans. a.** Thallium scan
 73. **Ans. b.** Akinetic does benefit by revascularization
 74. **Ans. b.** Echocardiography
 75. **Ans. d.** MRI
 76. **Ans. a.** Decreased tidal volume of CO₂
 - Most sensitive monitoring device for venous air embolism is TEE (0.02 mL/kg)
 - Most sensitive non-invasive technique for venous air embolism is precordial Doppler 0.25 mL of air (0.05 mL/kg)
 - Most sensitive gas sensing technique for venous air embolism is ↑ET N₂ (0.5 mL/kg)
 - Most convenient and practical for venous air embolism is ↓ET CO₂

Comparison of method of detection of vascular air embolism

| Method of detection | Sensitivity (mL/kg) | Availability | Invasiveness | Limitation |
|------------------------|---------------------|--------------|--------------|---|
| TEE | High (0.02) | Low | High | Expertise required, expensive, invasive |
| Precordial Doppler | High (0.05) | Moderate | None | Obese patients |
| PA catheter | High (0.25) | Moderate | High | Fixed distance, small orifice |
| TCD | High | Moderate | None | Expertise required |
| ETN ₂ | Moderate (0.5) | Low | None | N ₂ O, hypotension |
| ETCO ₂ | Moderate (0.5) | Moderate | None | Pulmonary disease |
| Oxygen saturation | Low | High | None | Late changes |
| Direct visualization | Low | High | None | No physiologic data |
| Esophageal stethoscope | Low (1.5) | High | Low | Late changes |
| Electrocardiogram | Low (1.25) | High | Low | Late changes |

77. **Ans. d.** Digital subtraction angiography (DSA)

78. **Ans. a.** Coarctation of aorta

79. **Ans. a.** Coarctation of aorta

80. **Ans. b.** CT

MRI is very good investigation for assessment of vascular rings however is child with respiration distress, a less time consuming and fast modality should be used. Also the assessment of airways is important for respiratory distress which is better done with CT scan

81. **Ans. a.** Doppler ultrasonography

82. **Ans. b.** Bronchial artery

83. **Ans. b.** Bronchial artery

84. **Ans. c.** Expiratory film

85. **Ans. c.** Decreased intercostal space

86. **Ans. d.** Shift of trachea on X-ray

87. **Ans. d.** Interferes with Doppler when used together

88. **Ans. b.** M-Mode Echocardiography

89. **Ans. c.** Pulmonary plethora

90. **Ans. c.** Obliteration of retrosternal shadow on lateral X-rays

91. **Ans. a.** Elevation of the left main bronchus

92. **Ans. c.** Ebsteins' anomaly

93. **Ans. c.** Echocardiography

94. **Ans. d.** Endomyocardial Biopsy

95. **Ans. c.** Catheter angiography

Best/gold standard will be Catheter angiography, however is no longer per formed due to high sensitivity, easy availability and non-invasive nature of CT angio.

96. **Ans. b.** Contrast CT

97. **Ans. b.** CT Scan

98. **Ans. a.** Intrapulmonary lesion

99. **Ans. d.** Osteosarcoma

100. **Ans. d.** All of the above

101. **Ans. c.** Hydatid cyst

102. **Ans. c.** Peripheral lower zone

103. **Ans. c.** Pericardial effusion

104. **Ans. c.** Emphysematous bulla

105. **Ans. b.** TGA

106. **Ans. b.** Left lateral decubitus

107. **Ans. a.** CT angiography

108. **Ans. b.** Mycetoma

109. **Ans. d.** All of the above

110. **Ans. c.** Left atrium enlargement

111. **Ans. c.** Right lateral decubitus

112. **Ans. d.** Prominent aortic knuckle.

Multiple Correct Answers

113. **Ans. a.** SVC, **b.** IVC, **c.** Rt. atrium

114. **Ans. a.** Interstitial edema, **b.** Pulmonary, **d.** Mirtal stenosis

115. **Ans. a.** Tuberculosis, **c.** Pneumoconiosis

116. **Ans. a.** Silicosis, **b.** Sarcoidosis, **d.** Lymphoma following radiotherapy, **e.** Tuberculosis

117. **Ans. a.** Double contour of right heart border, **b.** Straightening of left heart border, **c.** Splaying of carinal angle

118. **Ans. d.** Uniformly branching lines parallel to pleura

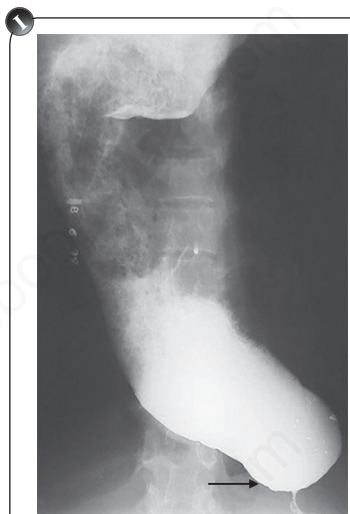
119. **Ans. a.** Neurofibromatosis, **d.** Taussig-Bing operation, **e.** Aortic obstruction

120. **Ans. c.** Dilated Lt. atrium, **e.** Dilated pulmonary arteries

4

Gastrointestinal and Genitourinary System

1 Barium studies are done under fluoroscopic guidance which is real time X-ray imaging and motility can be assessed unlike other studies where fix images are taken.



Achalasia Cardia
(Bird's beak sign)

1 Bird's beak has a smooth surface and rat's tail has irregular surface hence is a feature of carcinoma/secondary achalasia due to Ca.

ESOPHAGUS

- Barium studies are **better to diagnose motility disorders** and dysphagia if more for liquids than solids (as seen in achalasia cardia).
- **Gold std for motility disorders^o → Manometry** like for:
 - Scleroderma
 - Achalasia cardia
 - Diffuse esophageal spasm
- Endoscopic ultrasonography is **investigation of choice** for rest of the esophageal lesions specifically intramural and extraluminal. (can't be seen on endoscopy)
- EUS: even can differentiate b/w **T₁ to T₃ lesions for TNM staging-more accurate** [CT/MRI can only d/d b/w (T₁-T₃) and (T₄) lesions as this can not tell exact level of infiltration in the wall of esophagus]
- EUS even considered IOC for local staging of Ca esophagus over PETCT **But for metastatic workup- PETCT is IOC**
- **IOC for intraluminal lesions and complications of esophageal diseases- endoscopy**

Achalasia Cardia

- **Birds beak at GE junction^o**
- If long duration disease dilated esophagus with air fluid level
- If barium retained for > 5 minutes—supportive evidence.
- Premalignant
- Amyl nitrate and hot water improve while methacholine worsen symptoms.

Diffuse Esophageal Spasm

- Corkscrew on barium, seish kebab, rosary bead

Scleroderma

- Patulous esophagus (GE junction) + mediastinal nodes with GE reflux

GERD

- 24h pH monitoring (**Gold std**)^o
- IOC for consequence/complication—endoscopy

Ca Esophagus

- If Ca develops in long standing case of achalasia cardia—dilated esophagus can be seen both prox. and distal to lesion on barium.

Features on Barium Study

- Irregular mucosal outline—**Rat tail appearance**^o
- Narrowing
- **Shouldering of ends (arrow in figure)**

IOC → Endoscopic ultrasound + biopsy
Biopsy for confirmation of malignancy
Endoscopic ultrasound for local staging

Computed Tomography

- Most widely used for distant spread
- Prone position is preferred
- Criteria for Invasion
 - Loss of triangle of fat between esophagus, aorta, and spinal column
 - $> 90^\circ$ contact with Aorta
 - Nodular protrusion into airway

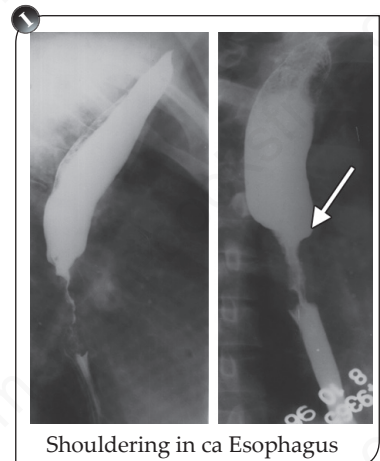
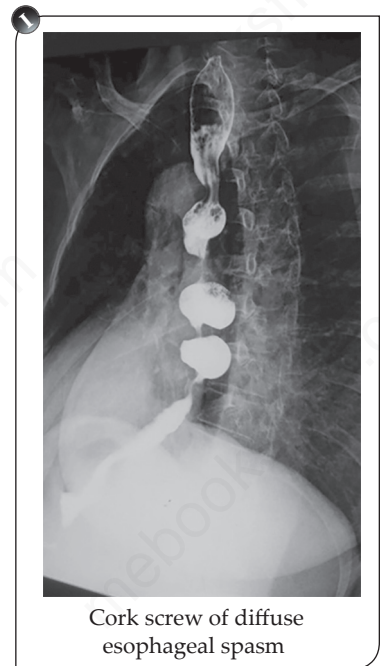
Echo Endoscope/Endoscopic Ultrasonography

- [EUS] (7-12 MHz)₂—highest spatial resolution.
- **Radial—perpendicular to scope**—for staging.
- **Linear—parallel to axis** → for FNA.

**Lower esophageal cancer if epicenter within 5.00 cm from GE junction

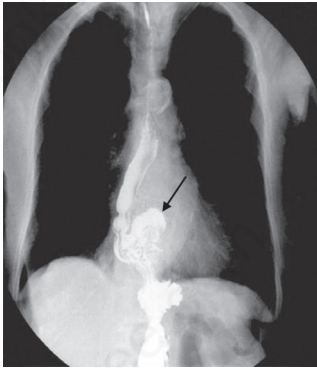
**Coeliac and periesophageal cervical nodes are regional rather than metastasis.

****(N)** esophagus < 5 mm thick on CT



Most malignant nodes do not enlarge and hence nodal enlargement cannot be taken as a criteria for spread of disease.

HERNIA AND DYSPHAGIA



Sliding hiatus hernia

First investigation in patient with dysphagia is barium swallow.

Bochdalek's Hernia

- MC congenital
- Through a defect in posterolateral diaphragm
- Can show 13 pairs of ribs

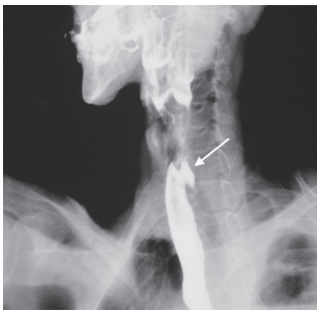Post-traumatic

- On barium herniation of bowel loop in thorax through rent → **Love bird sign**

Hiatus Hernia

- GE junction > 2 cm above hiatus [normal in rolling hernia]
- Widened hiatus > 2.5 cm
- > 3 gastric folds above hiatus [under fluoro direct visualization]
- Schatzki's or B-Ring [Sq-columnar junction] > 2 cm above hiatus

High Resolution Manometry is Gold Std for Sliding Hiatus Hernia.



Zenker's diverticulum

Zenker [Pharyngoesophageal] Diverticulum

- X-ray- can show air fluid level
- **Barium** – IOC → contrast filled out pouching through Killian dehiscence
- Endoscopy is difficult with potential danger of rupture

Killian-Jamieson Pouch/Diverticula

- Protrusion from anterolateral wall of upper cervical esophagus just below the level of cricopharyngeus d/t weakness by passage of inferior laryngeal nerve

Dysphagia Lusoria

- Dysphagia due to aberrant vascular loop
- MC is aberrant right SCA-Angiography → **gold std.**

Dysphagia Aortica

- In old age due to unfolding of aorta

ESOPHAGITIS**Barium Findings**

| | |
|--------------------------|---------------------------------|
| Eosinophilia | - low caliber esophagus |
| Barrett's esophagitis | - granular/reticular appearance |
| Candida | - Large linear mural plaques |
| Radiation/caustic injury | - long stricture |
| HIV/CMV | - Large ovoid/diamond shape. |



- Most common benign sub mucosal lesion of esophagus leiomyoma
- EUS can show origin from M.mucosa/muscularis propria
- **Best: biopsy** as GIST and leiomyoma look same on EUS

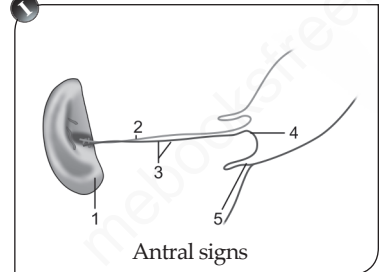


Acquired hypertrophy of pylorus d/t → peptic ulcer/inflammation
→ does not show shouldering

STOMACH**Hypertrophic Pyloric Stenosis**

Hypertrophied muscles lengthens and narrows canal

- IOC → USG^Q
- **Criteria on USG:** Elongated pylorus with thickened muscle (**most specific**)
 - ≥ 16 mm length
 - ≥ 13 mm transverse diameter
 - ≥ 4 mm circular muscle thickness
- Barium Signs of IHPS
 - **String sign [most specific sign] (2)**
 - Shouldering (antral) (due to retrograde bulge of muscles) (5)
 - Double track sign/triple track sign/double string sign
 - Beak sign (antral)
 - Pyloric canal is curved upward posteriorly
 - Diamond sign/Twining recess (3)
 - Pyloric teat sign
 - Olive pit sign (4)
 - Caterpillar sign
 - Kirklin mushroom sign → **d/t indentation of base of duodenal bulb (1)**
- Treatment of choice is ramstedt pyloromyotomy



If perforation suspected → use water soluble contrast as barium can lead to granuloma formation/peritoneal fibrosis.

You don't see shouldering in antral narrowing due to gastritis unlike in IHPS.

Breast ca metastasis can also be like linitis plastica.

- Double bubble sign
 - Ladd bond/ malrotation
 - Annular pancreas
 - Duodenal arterial/ stenosis
- Single bubble sign → IHPS
- **Triple/many multiple bubble** → jejunal/ileal obstruction [Micro colon & apple-peel appearance]
- **Apple core sign** → Ca colon (mainly → R sided)
- **Napkin ring** → Ca colon [(L) sided]
- **Coiled spring sign** → Intussusception
- **String of kantor sign** → Crohn's
- **String sign** → IHPS
- **Rams horn shape** → stenotic disease due to scarring and fibrosis causing narrowing of gastric antrum and pylorus into a funnel
- **Wind sock appearance** → duodenal web/diverticulum.
- **Hide bound appearance** → scleroderma

Peptic Ulcer

| Benign | Malignant |
|--|---|
| <ul style="list-style-type: none"> • Margin-Smooth ulcer mound d/t mucosal edema [circular filling defect/ulcer collar • Sharply punched out lesion-dependent • Ring shadow in nondependent ulcer • Hampton's line (in fallible sign-pathognomonic) (overhanging mucosa at margin) | <ul style="list-style-type: none"> • Heaped up nodular margins • Overt neoplastic tissue with shaggy and necrotic base • Gastric folds don't reach the ulcer crater • Carman's Meniscus sign |
| <ul style="list-style-type: none"> • Penetrating sign if in wall rather than mass with-smooth/clean base of ulcer • Radiating folds are smooth symmetric reaching up to edge of ulcer in sponge like manner [spoke wheel patterns] [ulcer crater may extend beyond wall] • Can show area gastricae in ulcer crater (N) peristalsis | <ul style="list-style-type: none"> • Kirkland complex • Intraluminal crater rather than only in wall • Strong enhancement at the site of ulcer than adjacent wall • Abnormal peristalsis |

**Superficial erosions till muscularis. Mucosa, if complete → would cause mound of edema.

****Trifoliate duodenum** → chronic duodenal ulcer with scarring.

**In barium study do both prone and supine views to exclude anterior wall perforation.

Gastritis

- Thick folds > 5 mm (most useful), [For H. Pylori Gastritis]
- Prominent area gastricae [most specific]-for H. Pylori gastritis
- Antral narrowing
- Inflammatory polyps

Gastric Striae

- Transverse folds impressions by gastric muscularis mucosa in antral gastritis.

Emphysematous Gastritis

- It due to acute gas forming infection

Gastric Emphysema

- If without infection

Phlegmonous Gastritis

- If pan mural inflammation

Linitis Plastica

- Better appreciated on fluoroscopy than endoscopy:
- Causes
 - Adenocarcinoma
 - Diffuse scirrhous carcinoma [**leather bottle appearance**]
 - **NHL [If adenopathy is bulky and also below renal hila and with splenomegaly]**
 - Breast metastasis
 - Kaposi sarcoma

Bull's Eye Lesions in Stomach (due to central ulceration)

- Submucosal metastasis [MC-melanoma]
- Lymphoma
- Carcinoma breast, bronchus, pancreas
- Carcinoid
- Leiomyoma
- Kaposi sarcoma
- Ectopic pancreas [central dip due to rudimentary duct]

Rotation/Volvulus

Organoaxial rotation [more common]

- Axis along cardia and pylorus
- If horizontal originally then → Greater curvature up and lesser low (more common)
- If *vertical* → (R) → (L) shift

Mesentericoaxial (mainly traumatic)

- Antropylorus at a higher level than fundus and cardia [known as → **Upside down stomach**]

Radiological Signs of Malabsorption on Barium


- Dilatation
- Rapid transit
- Flocculation of contrast [**Snow flake-like deposits**]
- Segmentation of barium column
- Fold thickening

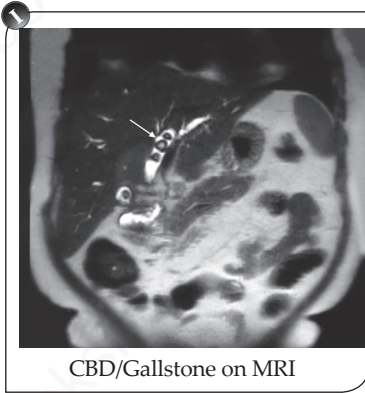1 ****Presence of gastric varices in absence of esophageal varices is a sign of splenic vein thrombosis [due to pancreatitis/ca pancreas].**

1 ****Villous adenomas [duodenum/intestine] → cauliflower/soap bubble appearance due to trapping of barium in the crevices**

1 ****Marked irregular narrowing of antrum and 1st part of duodenum → Pseudopostbillionth I-appearance [Crohn's disease].**

1 ****Wilkie's SMA compression synd-If compression and dilatation of duodenum (transverse IIIrd part) present even on prone films.**





- Excessive secretion
 - Causing dilution of contrast
 - Reduced mucosal coating
- “Moulage sign” → Tube-like appearance of bowel
- **Stacked coin appearance** → In HSP due to submucosal hemorrhages
- **Hide bound appearance** → scleroderma
- **Scalloped edges of sigmoid colon**-pneumatosis intestinalis
- **Saw tooth appearance** → Diverticulosis
- **String sign**
 - Crohn’s (of Kentor’s)
 - TB
 - IHPS

Ileocecal Tuberculosis (MC site of intestinal TB)

- Mucosal fold thickening
- Ulcers (transverse/star shaped/circumferential [*Crohn’s disease have longitudinal ulcers*])
- Terminal ileum stricture
- Funnelled contracture of cecum
- **Fleischer sign/Inverted umbrella defect** [due to thick, rigid, irregular IC-valve]
- **Sterlein sign** → rapid emptying of narrowed ileum in cecum
- Symmetrical annular napkin ring stenosis and uridened ileocecal angle (N) – 90° → it becomes obtuse)
- Amputated cecum → rigid, contracted, cone shaped retracted/pulled up cecum out of ileal fossa.
- **String sign**
- **Goose neck appearance**–ileum hanging from fibrosed, pulled up cecum.
- **Purse string** appearance of cecum

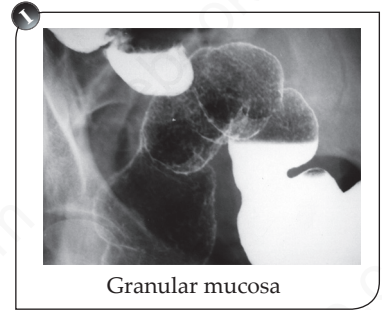Inflammatory Bowel Diseases

- **Crohn’s disease** → skip lesions
 - **Aphthoid ulcers (Earliest)** Fissure ulcers, abscess, fistula
 - **Longitudinal ulcer along mesenteric border** → characteristic sign
 - **Cobblestoning** → longitudinal and transverse ulcers separating intact mucosa

In a case of previous hemicolectomy due to CD, anastomosis is the most common site of recurrence.

*Comb sign, mesenteric edema, layered wall T2 hyperintensity and lymph nodes.
Signs of active CD

- **Strictures** → Multiple strictures are virtually diagnostic of CD (string sign of Kantor if terminal ileum stricture)
- **Pseudodiverticula** → asymmetrical involvement of intestine [represents (N) intestine in an otherwise severely involved segment]
- Inflammatory polyps not frequent in CD (as filling defects)
- **Thickening of wall** → displacement of adjacent barium filled bowel loops [which is also due to fibro fatty proliferation of the peritoneal fat]
- Stenosis + dilated proximal bowel loops
- Adhesions
- Enlarged ileocecal valve
- **CT enteroclysis/CT enterography** → IOC
 - Stratification/target mural thickening [active disease]
 - Comb sign – due to ↑ vascularity/Halo sign due to submucosal edema
- MRI → better to detect fistula or sinuses.



Granular mucosa

↑ Submucosal fat → **chronic UC**
Mesenteric fibro fatty proliferation – **chronic CD** [Presacral space widening in rectal disease]

Ulcerative Colitis

- Granular mucosa [earliest change]
- **Toxic mega colon** if transverse colon > 5.0 cm [As transverse colon is least dependent in supine position]
- Haustration always absent → if present it should not be because of toxic mega colon
- Collar button ulcers [on in profile view]
- Pseudopolyps
- Contiguous-No skip lesion
- Reflex/backwash ileitis
- **Pipe stem colon** [ahaustral]
- ↑ Presacral space [due to proliferation of perirectal fat]
- **Instant Enema** (If active disease → colon is almost always free of fecal matter → no need for bowel preparation)

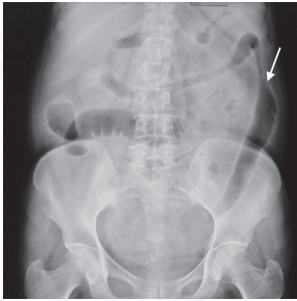
TB-A Common Burden in HIV (TACBH) pneumonic for aphthoid ulcers.

*Free perforation is rare in CD d/t chronic adhesions
*Mural thickens is more in CD than UC

Crohn's diseases
Aphthoid ulcers [earliest change]
Raspberry-/Rose thorn appearance due to deep ulcers.
**Montreal classification for Crohn's disease

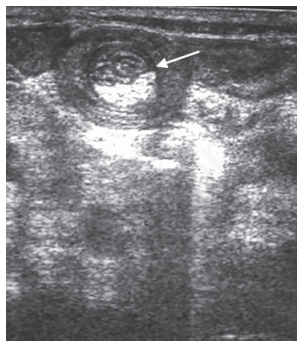Causes of Aphthoid Ulcers (black mound of halo due to edema)

- CD (not seen in UC)
- Amebiasis



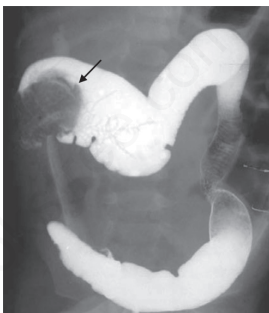
Featureless ahaustral colon- UC

- Radiation colitis [due to endarteritis] 4500 rad/ > 45 gray
- Radiation enteritis → **Mucosal tacking**



Intussusception target sign

****Hellmer sign** → lucency b/w liver and abdominal wall due to fluid in ascites.



Claw sign of intussusception on barium

- Tuberculosis
- Behcet's disease
- HIV-related infection

Sacculations

- CD
- Ischemic colitis

Accordion Sign

- AIDS related ischemic colitis
- Severe edema due to cirrhosis
- Pseudomembranous colitis

Lymphoma

- **Aneurysmal dilatation of bowel loops**
- **Sandwich-like massive mesenteric lymphadenopathy**
- Secondary deposits in RIF → narrowed loops in parallel configuration—**Palisading**

Ascariasis

- **Medusa head** appearance
- Sphagetti appearance
- Bulls eye sign
- Impacted worm sign
- Inner/double tube sign

Intussusception

- Coiled string sign-barium
- Target sign-USG (Image)
- Claw sign-barium
- Hayfork sign-USG
- Empty right iliac fossa
- Barium enema can be both therapeutic and diagnostic-usually not done
- Preferred T/t is ultrasound guided hydrostatic reduction

Hirschsprung's Disease

- Most common causes of neonatal colonic obstruction
- Characterized by a short segment of colonic aganglionosis

- Smaller calibre affected bowel with dilated normal proximal bowel (6.5 cm) mega rectum
- Most important sign is transition zone with reversal of recto sigmoid ratio (normally rectum is more dilated than sigmoid colon).

CURRENT STATUS

In situation of acute abdomen—supine abdomen and erect chest radiograph (after 10 min of standing are basic standard radiograph)

- **Supine** → with empty bladder, from diaphragm to hernial orifices which in practice means that the obturator foramen should be included.
 - (L) Lateral decubitus—It can clarify if erect X-ray is confusing for free air (most sensitive)
 - Erect abdomen is misleading to differentiate acute obstruction with ileus.
- **Valid indications of radiography in (acute abdomen)**
 - Suspected viscus perforation
 - Bowel obstruction
 - Bowel wall pattern [ischemia, colitis]
 - Intraabdominal foreign body.

Signs of Pneumoperitoneum

On supine radiograph

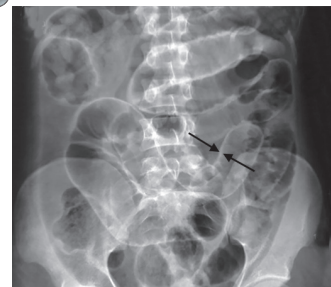
1. **Football sign** (hydropneumoperitoneum)
2. **Right UQ gas**
 - Perihepatic
 - Subhepatic
 - Morison's pouch
 - Fissure for ligamentum teres
 - Triangular air
3. **Rigler's [double wall]**—visualization of both sides of bowel wall (Pathognomonic) (Image)
 - Ligaments
 - Falciform [lig. teres]
 - Medial umbilical lig [inverted 'v' sign]

On standing radiograph

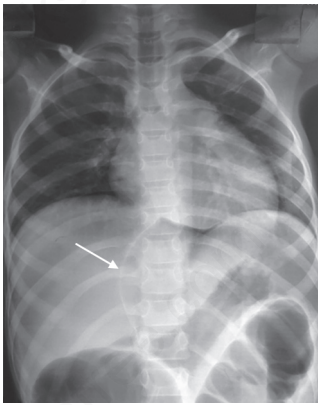
- Gas under (R) and (L) hemi diaphragm may join in midline—cupola sign
- Gas under diaphragm
- Doge's cap sign

Causes of Ca⁺⁺ in Right Hypochondrium

- Gallstone
- Porcelain GB
- Calcified (N) costal cartilage
- Hepatic adenoma, hemangioma, abscess, metastasis, hydatid cyst
- Calcification in kidney/stone
- Phlebolith/fecolith

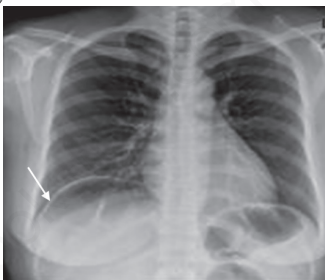

Rigler's sign

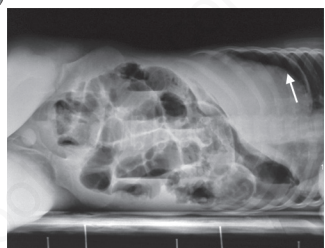


Falciform ligament sign

Gas in soft tissue of (L) thigh—classical site for gas from a diverticular disease/perforation.



Pseudopneumoperitoneum [chilaiditi synd.]



Gas around liver in left lateral decubitus view

Pseudopneumoperitoneum

- Intestine b/w liver and diaphragm [chilaiditi synd.] (Image)
- Subpulmonary pneumothorax
- Subphrenic abscess
- Curvilinear atelectasis
- Subdiaphragmatic fat
- Cysts in pneumatosis intestinalis
- Diaphragmatic irregularities/multiple humps

Bowel Obstruction

- **Acute gastric dilatation**—paralytic—elderly—due to fluid and electrolyte disbalance.
- **Paralytic ileus**—peritonitis, post-op, metabolic, ischemic, renal failure, morphine

In developed world MC cause of **Small Bowel Obstruction** → **adhesions due to previous surgeries.**

In underdeveloped/developing world is strangulated hernia [3/4th cases].

Radiological Signs of SBO

- Obstruction small bowel → centrally placed bowel loops > 3.0 cm
- **Transition zone** → most reliable CT sign [dilated prox. and collapsed distal]
- **Small bowel feces sign**—[pathognomonic and help in identifying transition zone]
- **String of beads**—diagnostic of acute obstruction.

Radiological Signs of Large Bowel Obstruction

- Peripherally Placed bowel loops > 5 cm with Haustra
- **Imminent rupture of cecum** > 9 cm diameter
- **Air in rectum** suggests paralytic ileus

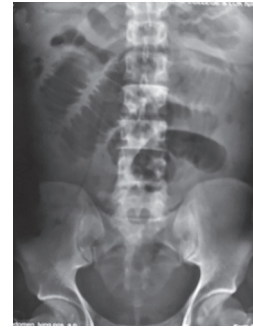CT Signs of a Closed Loop Obstruction

- Small bowel dilatation
- 'V' shaped or radial fluid-filled loops
- Mesenteric vessels converging toward point of obstruction
- Triangular loop with or without whirl or beak.
- Angulated or tethered loops on CT—adhesions
- Pseudo obstruction—elderly

- US/UK-Ca colon MC-for large bowel obstruction, diverticulitis—Ind MC cause.
Underdeveloped → 85% by **volvulus**.

Sigmoid Volvulus

- **Liver overlap sign** → ahaustral sigmoid colon
- Dilated descending colon-[**left flank overlap sign**]
- Left pelvis-[**pelvic overlap sign or inferior convergence**]
- Volvulus apex above T10 on left-side below diaphragm
- Enema-**hooked beak [bird of prey sign]**
- (Screw pattern of mucosal folds at twist)
- **Whirl sign**-due to twisted bowel and mesentery




Coiled spring sign

- *Best projection to detect pneumoperitoneum is PA Chest X-ray—if patient, cannot get erect then left lateral decubitus view after 10 minutes in that position.

Cecal Volvulus (30–60 years) younger age

- ‘**x-marks the spot**’ sign-two overlapping transition at the site of twist
- Pole of cecum and appendix in (L) upper quadrant (if inversion)
- (L) side of colon is collapsed

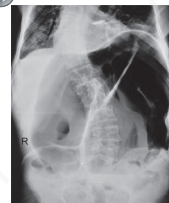

Ischemic Colitis

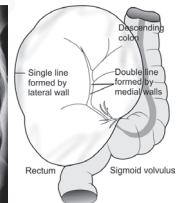
- **Splenic flexure and adjacent descending colon (MC)**
- Submucosa gets thickened due to edema and hemorrhage
 - **Thumb printing** and functional obstruction with dilated proximal bowel loops

Colitis (IBD)

- **Inactive disease if formed feces.**
- **Extensive colitis**-if absence of feces.
 - When haustra disappears → Ulcers have penetrated muscle layer.
 - Daily plain AXR- justified for follow-up
- **Pseudomembranous colitis** →
 - Thumb printing-transverse colon (MC)
 - Accordion sign.



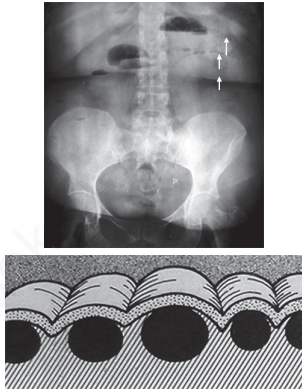
Sigmoid volvulus



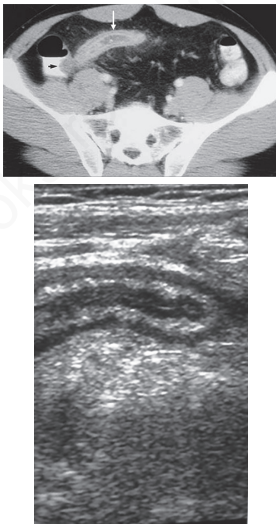String of beads

- FMD on [angiography]
- Chronic pancreatitis (chain of lakes) [MRCP/ ERCP]
- Small bowel obstruction [supine X-ray]

USG is IOC in pediatric population or pregnant ladies.
Cholecystitis – IOC–USG
Calculus shows acoustic shadow (an USG artifact)



String of bead sign



Acute appendicitis- CECT, USG

*In a c/o chronic intestinal bleeding-demonstration of persistent vitelline artery is a hallmark for angiographic disease of Meckel's diverticulum.

Appendicitis-IOC-CECT

USG

- Appendix > 7 mm (USG) (> 6 Cm) CT
- Appendicitis can cause generalized ileus
- **On USG-noncompressible, aperistaltic, blind ending tubular structure in RHC arising from cecum**
- Perforated appendix is compressible.
- CT-luminal contrast or air in the cecum pointing toward the obstructed origin of the appendix— **arrowhead sign.**
- Focal cecal thickening due to edema at the origin of the appendix → **cecal bar sign.**
- In pediatric patients, USG is the preferred investigation for acute appendicitis.

Ischemia

Arterial

- Acute occlusive (**thrombus**) → Mural thickening, dilatation, **nonenhancement, ascites (66%)**
- Nonocclusive **hypotension** → Mural thickening, mucosal **hyperenhancement.**

Venous Thrombosis

- **Mural thickening + mucosal hyperenhancement, mesenteric stranding + vascular engorgement, ascites (> 70%)**
- Ischemic colitis → **thumb printing**

Causes of Pneumatosis Intestinalis + Air in Portal/SM Veins

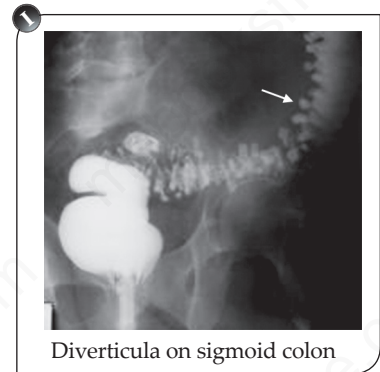
- Ischemia
- Infective/Inflammation
- Asthma
- Neoplastic conditions

Progressive Systemic Sclerosis

- Increased number of mucosal folds
- **Wire spring/hide bound appearance**
- **Sacculations** [pseudodiverticula]

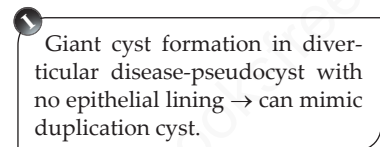
Diverticula-Sigmoid Colon MC Site

- **CT-most accurate** in determining the severity of diverticulitis saw tooth appearance on barium enema studies (arrow in image)
- Diverticula filled with diverticulolith [fecal matter]-may appear hyperdense like a polyp.
 - Fistula formation-MC with bladder



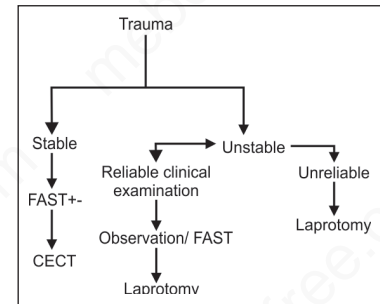
Blunt Trauma Abdomen

- **Gold std** → DPL not done now a days
- **IOC** → CECT in stable patient
- **FAST** → It unstable and if time permits (Figure-fluid in morrison's pouch)
- **Laparotomy** → **If unstable**



Gallstones → 90% lucent

- **Do not overlap spine on lateral X-ray**
- If air in stone → **Mercedes Benz sign**
- **IOC-USG** → **acoustic shadowing**-also seen in renal stones
- **WES complex** [wall-echo shadow complex] [Fibrosed wall → stone (echo) → shadow] → d/t cholelithiasis and chronic cholecystitis
- Acute cholecystitis → [Tc99HIDA **best investigation**]
- MRI- GB calculi seen as filling defect on T2W images (Figure)
- **CBD stone** → **MRCP (IOC)** → meniscus appearance.



Adenomyomatosis of Gallbladder

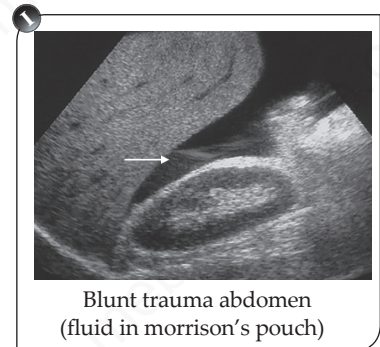
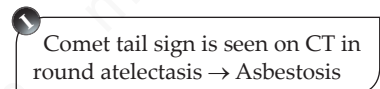
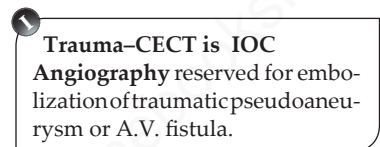
Generalized

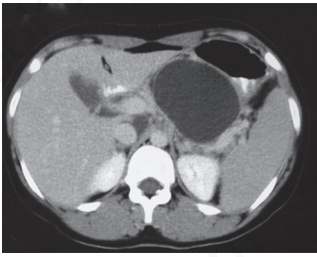
- Pearl necklace GB (T2WMRI)
- **Comet tail artefact (-USG)** [d/t **reverberation artifact** b/w cholesterol crystals in RA Sinus [pathognomonic]
- **String of beads sign** in thick GB wall (T2WMRI)

Localized-Fundal

Pancreatitis

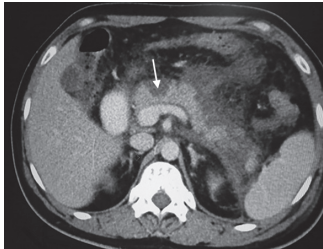
- Acute pancreatitis diagnosed by clinical and lab parameters
- **IOC for complication of acute pancreatitis** → CECT
 - Necrosis which is most imp. prognostic criteria (Figure).



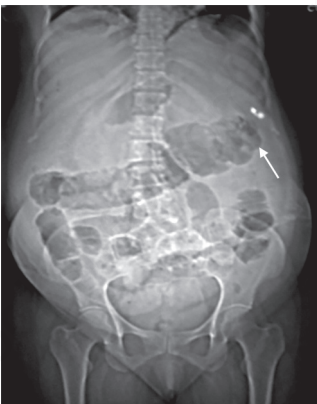

Pseudocyst

- IOC for Chronic pancreatitis → MRCP
- IOC for chronic calcific pancreatitis → NCCT
- Chain of lakes: in chronic pancreatitis (ERCP/MRCP)



Necrosis in acute necrotic pancreatitis



Colon cut-off sign

Diagnosis of Acute Pancreatitis (2-out of 3)

1. Abdominal pain (typical)
2. Three fold or greater ↑↑ in S. amylase or S.lipase
3. Confirmatory findings on cross sectional imaging

CECT Findings in Acute Pancreatitis

- Bulky pancreas
- Ill-defined peripancreatic planes with loss of lobulations
- Peripancreatic fluid collections.

Best prognostic scoring by → CTSI (CT severity Index)

X-ray

- Sentinel loop/colon cut-off/duodenal ileus/mottled lucencies/gasless abdomen/Renal halo sign

Causes of Ca⁺⁺ in Pancreas

- Chronic alcoholic pancreatitis
- Hereditary
- Malnutrition
- Parathyroidism

Periampullary carcinoma

- Widened 'c' loop of duodenum
- Frost berg inverted '3' sign
- Double duct sign
- Antral pad sign in c/o ca head of pancreas.

| | |
|-----------------------|---|
| Acute pancreatitis | <ul style="list-style-type: none"> • Renal halo sign, • Gasless abdomen, • Colon cut-off sign, • Sentinel loop sign |
| Chronic pancreatitis | <ul style="list-style-type: none"> • Beaded/string of pearls/chain of lakes • Rat tail/appearance • Nipping/narrowing of origins of side branches of MPD or CBD ± double duct sign |
| Calcific pancreatitis | <ul style="list-style-type: none"> • Double duct • Scrambled egg • Inverted 3 sign • Rose thorning of II part of duodenum |

Causes of Air in Biliary Tract

- Due to fistula with GI tract
 - Trauma

- Surgery
- Malignancy
- Duodenal ulcer
- Gallstone ileus
- **Emphysematous cholecystitis**
- **Reflux from duodenum**
 - Passage of stone/ascariasis
 - Sphincterotomy/plasty

FOCAL LIVER LESION

- Very commonly encountered lesion on abdominal ultrasound.
- Ultrasound is a very good investigation to differentiate cystic lesion from solid lesion.
- Ultrasound is not very good in characterizing a solid lesion.
- Best investigation for characterization of a liver lesion is triphasic MRI.
- Usually biopsy is not required. It may be done in case of metastatic lesion to look for primary source.

| Lesions | Classical triphasic CT/MRI findings |
|---------------------------------|--|
| Hepatic cyst | Sharply demarcated wall, water density, non enhancing |
| Hemangioma | Peripheral filling in of contrast over time "Light Bulb Sign" on T2 MRI |
| Focal nodular hyperplasia (FNH) | Early filling in arterial phase with central filling defect (scar) |
| Hepatic adenoma | Variable, central changes due to hemorrhage often seen |
| Metastasis | Mostly multiple low attenuation lesions, rim enhancement without "filling in" |
| Abscess | Well demarcated hypodense areas with peripheral enhancement, may see gas |
| Hepatocellular carcinoma (HCC) | Early arterial enhancement, fast wash-out, delayed fibrous capsule enhancement |

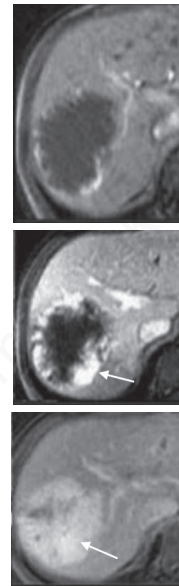
X-ray Signs of Splenic Trauma

- **Obliteration of splenic outline (best)**
- Loss of psoas outline
- Indenting gastric air bubble

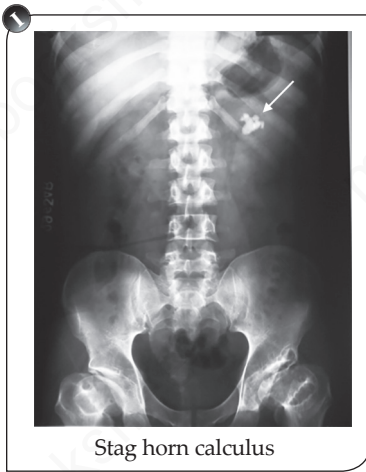

Few important full forms:

- HIFU → High frequency ultrasound
- TACE → Transcatheter arterial chemoembolization
- FAST → Focused assessment by sonography for trauma
- ALARA → As low as reasonably achievable
- BIRADS → Breast imaging reporting and data system
- FLAIR → Fluid attenuated inversion recovery sequence



Hemangioma: Gd-MRI
Progressive centripetal enhancement



- Fracture of lower ribs and elevation of (L) hemidiaphragm

Internal Hernias

(L) Paraduodenal (75%)—through landzert fossa at duodenojejunal junction bowel loops behind stomach and pancreas displacing inferior mesenteric vein anteriorly.

(R) Paraduodenal → [In cases of nonrotated bowel]—Through waldeyer's fossa → behind SMA and inferior to IIIrd part of duodenum

- Encapsulated small bowels in ® mid-abdomen
- Ante displacement of (R) celiac vein
- Looping of small intestine around SMA

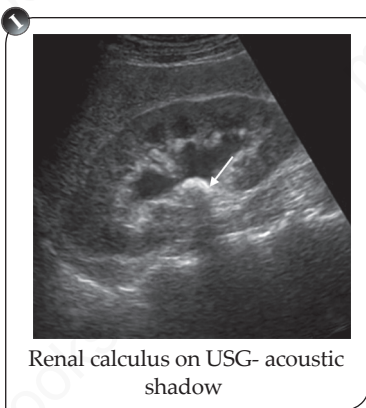
Renal calculi → 90% radiopaque

NCCT is investigation of choice

Uric acid and xanthine stones are lucent renal

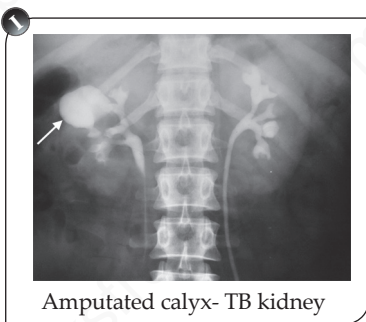
Ureteric stones overlap spine on lateral X-ray.

Cysteine stones are poorly radiopaque due to sulfur



Ureteric Colic/Obstruction

- IOC for ureteric colic → NCCT KUB
- Acutely obstructed kidney → Increasingly dense nephrogram without or delayed contrast in PCS on IVP
- USG → **acoustic shadow/twinkling artifact** on color Doppler
- Chronic obstruction –Hydronephrosis, No persistent nephrogram with poor pyelogram



Renal Tuberculosis

- *IOC for early renal TB → IVP
- For Chronic → CT
- MRI: No role
 - Predominantly for evaluation of nonfunctioning kidney.

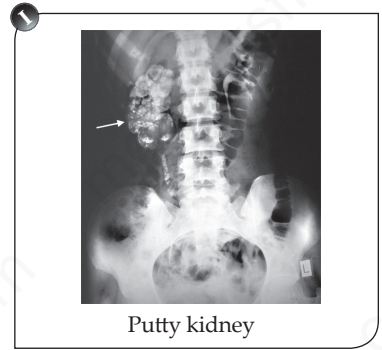X-Ray

- Lobar distribution of calcification is specific for renal TB (calcification is rare in UB)

IVU

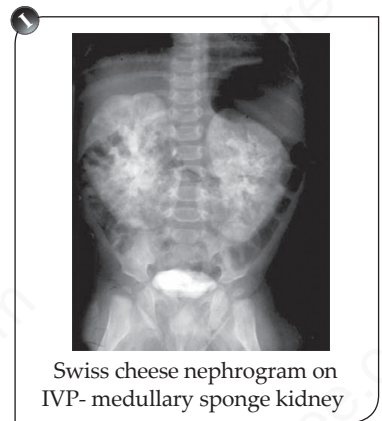
- Early features → loss of definition of minor calyx with **feathery outline**. (Moth eaten calyx)

- Upward pointing renal pelvic calculi due to **hiked up pelvis**
- **Autonephrectomy/putty kidney**
- Strictures with phantom calyx, amputated calyx
- Kinking of pelvis (**Kerr's kink**)
- **Beaded and corkscrew ureter**
- Pipe stem ureter
- Caseocavernous type → enlarged sac like poorly functioning kidney
- **Thimble bladder**—contracted (without calcification)
- **Golf hole ureter** on cystoscopy



Cystic Disease of Kidneys

- **Cortical beak sign** on CT → simple cyst → filling defect on IVP
- Swiss cheese/spider leg → IVP → PCKD
- **Sentinel cyst** → tubular obstruction by tumor
- Striated nephrogram → ARPKD → (potter type-I)
[ANC USG-bilateral enlarged echogenic kidneys + oligohydramnios]
- **Swiss cheese nephrogram**
 - ADPKD
 - Medullary sponge kidney



Renal Hydatid

If contrast between ectocyst and pericyst → of Renal hydatid → **Goblet of urine glass or Surraco's sign**.

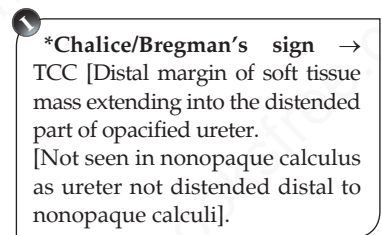
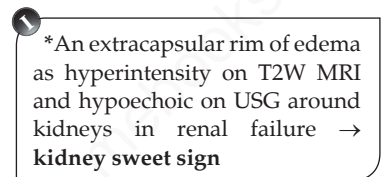
- Crescent sign

Horseshoe Kidney

- **Flower vase appearance on** → IVP
- IVP → medially projecting lower pole calyces → '**Hand shaking sign**'
- More prone to → calculi/trauma/Wilm's tumor/obstruction

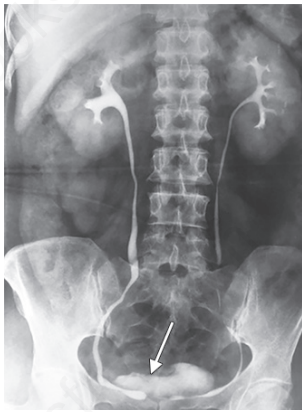Ureterocele

- **Adder head/ cobra head** → IVP
- Alternating distending and collapsing anechoic cyst at VUJ on—USG



Immediate Faint Persistent Nephrogram

- Chronic glomerular disease



Right ureterocele- adder head appearance

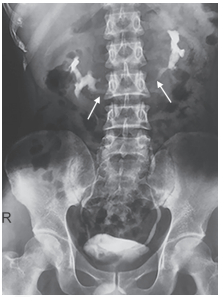- Acute glomerulonephritis
- Renal vein thrombosis
- Chronic severe ischemia

Unilateral Delayed Nephrogram

- Obstructive uropathy
- ↓Renal blood flow due to Renal artery stenosis/RVT

Increasingly Dense Nephrogram

- Acute renal obstruction
- Hypotension/dehydration
- Acute Papillary necrosis
- Renal ischemia
- MM/Myeloid
- Acute glomerular disease
- Intratubular obstruction
- Acute Renal vein thrombosis



Horseshoe kidney- shaking hand sign

Immediate Dense Persistent Nephrogram

B/L

- Acute tubular necrosis/obstruction
- Severe inflammatory renal disease
- Systemic hypotension

U/L

- Renal artery stenosis
- Renal vein thrombosis
- Urinary tract obstruction

Striated Nephrogram: Prominent nephrons seen extending into the medulla as medullary rays.

U/L

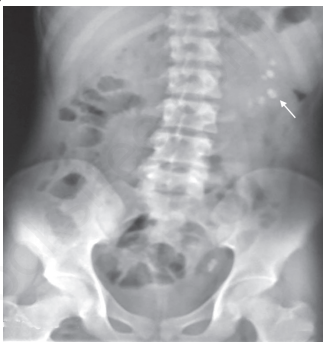
- Obstructive nephrogram (acute)

U/L or B/L

- Pyelonephritis
- Polyarteritis nodosa (PAN)
- Trauma

B/L

- Medullary cystic kidney disease/sponge
- ARPKD



Medullary calcinosis

Cortical Rim Sign: Enhancement of only most peripheral rim of renal cortex:

- Acute cortical necrosis
- Renal infarction
- Renal vein thrombosis
- ATN
- Acute arterial obstruction
- Severe hydronephrosis.

Nephrocalcinosis

| Cortical | Medullary |
|--|---|
| <ul style="list-style-type: none"> • Acute cortical neurosis • Alport's synd. • Graft rejection • Hemolytic-uremic synd. • Chronic glomerulonephritis | <ul style="list-style-type: none"> • Distal renal tubular acidosis • Hyperparathyroidism • Sarcoidosis/hypercalcemia • Medullary sponge kidney • Hyperoxaluria |

Radionuclide

- IOC for GFR – Tc⁹⁹DTPA (only glomerular filtration)
- IOC for R. function – MAG 3 (both glomerular and tubular excretion)
- IOC for scar/reflux nephropathy – Tc⁹⁹DMSA
- Screening for renovascular hypertension – captopril DTPA scanning
- IOC for Renal artery stenosis – MR Angiography
- Gold standard – Renal angiography

Medially Placed Ureters

B/L

- Retroperitoneal fibrosis
- Pelvic lipomatosis
- Abdominoperineal resection
- Ureterolysis

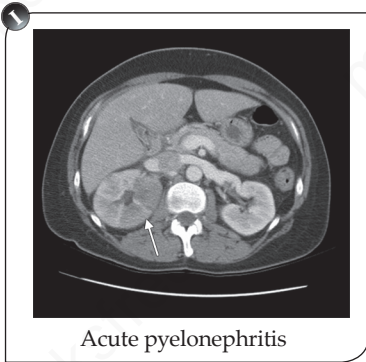
U/L

- Retrocaval ureler

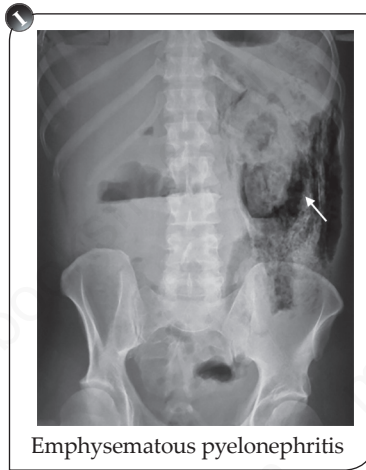Duplex Pelvicalyceal System

Weigert-Meyer law

- Upper moiety drains lower and more medial than lower moiety in UB.



Acute pyelonephritis



Emphysematous pyelonephritis

- Upper moiety more prone to ureterocele which is usually obstruction
 - Lower moiety → reflux
- **If ureters—fused distally** → yo-yo reflux from one ureter to the other which is draining non-functioning/ excreting moiety.

- IOC for reflux (VUR) – MCU (Micturating cystourethrography)
- For posterior urethra – MCU
- For anterior urethra – RGU (retrograde urethrography)
- For posterior Urethral Valve – MCU

Tumors

- **Oncocytoma**
 - Spoke wheel pattern on angiography however not characteristic:
- **Angiomyolipoma**
 - Fat containing lesion [CT attenuation— 50' to '– 100' HU]
 - Associated with tuberous sclerosis

| Wilms | Neuroblastoma |
|---|---|
| <ul style="list-style-type: none"> • Vascular displacement • does not cross midline • calcification rare • Pulmonary metastasis • Necrotic areas | <ul style="list-style-type: none"> • Encasement • Crosses midline • Calcification common • Usually metastasize to bone • Usually solid |

Renal Artery Stenosis

Signs of significant renal artery stenosis on Doppler

- Percentage of diameter > 70% stenosis
- Collaterals (**most specific-Harrison**)
- Systolic pressure gradient > 20 mm Hg across the lesion
- Poststenotic dilatation of the renal arteries with turbulent and reversed flow.

Direct Signs

- ↑Peak systolic velocity (> 150 cm/sec)
- Peak renal artery to aorta ratio (RAR) > 3.5
- Absence of blood flow during diastole.

Indirect Signs of Renal Artery-Stenosis

- Tardus parvus wave form in segmental renal arteries.
- Loss of early systolic acceleration
- Acceleration time (AT) delay > 0.05–0.08 sec increased
- **Reduced acceleration index (AI) [single most sensitive screening parameter]**
- Reduced resistive index (RI) and pulsatility index (PI)

Painful Hematuria

- Stone (MC)
 - X-ray—KUB—Ist baseline investigation
 - NCCT – IOC
 - USG – Initial IOC

Painless Hematuria

- Malignancy
 - USG—initial baseline Investigation
 - IVU—Ist investigation
 - CECT (CT urography)—IOC

Child with UTI

- IVU and cystourethrography (first investigation)
- VCUG (voiding cystourethrography)-IOC for VUR

Obstructive Uropathy in Pregnant and Children

- MR urography is preferred over IVU
IOC for pretransplant workup → angiography (MDCT > conventional)

Renal Papillary Necrosis

- Analgesic (acute)
- DM, dehydration, diarrhea
- Shock
- Obstruction
- Sickle cell disease
- Alcohol
- Coagulopathy
- Trauma
- TB

- RVT
- Rejection

Imaging features:

- **Ring-shaped calcification in sloughed papilla (X-ray)**
- IVP (best)
 - Ball/egg in cup
 - **Signet ring**
 - **Ring shadow**
 - **Club shaped/saccular calyx**
 - **Lobster claw sign**
 - **Filling defects in PCS**
 - ↓ **Density of contrast material in nephrogram**
 - Amputated calyx and formation of cavities

Acute Pyelonephritis

- Global/focal renal enlargement (IVU)
- Striated nephrogram (CT)
- Sloughed papilla/fungal ball (CT)

USG

- Focal/diffuse enlargement with hypoechogenicity
- Focal areas of hypoperfusion
- Perinephric fluid
- IOC in pregnant/pediatric patients

FEMALE PELVIS

MR imaging has become a valuable modality in the evaluation of the female pelvis. In many cases, it follows the performance of HSG or US. These cases include infertility and pelvic pain.

- Test of choice for local staging of cervical cancer and the evaluation of pain or disability in the pregnant patient.
- In the evaluation of advanced gynecologic cancers, it is usually a secondary choice with CT preferred.

Cervical incompetence

- USG is currently the **investigation of choice** for diagnosing cervical incompetence during pregnancy.
- The cervical length in normal pregnancy should measure more than 3 cm.

- The **width of the cervical canal is by far the most reliable parameter to predict cervical incompetence** and should measure less than 2 cm in the second trimester.
- If bulging of membranes into the cervical canal is seen, the prognosis is unfavorable.
- US criteria for diagnosing cervical incompetence have not been established in the nongravid patient.
- **MRI offers the potential to diagnose cervical incompetence in the nonpregnant as well as the pregnant patient.**

MRI Findings

- Shortening of the endocervical canal (less than 3 cm)
- Widening of the internal cervical os (greater than 4 mm)
- Asymmetric widening of the endocervical canal
- Thinning or absence of the low signal intensity cervical stroma.

Adenomyosis of Uterus

TVS

- Poorly defined hypoechoic myometrium
- Heterogenous myometrial echotexture
- Asymmetrically thickened myometrial wall
- Poor definition of endomyometrial junction
- Scattered small (<5 mm) myometrial cysts.

MRI

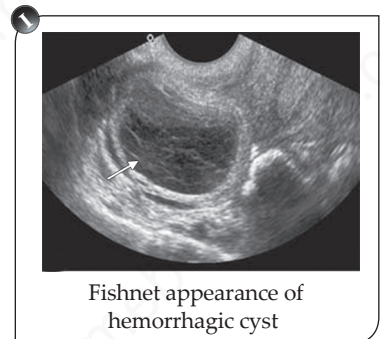
- Ill defined poorly marginated low signal intensity area
- Thickened endomyometrial junction >12 mm
- Multiple scattered small T2W hyperintense cysts.

Corpus Luteal Cysts

- Thickened hyperechoic (due to higher fat) crenulated wall showing increased peripheral vascularity on color Doppler.

Hemorrhagic Cyst

- **Fish net appearance of the cysts on USG**
- **Hyperintense signal on both T1W and T2w images**



Fishnet appearance of hemorrhagic cyst

Endometrial Cysts

- T1W hyperintense signal which shows shading on T2W images.

Polycystic Ovarian Disease

- Bilateral ovarian enlargement with multiple (10 or more) peripherally arranged small cysts (2–8 mm) giving string of pearls appearance on TVS/MRI

Hydrosalpinx

- Dilated tube with incomplete septae
- Cogwheel sign
- Beads on a string sign

Ovarian Torsion

- **USG with Doppler** – initial investigation of choice
- Unilateral ovarian enlargement
- Edematous ovary with multiple small cystic structures at the periphery
- Small amount of fluid in pouch of douglas
- Ovary has a dual blood supply and torsion can lead partial loss of blood flow with absent systolic spike/peak
- Arterial flow may be present in non viable ovaries but absent venous flow may be sensitive of non viability.

ANC

1st trimester scan- for

- Confirmation of pregnancy
- Intra uterine or extrauterine (ectopic)
- No of pregnancies
- Estimation of gestation age
- Adnexal/uterine pathologies
- Viability of fetus

TVS is the method of choice; more accurate and sensitive than transabdominal scan due to use of higher frequency probe.

Crown rump length is the most accurate single parameter for the assessment of gestational age in first trimester.

Earliest congenital anomaly to be detected on ANC USG- Anencephaly (8–10 weeks)- absent ossification of frontal bone.

Exencephaly- brain outside skull (14 weeks)

Routine use of Doppler is avoided although used to assess foetal or maternal complications like ectopic pregnancy and IUGR.

- **Ectopic pregnancy**

Failure to double the level of β -HCG in 48 hours and lower levels of β -HCG as compared to gestational age.

| | TVS | TAS |
|--------|---------|---------|
| G. Sac | 4 + wks | 5 + wks |
| CA | 5 + wks | 6 + wks |

USG Features of Ectopic Pregnancy

- Erogenous/complex adnexal mass representing ectopic gestational sac or hematoma separate from the ovary (**Most common finding**)
- Doppler shows a ring of fire due to high velocity, low impedance flow compatible with placental flow
- **Tubal ring- extrauterine G sac with trophoblastic tissue**
- Free fluid in pouch of Douglas
- **Doughnut/bagel sign- hyperechoic rim surrounding the gestational sac**
- **Pseudo sac** in the endometrial cavity containing fluid and echogenic areas
- Decidual reaction in the endometrial cavity.

2nd Trimester Scan/Anomaly Scan- 18–20 Weeks

- For gross congenital anomalies and structural/anatomical defects and placental localization
- BPD is most accurate single parameter however multiple parameter assessment is the best and most accurate for dating in 2–3rd trimester.

IUGR (Intrauterine Growth Retardation)

- Doppler is IOC to assess IUGR
- Early diastolic notching is abnormal after 22 weeks of gestation with gradual reduction in diastolic flow with S/D (systolic/diastolic) ration > 3 suggests IUGR [Normal is < 2.5]
- Absent diastolic flow is associated with high mortality rate

- Reversal of diastolic flow is associated with worst fetal outcome
- Increased diastolic flow or reduced S/D ratio of cerebral arteries is an indicator of brain sparing IUGR.

Imaging of Male Genital System

Scrotum

Epididymitis- orchitis

- Prehan sign- pain relieved when testes are elevated over pubic symphysis
- USG with Doppler- IOC
- Enlarged hypoechoic epididymis/testis (hyperechoic if hemorrhage)
- Indirect signs of inflammation like- reactive hydrocoele or pyocele, scrotal wall thickening
- Increased number and concentration of identifiable vessels with high flow
- Reversal of flow in diastole is suggestive of venous infarction.

Testicular Torsion

- Anomalous suspension of testis by a long stalk of spermatic cord (Bell and clapper phenomenon)
- USG- first investigation with Doppler being IOC
- May be normal if done immediately
- Testicular swelling and decreased echogenicity – most common findings at 4–6 hours duration
- Heterogenous echotexture due to hemorrhage and infarction
- Reduced or absent blood flow on Doppler.
- Presence of color or power Doppler in a patient with clinical manifestations – does not exclude torsion
- Torsion of appendix testis- blue dot sign through overlying skin.

Carcinoma Prostate

- Location: Peripheral zone 70%, transition zone 20% and central 10%.
- Most important factor affecting **prognosis/choice** of treatment is **presence or absence of extracapsular extension**.
- **TRUS is most widely used imaging modality for local staging.**

- **Small prostatic cancer usually appears hypoechoic because of closely packed cells.**
- **Secondary signs like glandular asymmetry and capsular bulging.**
- 3D MR spectroscopy (increased choline and decreased citrate levels) + Endorectal MR imaging increase accuracy in detecting and staging of local and extracapsular extension of prostate carcinoma.
- Pathologically: adults (adenocarcinoma); Children (rhabdomyosarcoma)

Classic Imaging Appearance

- **TRUS is most frequently used to assess the primary tumor, but no consistent finding predicts cancer with certainty.**
- **TRUS is used primarily to direct prostate biopsies.**
- Computed tomography (CT) scans lack sensitivity and specificity to detect extraprostatic extension and are inferior to magnetic resonance imaging (MRI) in visualization of lymph nodes.
- **T2WI:** Decrease signal in a normally high signal peripheral zone.

MRI is IOC for Preoperative Staging of Prostatic Cancer

- MRI specificity is improved with an endorectal coil and aids in planning radiation therapy. T1-weighted images demonstrate the periprostatic fat, periprostatic venous plexus, perivesicular tissues, lymph nodes, and bone marrow. -T2-weighted images demonstrate the internal architecture of the prostate and seminal vesicles.
- MR spectroscopy is also helpful in identification of malignancy identified by loss of citrate peak seen in normal gland and identification of choline peak.
- Radionuclide bone scans are used to evaluate spread to osseous sites.

Spermatic Venography is usefully employed in location of undescended testis if this is not identified using cross-sectional imaging. Now for a young man with primary infertility, low volume, fructose negative ejaculate, pathology is most likely to be in seminal vesicles, ejaculatory duct or vas.

Transrectal Ultrasonography (TRUS) is an excellent technique for demonstrating seminal vesicle anatomy and finding ejaculatory duct pathologies.

QUESTIONS

1. Which of the following is not seen on ultrasound in acute pyelonephritis?
 - a. Grossly enlarged kidney
 - b. Focal area of hypoechogenicity
 - c. Perinephric collection (pus in the perinephric space)
 - d. Increased vascularity
2. On contrast radiography, which among the following is false:
 - a. Ileum is featureless
 - b. Colon has haustrations
 - c. Jejunum is feathery
 - d. Distal part of duodenum has a cap
3. Central dot sign is seen in:
 - a. Primary sclerosing cholangitis
 - b. Liver hamartoma
 - c. Caroli's disease
 - d. Polycystic liver disease
4. The radiological procedure for studying vesico-ureteric reflux is:
 - a. Ascending pyelogram
 - b. Cystogram
 - c. Intravenous pyelogram
 - d. Micturating cystourethrogram
5. Which of the following is true regarding the principle of use of MRCP?
 - a. Intraluminal dye is used to create the three-dimensional view of the structures
 - b. Dye is instilled percutaneously first-then MRI is used
 - c. Use of heavily T2-weighted image without contrast to create the three-dimensional image of the biliary tree using MIP algorithm
 - d. Use of systemic gadolinium as a contrast agent to create the three-dimensional image of the biliary tree
6. Micturating cystourethrography is used in the diagnosis of:
 - a. Vesicoureteric reflex and posterior urethral valve
 - b. Rupture urethra
 - c. Stricture urethra
 - d. Ca of the bladder
7. Investigation of choice in small renal calculi:
 - a. Low dose non-enhanced CT
 - b. High dose non-enhanced CT
 - c. Low dose enhanced CT
 - d. High dose enhanced CT
8. Distribution of functional renal tissue is seen by:
 - a. Dimercaptosuccinic acid (DMSA)
 - b. Diethylene triamine penta-acetic acid (DTPA)
 - c. Mercaptoacetyl triglycine 3 (MAG3) - Tc99
 - d. I 123 iodocholesterol
9. On X-ray, small bowel can be differentiated by large bowel by having:
 - a. String of beads sign
 - b. Haustrations
 - c. Peripherally placed concave coil of intestine
 - d. Air fluid level
 - e. Valvulae conniventes
10. Renal agent used for assessing cortical scarring:
 - a. TC-99 m DTPA
 - b. TC-99 m DMSA
 - c. TC-99 m Glucohepatanate
 - d. 1-131- Hippuran
11. For suspected ureteric calculus, the modality of choice is:
 - a. Noncontrast CT
 - b. Ultrasonography
 - c. X-ray KUB
 - d. Cystoscopy

12. Which one of the following imaging modalities strive for evaluation of extra-adrenal pheochromocytoma:
 - a. Ultrasound
 - b. CT
 - c. MRI
 - d. MIBG scan
13. For renal stone, diagnosis is not done by:
 - a. IVP
 - b. MRI
 - c. PET-scan
 - d. CT-scan
14. Of the following imaging modality is most sensitive investigation of choice) to detect early renal tuberculosis:
 - a. Intravenous urography
 - b. Ultrasound
 - c. Computed tomography
 - d. Magnetic resonance imaging
15. Posterior urethra is best visualized by:
 - a. Static cystogram
 - b. Retrograde urethrogram
 - c. Voiding cystogram
 - d. Cr cystogram
16. Radiation exposure is least in the following procedure:
 - a. Micturating cystourethrogram
 - b. IVP
 - c. Bilateral nephrostogram
 - d. Spiral CT for stones
17. All of the following form radiolucent stones except:
 - a. Xanthine
 - b. Cysteine
 - c. Indinavir associated stones
 - d. Allopurinol associated stones
18. Most sensitive and specific investigation for diagnosis of renovascular hypertension:
 - a. MRI
 - b. Captopril-enhanced radionuclide scan
 - c. Spiral CT angiography
 - d. Catheter angiography
19. Abdominal ultrasonography in a 3-year-old boy shows a solid circumscribed hypoechoic renal mass. Most likely diagnosis is:
 - a. Wilms' tumor
 - b. Renal cell carcinoma
 - c. Mesoblastic nephroma
 - d. Oncocytoma
20. Which of the following is not an appropriate investigation for anterior urethral stricture:
 - a. Magnetic resonance imaging
 - b. Retrograde urethrogram
 - c. Micturating cystourethrogram
 - d. High-frequency ultrasound
21. Transrectal ultrasonography in carcinoma prostate is most useful for:
 - a. Guided prostatic biopsies
 - b. Seminal vesicle involvement
 - c. Measurement of prostatic volume
 - d. To detect hypoechoic area
22. Papillary necrosis features are all except:
 - a. Egg in cup
 - b. Hyperdense nephrogram
 - c. Calyceal horns
 - d. Ring shadows
23. The most important sign of significance of renal artery stenosis on an angiogram is:
 - a. A percentage diameter stenosis >70%
 - b. Presence of collaterals
 - c. Stenosis > 50%
 - d. Thrombosed renal artery
24. Dense persistent renogram is obtained by:
 - a. Dehydrating the patient
 - b. Increasing the dose of contrast media
 - c. Rapid (bolus) injection of dye
 - d. Using nonionic media

25. Investigation of choice in diffuse esophageal spasm is:
- Manometry
 - Esophagoscopy
 - Barium examination showing tertiary contractions
 - CT thorax
26. Double bubble sign with air shadows absent in distal bowel coils on X-ray abdomen is characteristic of:
- Duodenal webs
 - Duodenal atresia
 - GIPH
 - Ileal atresia
27. Carman's meniscus sign is diagnostic of:
- Peptic ulcer
 - Cholecystitis
 - Meconium ileus
 - Carcinoma of stomach
28. Trifoliate appearance is in:
- Peptic ulcer
 - Pyloric stenosis
 - Carcinoma head of pancreas
 - Periampullary carcinoma
29. X-ray feature of pyloric stenosis is:
- Single bubble appearance
 - Double bubble appearance
 - Triple bubble appearance
 - Multiple air fluid levels
30. String sign is seen in:
- Crohn's disease
 - TB of the ileocaecal region
 - Idiopathic hypertrophic pyloric stenosis
 - All of the above
31. "Coffee bean" sign is seen in:
- Intussusception
 - Bowel ischemia
 - Sigmoid volvulus
 - Congenital hypertrophic pyloric stenosis
32. Triad of vomiting, abdominal distension and string of beads sign on abdominal X-ray is typically suggestive of:
- Duodenal atresia
 - Small bowel obstruction
 - Large bowel obstruction
 - Gastric volvulus
33. String sign of Kantor is seen in:
- Crohn's disease
 - Ulcerative colitis
 - TB
 - Carcinoma
34. Ileocecal tuberculosis presents with all except:
- Rapid emptying of narrowed terminal ileum
 - Inverted umbrella sign
 - Stellate ulcer with elevated margins
 - Longitudinal ulcers are more common.
35. Following are common features of malignant gastric ulcer on barium meal, except:
- Location on the greater curvature
 - Carman's meniscus sign
 - Radiating folds which do not reach the edge of the ulcer
 - Lesser curvature ulcer with a nodular rim
36. Findings of pyloric stenosis on USG are all except:
- Accuracy 95%
 - High gastric-residue
 - Segment length > 16 mm
 - Thickness of muscle wall > 4 mm
37. A newborn presenting with intestinal obstruction showed on X-ray multiple air fluid levels are seen. The diagnosis is most likely to be:
- Pyloric obstruction
 - Duodenal atresia
 - Ileal atresia
 - Ladd's bands

38. The following are radiological features of sigmoid volvulus except:
- Inverted U-shaped bowel loop
 - Liver overlap sign
 - Bird of prey
 - Cupola sign
39. Radiological signs of Crohn's disease:
- String sign of Kantor
 - Pipestem colon
 - Pseudopolyp
 - Backwash ileitis
40. Lead pipe appearance is seen in:
- Crohn's disease
 - Ulcerative colitis
 - Schistosomiasis
 - Carcinoma colon
41. All of the following are diagnostic barium follow-through features of ileocecal tuberculosis except:
- Apple-core appearance
 - Pulled up contracted cecum
 - Widening of ileocecal angle
 - Strictures involving terminal ileum
42. Following are features of ischemic colitis except:
- Thumb printing
 - Serrated mucosa
 - Increased mucosal fold thickness
 - Dilution of barium
43. The best view to visualize minimum pneumoperitoneum is:
- AP view of abdomen
 - Erect film of abdomen
 - Rt lateral decubitus with horizontal beam
 - Lt lateral decubitus with horizontal beam
44. In case of suspected perforation which view is the best:
- Erect
 - Supine
 - Lateral decubitus
 - None
45. Radiological feature of ischemic colitis is:
- Saw-toothing
 - Craggy popcorn appearance
 - Thumb printing
 - Corkscrew appearance
46. Feathery appearance in jejunum is due to:
- Valvulae conniventes
 - Haustrations
 - Luminal gas
 - Vascular network
47. Which among the following is false regarding small bowel appearance on abdominal radiograph?
- Valvulae conniventes are present
 - Peripheral distribution
 - Radius of curvature is small
 - Solid faces are absent
48. Small intestine in intestinal obstruction is distinguished radiologically from large intestine by:
- Haustration
 - Valvulae conniventes
 - Can not be distinguished
 - None
49. Soap bubble appearance in X-ray is seen in:
- Multiple cystic kidney
 - Neuroblastoma
 - Cystic lymphangiectasis
 - Meconium ileus
50. Which among the following is false regarding need of Supine chest radiograph in the abdominal pathology:
- For showing presence of a small pneumoperitoneum
 - A number of chest conditions can present as acute abdominal condition
 - Acute abdominal condition may be complicated by the chest pathology
 - Even when the chest radiograph is normal, it acts as a most valuable baseline.

51. Free gas in abdomen (under the diaphragm) can be best diagnosed by which X-ray?
- Standing
 - Right lateral recumbent view
 - Left lateral recumbent view
 - Sitting position
52. Cupola sign:
- Radiological finding in supine posture for pneumoperitoneum
 - Radiological finding in supine posture for pneumothorax
 - Air in Morrison's pouch
 - Both walls of bowel is seen
53. Typical "saw-tooth" colon on barium enema is seen with:
- Colonic diverticulosis
 - Colonic volvulus
 - Colonic carcinoma
 - Ulcerative colitis
54. Chain-of-lake appearance ERCP is seen in:
- Acute pancreatitis
 - Chronic pancreatitis
 - Carcinoma pancreas
 - Ductal adenoma
55. Solitary hypoechoic lesion of the liver without septate or debris is most likely to be:
- Hydatid cyst
 - Caroli's disease
 - Liver abscess
 - Simple cyst
56. "Hat sign" on double contrast barium enema is seen in:
- Ulcer
 - Polyp
 - Carcinoma
 - Diverticulum
57. Couinaud's segments are used to divide which organ:
- Liver
 - Lung
 - Spleen
 - Kidney
58. A 22-year-old man presents with a solitary 2 cm space-occupying lesion of mixed echogenicity in the right lobe of liver on ultrasound examination. The rest of the liver is normal. Which of the following tests should be done next?
- Ultrasound-guided biopsy of the lesion
 - Hepatic scintigraphy
 - Hepatic angiography
 - Contrast-enhanced CT scan of the liver
59. Which one of the following hepatic lesions can be diagnosed with high accuracy by using nuclear imaging?
- Hepatocellular carcinoma
 - Hepatic adenoma
 - Focal nodular hyperplasia
 - Cholangiocarcinoma
60. CT findings of acute pancreatitis are all except:
- Dilation of pancreatic duct
 - Fuzzy outline of pancreas
 - Peripancreatic fluid collection
 - Edematous pancreas
61. According to Couinaud's classification of functional segments of liver, which of the following is segment IV of liver?
- Left lobe
 - Right lobe
 - Caudate lobe
 - Quadrant lobe
62. Radiological signs of acute pancreatitis include the following except:
- Colon cut-off sign
 - Cullen's sign
 - Renal halo sign
 - Sentinel loop sign
63. CT findings of acute pancreatitis are:
- Fuzzy outline of pancreas
 - USG has replaced it
 - Dye used is telepaque
 - All of the above

64. **Colon cut-off sign is seen in:**
- Acute pancreatitis
 - Diverticulitis
 - Appendicitis
 - Carcinoma colon
65. **Widening of the C loop in X-ray is diagnostic of:**
- Chronic pancreatitis
 - Carcinoma head of pancreas
 - Periampullary carcinoma
 - Calculi in the ampulla of Vater
66. **ERCP in pancreatitis is done to know about:**
- CBO stones
 - Associated cholangitis
 - Ascites
 - Pancreatic divisum
 - Annular pancreas
67. **“Spongy appearance” with central sunburst calcification is seen in:**
- Pancreatic adenocarcinoma
 - Mucinous cyst adenocarcinomas
 - Somatostatinoma
 - Serous cystadenoma
68. **Most sensitive investigation for pancreatic carcinoma is:**
- Angiography
 - ERCP
 - Ultrasound
 - CT scan
69. **Investigation of choice for small intestine tumor:**
- Ba followthrough
 - Echo
 - X-ray abdomen
 - CT scan with contrast
70. **Contrast used in barium enema is:**
- Barium oxide
 - Barium sulfide
 - Barium sulfate
 - Lead sulfate
71. **A patient complains of epigastric pain, radiating to back off and on. The investigation of choice is:**
- MRI
 - CT scan
 - USG
 - Radionucleotide scan
72. **Investigation of choice for gallstone:**
- X-ray
 - USG
 - Cholecystography
 - CT scan
73. **The investigation of choice for acute cholecystitis is:**
- USG
 - HIDA-scan
 - CT-scan
 - X-ray
74. **Which is not required for visualization of gallbladder in oral cholecystography?**
- Functioning liver
 - Motor mechanisms of gallbladder
 - Patency of cystic duct
 - Ability to absorb water
75. **Investigation of choice in obstructive jaundice is:**
- ERCP
 - USG
 - Cholecystography
 - Laparoscopy
76. **Minimal ascites can be best detected by:**
- USG
 - Plain X-ray abdomen
 - MRI
 - CT scan
77. **Most common investigation done for obstructive jaundice:**
- CT scan
 - USG
 - X-ray
 - ERCP
78. **Focal and diffuse thickening of gallbladder wall with high amplitude reflections and ‘comet tail’ artifacts on USG suggest the diagnosis of:**
- Xanthogranulomatous cholecystitis
 - Carcinoma of gallbladder
 - Adenomyomatosis
 - Cholesterosis

79. Which of the following is not a diagnostic feature of gallstone ileus in plain abdominal radiograph?
- Ectopic calcified gallstone
 - Stone < 2.5 cm size in the intestine
 - Signs of small intestinal obstruction
 - Gas in the biliary tree
80. Air in biliary tract is seen in all except:
- Gallstone ileus
 - Sclerosing cholangitis
 - Carcinoma gallbladder
 - Endoscopic papillotomy
81. Computed Tomography (CT scan) is least accurate for diagnosis of:
- Aneurysm in the hepatic artery
 - Lymph node in the para-aortic region
 - Mass in the tail of pancreas
 - Gallstones
82. Investigation of choice for recurrent GIST:
- MIBG
 - PET CT
 - MRI
 - CECT
83. Technetium-99 scan is used for diagnosis of:
- Meckel's diverticulum
 - Appendix
 - Volvulus
 - Obstruction
84. Best imaging modality for neuroendocrinal tumors:
- PET
 - CECT
 - Radionucleotide scan
 - MRI with gadolinium scan
85. Protein-losing enteropathy diagnosis, all used except?
- Tc albumin
 - Tc dextran
 - In transferrin
 - Tc seclousumab
86. A dense persistent nephrogram may be seen in all of the following except:
- Acute ureteral obstruction
 - Systemic hypertension
 - Severe hydronephrosis
 - Dehydration
87. Calcific hepatic metastases are seen in:
- Adenocarcinoma of the colon
 - Carcinoid tumors
 - Renal cell carcinoma
 - Lymphoma
88. For the evaluation of blunt abdominal trauma, which of the following imaging modalities is ideal?
- Ultrasonography
 - Computed tomography
 - IVP
 - MRI
89. USG is sensitive in:
- Ureteric colic
 - Gallstone
 - Appendicitis
 - Pancreatic pathology
90. Investigation of choice for diagnosis of splenic rupture:
- Peritoneal lavage
 - Ultrasound
 - CT scan
 - MRI
91. Which of the following agents is used to measure glomerular filtration rate (GFR):
- Iodohippurate
 - Tc99m-DTPA
 - Tc99m-MAG3
 - Tc99m-DMSA
92. The investigation of choice for Renal Scarring defect in kidney is:
- Tc99 DMSA scan
 - DTPA scan
 - DEXA scan
 - MCU

93. A patient presents with acute renal failure and anuria. The USG is normal. Which of the following investigations will give the best information regarding renal function:
- Intravenous pyelogram
 - Retrograde pyelography
 - Antegrade pyelography
 - DTPA scan
94. A patient presented with ARF with complete anuria but a normal ultrasound. Next investigation is:
- IVP
 - Antegrade pyelography
 - Retrograde pyelography
 - Radiorenogram
95. A dense renogram is obtained by:
- Dehydrating the patient
 - Increasing the dose of contrast media
 - Rapid (Bolus) injection of dye
 - Using nonionic media
96. Nonvisualization of kidney in excretory urogram is seen in:
- Duplication
 - Renal vein thrombosis
 - Hydronephrosis
 - Hypoplasia
97. 'Stipple sign' in transitional cell carcinoma of the renal collecting system is best demonstrated by:
- Intravenous urography
 - Retrograde pyeloureterography
 - Radionuclide scan
 - Ultrasound scan
98. "Adder-head" appearance on voiding cystourethrogram in bladder is feature of:
- Horse-shoe kidney
 - VUR
 - Ureterocele
 - Carcinoma of bladder
99. Cobra head deformity is characteristic of:
- Posterior urethral valve
 - Ureterocele
 - Bladder tumor
 - Cystitis
100. IVP is contraindicated in:
- Multiple myeloma
 - Kidney stones
 - Renal cyst
 - Transplanted kidney
101. Screening of renovascular hypertension is done by:
- MRI
 - Captopril-enhanced radionuclide scan
 - Spiral CT scan
 - Duplex-Doppler flow study
102. The investigation of choice for imaging of urinary tract tuberculosis is:
- Plain X-ray
 - Intravenousurography
 - Ultrasound
 - Computed tomography
103. Spider leg appearance is found in:
- Polycystic kidney
 - Pyelonephritis
 - Hydronephrosis
 - Renal artery stenosis
104. Tear-drop bladder is seen in:
- Pelvic abscess
 - Pelvic lipomatosis
 - Bladder rupture
 - All of the above
105. Renal tuberculosis can be diagnosed earliest by:
- CTscan
 - IVP
 - Angiography
 - USG

106. **Hypoechoic lesion within prostate in USG is seen in:**
- Adenocarcinoma
 - Normal prostate tissue
 - Infertility
 - Urethral obstruction
 - BPH
107. **Most accurate assessment of gestational age by USG is done by:**
- Femur length
 - Gestational sac size
 - Menstrual history
 - Crown rump length
108. **Molar pregnancy can be best diagnosed by:**
- Clinical history and examination
 - Ultrasound study
 - Laparoscopy
 - CT Scan
109. **USG can detect gestation sac earliest at:**
- 5–6 weeks of gestation
 - 7–8 weeks of gestation
 - 10 weeks of gestation
 - 12 weeks of gestation
110. **The investigation of choice for an ectopic pregnancy is:**
- CT scan
 - Transvaginal USG
 - Serum hCG levels
 - Crown rump length
111. **Earliest sign of fetal life is best detected by:**
- X-ray
 - Fetoscopy
 - Real time USG
 - Doppler
112. **Parameters used to estimate gestational age in last TM:**
- CR length
 - Abdominal circumference suggestive of
 - BPD
 - Femur length
113. **In second trimester of pregnancy, the diagnosis of IUGR can be best made of by assessing which of the following parameters:**
- HC
 - AC
 - CRL
 - BPD
114. **Which of the following congenital malformations of the fetus can be diagnosed in first trimester by ultrasound?**
- Anencephaly
 - Inencephaly
 - Microcephaly
 - Holoprosencephaly
115. **Anencephaly can be diagnosed by USG at:**
- 10–12 weeks of gestation
 - 14–18 weeks of gestation
 - 20–24 weeks of gestation
 - 24–28 weeks of gestation
116. **Ultrasonography of umbilical artery is done to know about:**
- Heartbeat
 - Gestational age
 - Fetal weight
 - Fetal maturity/growth
117. **True about antenatal Doppler analysis is all except:**
- Reduction in end diastolic flow is associated with poor outcome
 - Reduction of EDF is associated with IUGR
 - In normal gestation placental resistance is high
 - S/D ratio is high in IUGR
 - Investigation of choice in pregnancy
118. **USG done at 18–20 weeks mainly to:**
- Detect fetal abnormality
 - Determine sex
 - Estimate liquor
 - Determine maturity

119. All are signs/features of ectopic pregnancy on USG except:
- Pseudosac
 - Hyperechoic rim
 - Adnexal mass
 - Echogenic mass with multicystic spaces within endometrial cavity
120. Ectopic pregnancy, characteristic finding in USG is:
- Absence of gestational sac in uterus
 - Complex adnexal mass
 - Resistance in color Doppler
 - Free fluid in peritoneal cavity
121. USG can diagnose all except:
- Anencephaly
 - Neural tube defect
 - Placenta previa
 - Down's syndrome
122. On USG, finding of cystic hygroma in fetus is suggestive of:
- Down's syndrome
 - Marphan's syndrome
 - Turner's syndrome
 - Klinefelter's syndrome
123. Mammographic abnormality seen in CA breast is:
- Change in density
 - Clusters of microcalcification
 - Change in architecture
 - All of the above
124. Hallmark of breast malignancy on mammography:
- Low-density lesion
 - Smooth margin
 - Clusters of microcalcification
 - Popcorn calcification
125. Which of the following features on mammogram would suggest malignancy:
- Well defined lesion
 - A mass of decreased density
 - Areas of spiculated microcalcifications
 - Smooth borders
126. The sensitivity of mammography is low in young females because of:
- Less glandular tissue and more fat
 - Young females are less cooperative
 - Young breast have dense tissue
 - Because of less fat content
127. On mammography following are the features of a malignant tumor except:
- Spiculation
 - Microcalcification
 - Macrocalcification
 - Irregular mass
128. Which of the following does not contain fat on mammography?
- Post-traumatic cyst
 - Hamartoma
 - Seborrheic keratosis
 - Galactocele
129. Investigation to diagnose stage-I carcinoma breast:
- Bilateral mammogram
 - X-ray chest
 - Bone scan
 - CT scan
130. The most sensitive investigation for DCIS (ductal carcinoma in situ) of breast?
- Mammography
 - Ultrasound
 - MRI
 - PET scan
131. Triple assessment for carcinoma breast includes:
- History, clinical examination, biopsy/cytology
 - Clinical examination, mammography, biopsy/cytology
 - History, clinical examination, ultrasonography
 - Observation, ultrasonography, biopsy/cytology

132. Mammograph can be used in:
- Early breast carcinoma
 - Mastitis
 - Fibroadenoma
 - Phyllodes tumor
133. What is least useful as diagnostic procedure in case of acute hematemesis:
- Barium meal
 - Endoscopy
 - Gastric content aspiration
 - Angiography
134. Following are common features of malignant gastric ulcer on Barium meal except:
- Location on the greater curvature
 - Carman's meniscus sign
 - Radiating folds which do not reach the edge of the ulcer
 - Lesser curvature ulcer with a nodular rim
135. After taking a drug, a patient developed some abdominal problem for which he consulted a physician, who advised X-ray. X-ray finding was radiopacity in bowel. Probably he might have taken A/E:
- Salicylate
 - Iron
 - Phenothiazine
 - Corticosteroid
136. Gasless abdomen is a feature of:
- High obstruction
 - Acute pancreatitis
 - Congenital diaphragmatic hernia
 - All of above
137. Widening of C loop of duodenum is a feature of:
- Pancreatic head growth
 - Carcinoma stomach
 - Splenic involvement
 - Involvement of upper right renal pole
138. X-ray appearance of CBD stone on cholangiography is:
- Meniscus appearance
 - Sudden cut-off
 - Smooth tapering
 - Eccentric occlusion
139. A newborn baby has not passed meconium for 48 hours since birth. She has vomiting and distension of abdomen. The most appropriate investigation for evaluation would be:
- Anorectal manometry
 - Rectal biopsy
 - Lower GI contrast study
 - Trypsin estimation
140. Papillary necrosis features are all except:
- Egg in cup
 - Hyperdense nephrogram
 - Calyceal horns
 - Ring shadows
141. Which of the following regarding antenatal assessments of umbilical arteries by color Doppler study is TRUE?
- There is decreased S/D ratio in smoker and nicotine-abusing pregnant females
 - The reduced diastolic flow at term indicates good prognosis
 - The flow velocities and the S/D ratio are useful to evaluate high-risk pregnancies
 - In otherwise normal pregnancies the increased S/D ratio is normal in smoking females
142. Best for unruptured ectopic pregnancy is:
- Per abdominal US
 - hCG
 - Transvaginal US
 - Amniocentesis

143. **Most accurate assessment of gestational age by USG is done by:**
- Femur length
 - Gestational sac size
 - Menstrual history
 - Crown rump length
144. **The method to diagnose misplaced intrauterine device is:**
- Ultrasound
 - X-ray abdomen (Erect view)
 - Uterine sound and hysteroscopy
 - All of the above
145. **Maximum radio-opaque shadow in ovary is seen in:**
- Teratoma
 - Dysgerminoma
 - Mucinous cystadenoma
 - Granulosa cell tumor
146. **Missed IUD (IUCD) is recognized by:**
- X-ray
 - USG
 - Barium meal
 - CT Scan
147. **Radiological investigation of female of reproductive age group is restricted to:**
- Menstrual period
 - First 10 days of menstrual cycle
 - 10–20 days of menstrual cycle
 - Last 10 days of menstrual cycle
148. **Radiological findings of battered baby syndrome is:**
- Multiple injuries not explained by one cause
 - Multiple fractures in different stage of healing
 - Excessive callus formation
 - All of the above
149. **In renal cell carcinoma, investigation of choice to evaluate inferior vena cava and renal vein for thrombus:**
- IVP
 - Color Doppler
 - USG
 - CT scan
150. **Which of the following is the most preferred route to perform cerebral angiography?**
- Transfemoral route
 - Transaxillary route
 - Direct carotid puncture
 - Transbrachial route
151. **Calcification is best detected by:**
- X-ray
 - USG
 - CT scan
 - MRI
 - PET scan
152. **Functional analysis of kidney is best done by:**
- Radionuclide scanning
 - IVP
 - Ultrasound
 - MRI
153. **Investigation of choice in obstructive jaundice is:**
- ERCP
 - USG
 - Cholecystography
 - Laparoscopy
154. **Gastro-esophageal reflux is best detected by:**
- Endoscopy
 - USG
 - Barium study
 - Isotope scan
155. **Neural tube defect is best detected by:**
- USG
 - Chromosomal analysis
 - Amniocentesis
 - Placentography
156. **Investigation of choice for Zenker's diverticulum is:**
- Barium swallow
 - Endoscopy
 - Esophageal manometry
 - CT

157. Which of the following is not a CT feature of Adrenal adenoma?
- Low attenuation
 - Homogenous density and well defined borders
 - Enhances rapidly, contrast stays in it for a relatively longer time and washes out late
 - Calcification is rare
158. Fir tree appearance of bladder is seen in:
- Schistosomiasis
 - Tuberculosis
 - Neurogenic bladder
 - Pelvic abscess
159. Investigation of choice for posterior urethral valve is:
- Micturition cystourethrogram
 - Retrograde urethrography
 - Ultrasound
 - IVP
160. Drooping Lilly sign is seen in:
- Duplication of ureters
 - Renal cyst
 - Hydatid cyst
 - Duplication of uterus
161. Earliest finding of renal tuberculosis on IVP is:
- Cortical scarring
 - Hydronephrosis
 - Cavitation
 - ill defined calyx
162. Most sensitive test to detect early renal TB is:
- Intravenous urography
 - CT
 - MRI
 - USG
163. Investigation of choice in choledocholithiasis:
- CT
 - PET scan
 - USG
 - HIDA scan
164. Invertogram to be done in a new born:
- Immediately
 - After 2 hours
 - After 4 hours
 - After 6 hour
165. On CT, Balthazar grading is for:
- Acute pancreatitis
 - Cholecystitis
 - Pancreatic carcinoma
 - Chronic pancreatitis
166. Endoscopic USG criteria for chronic pancreatitis, when the diameter of the main pancreatic duct is:
- >1 mm
 - 1.5 mm
 - >2 mm
 - >3 mm
167. Corkscrew oesophagus on barium swallow is seen in:
- Achalasia cardia
 - Diffuse oesophageal spasm
 - Carcinoma oesophagus
 - Gastroesophageal reflux
168. Colon cut off sign is seen in?
- Carcinoma colon
 - Pancreatitis
 - Sigmoid volvulus
 - Diverticulosis
169. Drug administered to increase diagnostic accuracy of HIDA scan in neonatal jaundice is?
- Pentagastrin
 - Phenobarbital
 - Morphine
 - Cholecystokinin
170. Apple core appearance is seen in:
- Carcinoma esophagus
 - Carcinoma colon
 - Sigmoid volumes
 - Diverticulosis
171. Chain of lakes appearance is seen in:
- Chronic pancreatitis
 - Acute pancreatitis

- c. Gall stone ileus
d. Subacute intestinal obstruction
- 172. Cork screw oesophagus seen in:**
a. Carcinoma oesophagus
b. Diffuse oesophageal spasm
c. Achalasia cardia
d. Hypertrophic pyloric stenosis
- 173. On DSA, typical 'string of beads' appearance of arteries is seen in:**
a. Takayasu's disease
b. Atherosclerotic stenosis
c. Fibromuscular dysplasia
d. Middle aortic syndrome
- 174. Pulled up cecum is seen in:**
a. Ileocecal TB
b. Carcinoma cecum
c. Intussusception
d. Carcinoma
- 175. Fetal cardiac activity can be detected earliest by USG at which age of intrauterine life:**
a. 1-2 weeks b. 2-4 weeks
c. 5-6 weeks d. 6-8 weeks
- 176. Gas shadow in heart and great vessels appears in:**
a. IUD
b. Abortion
c. Still birth
d. None of the above
- 177. Spalding sign is seen in:**
a. Abortion b. Still birth
c. IUD d. infanticide
- 178. T-sign is seen in:**
a. Genital TB
b. Membrane in twin pregnancy
c. Molar pregnancy
d. Septate uterus
- Multiple Correct Answers**
- 179. The chemical composition of renal calculi visualized on plain radiographs is:**
a. Calcium oxalate
b. Uric acid
c. Magnesium ammonium phosphate
d. Cysteine
- 180. Teardrop bladders are seen in:**
a. Pelvic hematoma
b. Pelvic lipomatosis
c. TB
d. Neurogenic bladder
e. Intraperitoneal bladder rupture
- 181. Investigations for small intestine include all except:**
a. Enteroclysis.
b. Radionuclide enteroclysis
c. MRI enteroclysis
d. CT enteroclysis
e. USG enteroclysis
- 182. True about features of cholecystitis on USG:**
a. Thick fibrosed gallbladder wall
b. Stone impacted at neck of gallbladder
c. Pericholecystic edema
d. Increased vascularity
e. Comet tail sign
- 183. Thickened gallbladder wall in USG is seen in:**
a. Acute cholecystitis
b. Mucosal thickening
c. Cholesterosis
d. Ascites
e. AIDS cholangitis
- 184. True about MRCP:**
a. MRI is used to obtain the image
b. CT is used for the images
c. It shows the biliary tree
d. Dye has to be injected endoscopically
e. It is an invasive procedure
- 185. Splenic injury is diagnosed on X-ray by:**
a. Half stomach shadow
b. Obliteration of splenic shadow
c. Rib fracture
d. Gas under diaphragm

186. In a CT scan at the level of celiac trunk, following structures will be seen:
- Pancreas
 - Gallbladder
 - Inferior vena cava
 - Duodenum
 - Portal vein
187. RHC calcification is seen in:
- Gallstone
 - Renal stone
 - Calcification of vessels
 - Hepatic hemangioma
 - Calcified costal cartilage
188. For renal stone, diagnosis is not done by:
- | | |
|-------------|--------|
| a. IVP | b. MRI |
| c. PET-Scan | d. USG |
| e. CT scan | |
189. IVP of polycystic kidney disease shows:
- Cobra head
 - Dropping lily
 - Flower base appearance
 - Spider leg deformity
 - Fish hook appearance
190. Diffuse esophageal dilatation on barium swallow is seen in:
- Achalasia
 - Trypanosomiasis
 - Etidronate therapy
 - Scleroderma
191. Radiological finding in ileal atresia:
- Microcolon on Ba enema
 - Double bubble sign
 - Coil spring appearance in Ba-Enema
 - Obstruction in Ba meal
 - Napkin ring stenosis
192. Investigation for small intestine includes all except:
- Enteroclysis
 - Radionuclide enteroclysis
 - MRI enteroclysis
 - CT enteroclysis
 - USG enteroclysis
193. Causes of bladder calcification are:
- Schistosomiasis
 - Urethral cell carcinoma
 - TB
 - Ureterocele
 - Cystitis

ANSWER KEYS

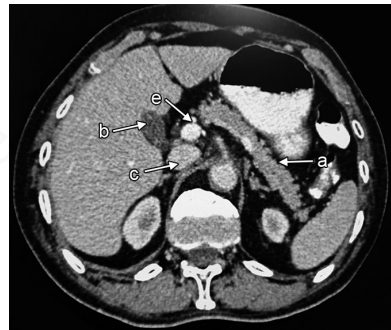
1. **Ans. d.** Increased vascularity
2. **Ans. d.** Distal part of duodenum has a cap
3. **Ans. c.** Caroli's disease
4. **Ans. d.** Micturating cystourethrogram
5. **Ans. c.** Use of heavily T2-weighted image without contrast to create the three-dimensional image of the biliary tree using MIP algorithm
6. **Ans. a.** Vesicoureteric reflex and posterior urethral valve
7. **Ans. a.** Low-dose nonenhanced CT
8. **Ans. a.** Dimercaptosuccinic acid (DMSA)
9. **Ans. e.** Valvulae conniventes
10. **Ans. b.** TC-99 m DMSA
11. **Ans. a.** Noncontrast CT
12. **Ans. d.** MIBG scan
13. **Ans. c.** PET-Scan
14. **Ans. a.** Intravenous urography
15. **Ans. c.** Voiding cystogram
16. **Ans. c.** Bilateral nephrostogram
17. **Ans. b.** Cysteine
18. **Ans. d.** Catheter angiography
19. **Ans. a.** Wilms' tumor
20. **Ans. a.** Magnetic resonance imaging
21. **Ans. a.** Guided prostatic biopsies
22. **Ans. b.** Hyperdense nephrogram
23. **Ans. b.** Presence of collaterals
24. **Ans. a.** Dehydrating the patient
25. **Ans. a.** Manometry
26. **Ans. b.** Duodenal atresia
27. **Ans. d.** Carcinoma of stomach
28. **Ans. a.** Peptic ulcer
29. **Ans. a.** Single bubble appearance
30. **Ans. d.** All of the above
31. **Ans. c.** Sigmoid volvulus
32. **Ans. b.** Small bowel obstruction
33. **Ans. a.** Crohn's disease
34. **Ans. c.** Stellate ulcer with elevated margins
35. **Ans. d.** Lesser curvature ulcer with a nodular rim
36. **Ans. b.** High gastric-residue
37. **Ans. c.** Ileal atresia
38. **Ans. d.** Cupola sign
39. **Ans. a.** String sign of Kantor
40. **Ans. b.** Ulcerative colitis
41. **Ans. a.** Apple-core appearance
42. **Ans. d.** Dilution of barium
43. **Ans. d.** Lt lateral decubitus with horizontal beam
44. **Ans. c.** Lateral decubitus
45. **Ans. c.** Thumb printing
46. **Ans. a.** Valvulae conniventes
47. **Ans. b.** Peripheral distribution
48. **Ans. b.** Valvulae conniventes
49. **Ans. d.** Meconium ileus
50. **Ans. a.** For showing presence of a small pneumoperitoneum
51. **Ans. c.** Left lateral recumbent view
52. **Ans. a.** Radiological finding in supine posture for pneumoperitoneum
53. **Ans. a.** Colonic diverticulosis
54. **Ans. b.** Chronic pancreatitis
55. **Ans. d.** Simple cyst
56. **Ans. b.** Polyp
57. **Ans. a.** Liver
58. **Ans. d.** Contrast-enhanced CT scan of the liver
59. **Ans. c.** Focal nodular hyperplasia
60. **Ans. a.** Dilation of pancreatic duct
61. **Ans. d.** Quadrate lobe
62. **Ans. b.** Cullen's sign
63. **Ans. a.** Fuzzy outline of pancreas
64. **Ans. a.** Acute pancreatitis
65. **Ans. b.** Carcinoma head of pancreas
66. **Ans. a.** CBO stones **d.** Pancreatic divisum and **e.** Annular pancreas

67. **Ans. d.** Serous cystadenoma
68. **Ans. d.** CT scan
69. **Ans. d.** CT scan with contrast
70. **Ans. c.** Barium sulfate
71. **Ans. b.** CT scan
72. **Ans. b.** USG
73. **Ans. a.** USG
74. **Ans. d.** Ability to absorb water
75. **Ans. a.** ERCP
76. **Ans. c.** MRI
77. **Ans. b.** USG
78. **Ans. c.** Adenomyomatosis
79. **Ans. b.** Stone < 2.5 cm size in the intestine
80. **Ans. b.** Sclerosing cholangitis
81. **Ans. d.** Gallstones
82. **Ans. b.** PET CT
83. **Ans. a.** Meckel's diverticulum
84. **Ans. a.** PET
85. **Ans. b.** Tc dextran
86. **Ans. c.** Severe hydronephrosis
87. **Ans. a.** Adenocarcinoma of colon
88. **Ans. b.** Computed tomography
89. **Ans. b.** Gallstone
90. **Ans. c.** CT scan
91. **Ans. b.** Tc99m-DTPA
92. **Ans. a.** Tc99 DMSA scan
93. **Ans. d.** DTPA scan
94. **Ans. a.** IVP
95. **Ans. a.** Dehydrating the patient
96. **Ans. d.** Hypoplasia
97. **Ans. a.** Intravenous urography
98. **Ans. c.** Ureterocele
99. **Ans. b.** Ureterocele
100. **Ans. a.** Multiple myeloma
101. **Ans. b.** Captopril-enhanced radionuclide scan
102. **Ans. b.** Intravenous urography
103. **Ans. a.** Polycystic kidney
104. **Ans. d.** All of the above
105. **Ans. b.** IVP
106. **Ans. a.** Adenocarcinoma
107. **Ans. d.** Crown rump length
108. **Ans. b.** Ultrasound study
109. **Ans. a.** 5–6 weeks of gestation
110. **Ans. b.** Transvaginal USG
111. **Ans. c.** Real time USG
112. **Ans. d.** Femur length
113. **Ans. b.** AC
114. **Ans. a.** Anencephaly
115. **Ans. a.** 10–12 weeks of gestation
116. **Ans. d.** Fetal maturity/growth
117. **Ans. c.** In normal gestation (placental resistance is high)
118. **Ans. a.** Detect fetal abnormality
119. **Ans. d.** Echogenic mass with multicystic spaces within endometrial cavity
120. **Ans. a.** Absence of gestational sac in uterus
121. **Ans. d.** Down's syndrome
122. **Ans. c.** Turner's syndrome
123. **Ans. d.** All of the above
124. **Ans. c.** Clusters of microcalcification
125. **Ans. c.** Areas of speculated microcalcifications
126. **Ans. c.** Young breasts have dense tissue
127. **Ans. c.** Macrocalcification
128. **Ans. c.** Seborrhic keratosis
129. **Ans. a.** Bilateral mammogram
130. **Ans. c.** MRI
131. **Ans. b.** Clinical examination, mammography, biopsy/cytology
132. **Ans. a.** Early breast carcinoma
133. **Ans. c.** Gastric content aspiration
134. **Ans. d.** Lesser curvature ulcer with a nodular rim
135. **Ans. b.** Iron
136. **Ans. d.** All of the above
137. **Ans. a.** Pancreatic head growth
138. **Ans. a.** Meniscus appearance
139. **Ans. c.** Lower GI contrast study
140. **Ans. b.** Hyperdense nephrogram
141. **Ans. c.** The flow velocities and the S/D ratio are useful to evaluate high-risk pregnancies
142. **Ans. c.** Transvaginal US

143. **Ans. d.** Crown rump length
 144. **Ans. d.** All of the above
 145. **Ans. a.** Teratoma
 146. **Ans. a.** X-ray
 147. **Ans. b.** First 10 days of menstrual cycle
 148. **Ans. d.** All of the above
 149. **Ans. d.** CT scan
 150. **Ans. a.** Transfemoral route
 151. **Ans. c.** CT scan
 152. **Ans. a.** Radionuclide scanning
 153. **Ans. a.** ERCP
 154. **Ans. c.** Barium study
 155. **Ans. a.** USG
 156. **Ans. a.** Barium swallow
 157. **Ans. c.** Enhances rapidly, contrast stays in it for a relatively longer time and washes out late
 158. **Ans. c.** Neurogenic bladder
 159. **Ans. a.** Micturition cystourethrogram
 160. **Ans. a.** Duplication of ureters
 161. **Ans. d.** ill defined calyx
 162. **Ans. a.** Intravenous urography
 163. **Ans. c.** USG
 164. **Ans. d.** After 6 hours
 165. **Ans. a.** Acute pancreatitis
 166. **Ans. d.** >3 mm
 167. **Ans. b.** Diffuse oesophageal spasm
 168. **Ans. b.** Pancreatitis
 169. **Ans. b.** Phenobarbital
 170. **Ans. b.** Carcinoma colon
 171. **Ans. a.** Chronic pancreatitis
 172. **Ans. b.** Diffuse oesophageal spasm
 173. **Ans. c.** Fibromuscular dysplasia
 174. **Ans. a.** Ileocecal TB
 175. **Ans. c.** 5-6 weeks
 176. **Ans. a.** IUD
 177. **Ans. c.** IUD
 178. **Ans. b.** Membrane in twin pregnancy

Multiple Correct Answers

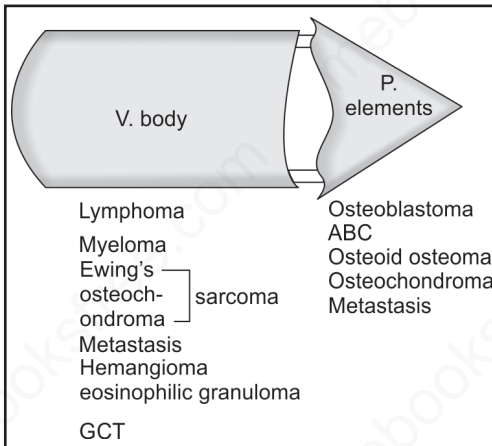
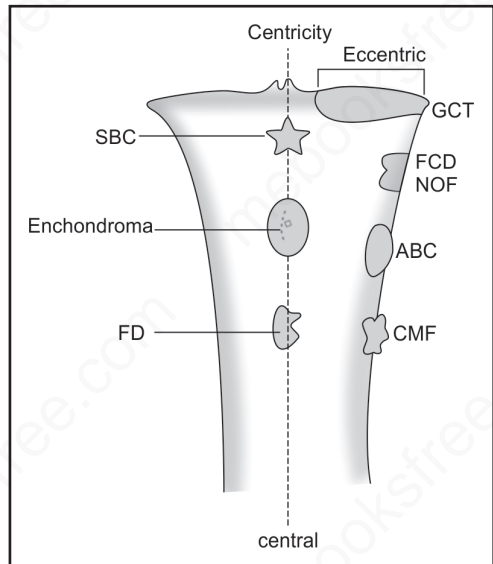
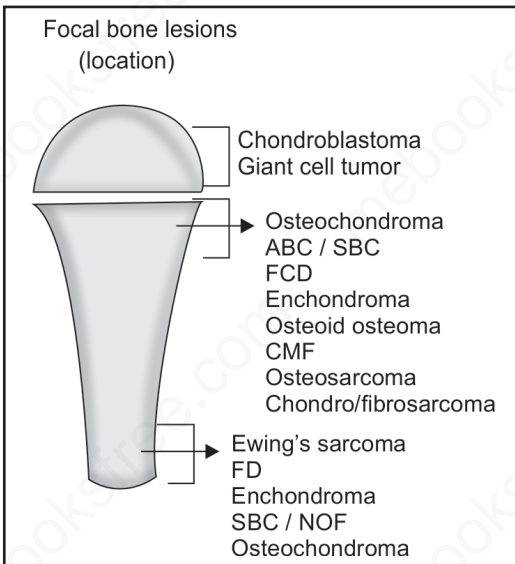
179. **Ans. a.** Calcium oxalate, **c.** Magnesium ammonium phosphate, **d.** Cysteine
 180. **Ans. a.** Pelvic hematoma, **b.** Pelvic lipomatosis
 181. **Ans. b.** Radionuclide enteroclysis, **e.** USG enteroclysis
 182. **Ans. a.** Thick fibrosed gallbladder wall, **b.** Stone impacted at neck of gallbladder, **c.** Pericholecystic edema
 183. **Ans. a.** Acute cholecystitis, **b.** Mucosal thickening, **c.** Cholesterosis, **d.** Ascites, **e.** AIDS cholangitis
 184. **Ans. a.** MRI is used to obtain the image, **c.** It shows the biliary tree
 185. **Ans. b.** Obliteration of splenic shadow
c. Rib fracture
 186. **Ans. a.** Pancreas, **b.** Gallbladder, **c.** Inferior vena cava, **e.** Portal vein



187. **Ans. a.** Gallstone, **b.** Renal stone, **c.** Calcification of vessels, **d.** Hepatic hemangioma, **e.** Calcified costal cartilage
 188. **Ans. b.** MRI, **c.** PET-Scan
 189. **Ans. d.** Spider leg deformity
 190. **Ans. a.** Achlasia, **b.** Trypanosomiasis, **d.** Scleroderma
 191. **Ans. a.** Microcolon on Ba enema, **d.** Obstruction in Ba meal
 192. **Ans. b.** Radionuclide enteroclysis, **e.** USG enteroclysis
 193. **Ans. a.** Schistosomiasis, **b.** Urethral cell carcinoma

5

Musculoskeletal Radiology



| | Age |
|------------------------|-------------------|
| Neuroblastoma | - < 2 yrs |
| SBC | - 0-10 and 10-20 |
| FCD | - 10-20 |
| ABC | - 10-20 |
| Ewing's sarcoma | - 0-10 and 10-20 |
| Osteosarcoma | - 10-20 |
| GCT | - 20-30 and 30-40 |
| Chondrosarcoma | - > 30-70 |
| MM | - > 50 |
| Metastasis | - > 50 |

Patterns of Bone Destruction

I. Geographic

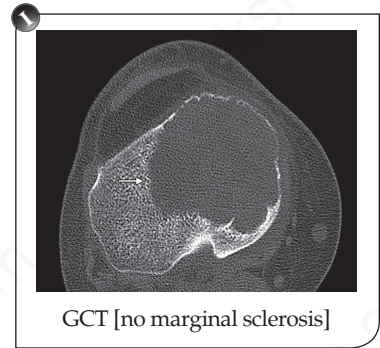
- With sclerotic margin—SBC, enchondroma, CMF, FD, Brodie's
- **No marginal sclerosis**—GCT (Figure), also-SBC
- Ill defined margins—osteosarcoma, chondrosarcoma, ABC, osteomyelitis

II. Moth-eaten Bone Destruction—Wide Zone of Transition—Malignant

- Reticulum cell sarcoma, osteosarcoma, chondrosarcoma, fibrosarcoma, round cell tumor (Ewing's), osteomyelitis

III. Permeative Bone Destruction

- Ewing's, reticulum cell sarcoma, high grade chondrosarcoma fibrosarcoma, angiosarcoma, leukemia and metastasis



NCCT—most valuable modality in detection of subtle matrix calcifications

Matrix Pattern

Osseous Matrix

- Bony trabeculae, radiodense struts (pathognomonic)
- Osteosarcoma, parosteal osteosarcoma, osteoblastoma, FD, fat necrosis

Cartilage Matrix

- Flecks, punctate, flocculated calcified foci.
- **Punctate**—When disruption is in zone of provisional calcification
- **Ring and arc**—Disrupted enchondral bone formation
- Enchondroma, osteochondroma

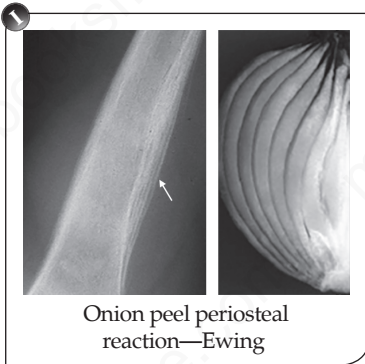
(*-FD-shows thick sclerotic rim—Rind of orange)

Benign tumor—sharp inner and outer margin
Benign inflammatory condition—sharp inner but fuzzy outer margin

Periosteal Reaction

Continuous

- **Single lamella**
 - Healing fracture, Osteomyelitis
- **Solid periosteal**
 - Osteoid osteoma (smooth)
 - Undulating
 - O.M. pulmonary osteoarthropathy



Onion peel periosteal reaction—Ewing

- **Multilamellated/onion peel** (Waxing waning course) (Figure)
 - OM
 - ABC
 - Ewing's
 - Osteosarcoma
- **Spiculated**
 - **Parallel spiculation**—hair on end
 - **Thalassemia**
 - Metastasis
 - Ewing's
 - Osteosarcoma
 - **Divergent/Sunburst** spicules
 - **Osteosarcoma**
 - Hemangioma
 - Osteoblastic metastasis
 - Various directions
 - Ewing's sarcoma

Interrupted/discontinuous (Aggressive)

- **Codman's Angle/Triangle**
 - Due to tumor, blood, edema, pus
 - Both malignant and benign
- **Buttress**
 - Slow growing tumor
- **Truncated lamella**
 - Neoplasm, virulent infection

Lytic Expansile Lesions with Septations (Septations are Residual (N) Bone)

- ABC
- CMF (thick coarse septations)
- GCT
- NOF

Saucerization

- Ewing's Sarcoma
- Metastasis

Bone Scan

- MC-malignant bone tumor-Skeletal metastasis
- IOC for bone metastasis is bone scintigraphy except in spine, where MRI is preferred. MRI is also IOC for extent of primary bony tumor

1 Soft tissue lesion—Hyperintense both on T1W & T2W images
Lipoma

1 Osteomyelitis—shows increased activity on all three phases of bone scan

- Most common-pattern-hot lesions scattered diffusely
- **Causes of False-negative** bone scintigraphy in a patient of bone metastasis
 - Avascular lesions
 - Rapidly growing pure osteoclastic lesions with no osteoblastic activity
 - Lesions with low bone turnover (MM and thyroid cancer)
- Causes of false positive results
 - Increase blood flow in osteoarthritis, trauma and inflammation



IOC for stress fracture of tibia → MRI
IOC for B/C stress fracture → Bone scan



FDG-PETCT is IOC-for Assessing Treatment Response for Metastasis

- Decrease in standard uptake value (SUV) suggests response to treatment

Stress Fractures

(Shows uptake also on blood phases with delayed phases)

- **Fatigue** → Repeated stress (normal bones)-**Fusiform increased radiotracer uptake**
- **Insufficiency**—Normal stress on abnormal bone
- **Sacral stress fracture** → **Honda sign-'H' sign**
- **Shin splints** → Exercise induced pain/tenderness in posteromedial aspect of tibia → **Linear uptake on delayed phases-Oriented** longitudinally ((n) blood pool and blood flow unlike stress fractures)



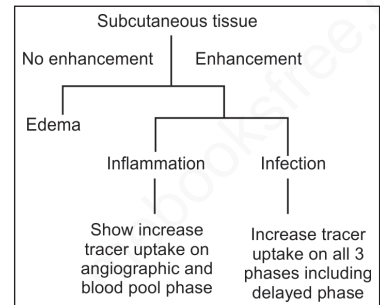
Bone scan remains positive for months even after treatment of acute osteomyelitis—cannot differentiate between healing from chronic active disease.

Paget's Disease

- 'V' shape advanced edge
- Clover, heart and micky mouse signs of uptake in vertebral bodies

Hyperparathyroidism

- **Super scan (most common)**
- Pseudofracture → focal



Renal Osteodystrophy

- Superscan with absent UB activity (due to renal failure)

AVN

- MRI-IOC
 - Bisphosphonate Therapy—Jaw
 - Keinbock's—lunate
 - Kohler's—Navicular



Benign lesions showing uptake on SPECT

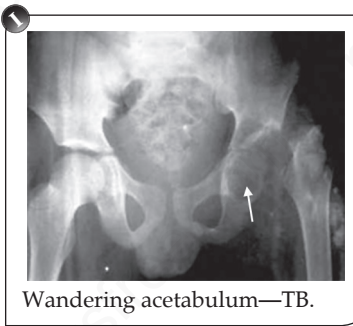
- Osteoid osteoma
- Eosinophilic granuloma
- ABC
- Chondroblastoma
- Enchondroma



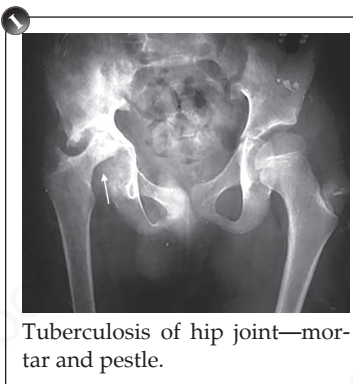KeiL – (Keinbock-lunate)
KoNa – (Kohler-navicular)

1 Bone scan may be (normal) in 85% of cases in first 48 hours but then reduced activity (cold) for a variable period.

1 Dense circumscribed blush in early arterial phase of angiography → osteoid-osteoma.



Wandering acetabulum—TB.



Tuberculosis of hip joint—mortar and pestle.

But bone scan (BS) detects AVN **earlier than MRI** (72 hours vs 6 days).

Reflex-Sympathetic Dystrophy

- Reduced blood flow and blood pool phase, **increased on delayed.**
- Periarticular uptake of radiotracer.

TUBERCULOSIS OF BONES

- **Sequestration and periostitis are not common and usually no sclerosis**
- Very small sequestrum
- Marginal erosions in weight bearing joints.
- Kissing sequestra
- **Rice bodies**
 - Synovial joints
 - Tendon sheaths
 - Bursae

Four Stages

- Inflammatory edema and exudates
- Necrosis and cavitation
- Destruction and deformation
- Healing and repair.
- **Hip tubercular arthritis** can arise in acetabulum, synovium, femoral epiphysis and metaphysis (**Babcock's triangle**)
 - Wandering acetabulum
 - Bird's beak appearance of femur
 - Mortar and pestle appearance (figure)
 - Breaking of Shenton's line
- **Knee TB**
 - **Triple deformity** in advanced cases, i.e. lateral, posterior and superior displacement of tibia on femur
 - Shoulder TB synovial lesions are rare in **shoulder joint** T.B. atrophic type without pus- **carries sica**
- **Frontal bone TB**
 - Button sequestrum
- **Pelvis TB**
 - **Weaver's bottom**

- **TB dactylitis**
 - Cystic expansion of short bones
 - **Spina ventosa** (spina-short, ventosa-expanded with air)
 - Plain radiography is the modality of choice for evaluation and follow-up
 - Differential diagnosis—**syphilitic dactylitis**→
 - Bilateral involvement
 - Symmetric involvement
 - **More periosteitis**
 - Less soft tissue swelling
 - Less sequestrations
- **TB of Tendon Sheath/Bursae**
 - Dumbbell-shaped swelling
 - Melon seed bodies
 - Rice bodies (serofibrinous stage)

Seen in
Syphilitic
dactylitis

1 Acute pyogenic arthritis is a complication of O.M. in infants (< 1 year) and in adults. In rest the physis block spread of infection to joint.

BONE AND JOINT INFECTION

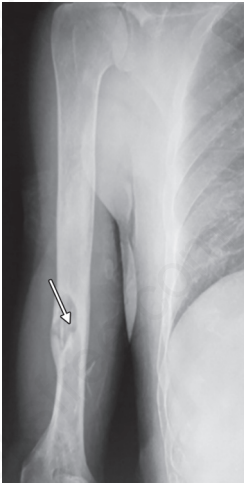
- Osteomyelitis is most frequent at end plates d/t greater no. arteries at this location.
- **Ist ordered investigation—X-ray**
 - Cortical irregularity
 - Periosteal reaction
 - Deep soft tissue swelling
 - Demineralization
 - **X-Ray-Earliest bone changes (7–10 days)**
- **USG**
 - Deep soft tissue swelling is the earliest sign (2–3 days)
 - Periosteal elevation (hyperechoic line)
 - Subperiosteal fluid collection
 - Cortical breach.
- **MRI**
 - Investigation of choice for bone infection suns
 - Most sensitive investigation as it can pickup marrow edema within six hours
- **Bone scintigraphy**
 - Can be positive (1–3 day) earliest
 - Uptake on all three phases:
 - Blood flow (angiography),
 - Blood pool (capillary),
 - Delayed (2–4 hours) uptake in bone

1 However in all cases of shoulder/hip joints due to periosteal spread into synovium due to metaphysical attachment of synovium or joint capsule.

1 **Soft tissue swelling is the 1st radiographic sign of pyogenic arthritis/OM**
Earliest bone change 8-10 day after infection.

1 Cellulitis and OM show similar soft tissue changes, however in cellulitis, the bone is (n).

1 • **Sickle cell disease**
- Prone to salmonella infection (cortical fissuring and tunneling).



Chronic osteomyelitis
(dead dense bone)

False Positive on Scintigraphy

- Degenerative disease
- Healing fracture
- Loose prosthesis

But do not show uptake on early phases (I and II_{nd}).

- **Celery stalk appearance also seen in mucoid degeneration of anterior cruciate ligament on T2W /STIR images.**

Flowing wax appearance – melorheostosis.

- Gallium scan
 - ⁶⁷Ga (gallium) bind to leukocyte and go to sites of inflammation
 - If gallium scan is congruent or hotter than Tc99 MDP infection is implied.
 - If gallium scan is noncongruent or colder-no infection
 - Labeled leukocytes not useful for spinal infection as 50% or more of spinal osteomyelitis present as nonspecific areas of decreased or absent activity.

Chronic Osteomyelitis

- Cloacae
 - Involucrum-3-week
 - Sequestrum-4-week (dead dense bone) (Figure)
 - Bony thickening and deformity
- No sclerosis however seen in skull OM.

Chronic OM of Garre

- Children (endosteal expansion of bone).

Brodie's Abscess—Lytic Bone Lesion with Sclerosed Margin

- Serpiginous tract/channel having sclerosed margin which marks the tract of infection
- Finger like extension in adjacent normal bone pathognomonic

Syphilis

Earliest change is in metaphysis with widening of zone of provisional calcification.

- Congenital Syphilis
 - Bilateral symmetrical destruction of medial end of proximal tibial metaphysis (**Wimberger's sign**)
Pathognomonic
- Late Congenital Syphilis
 - Hutchinson teeth, mulberry molar
 - **Hot cross bun skull**
 - Thickening of upper half of tibia anteriorly → **sabre tibia d/t periosteitis (MC feature)**

Rubella OM

- Celery stalk appearance

Maduromycosis OM

- No pain
- No sequestrum
- No osteopenia
- Shaggy periostitis, reactive sclerosis/**melting snow appearance**
- **Dot and Dash appearance on MRI (Actinomycosis)**

Leprosy

- **Licked candy appearance**

TB SPINE (POTT'S SPINE)

- Begins in cancellous area
- **Paradiscal region**—MC site (less commonly in centrum or at anterior surface)
- Anterior wedging common in dorsal spine
- **Disc avascular**—hence involvement of disc is via direct spread from subchondral bone or beneath anterior or post longitudinal ligaments.
- Skip lesions

*Pyogenic infection on contrary causes more disk destruction.

MRI

- **IOC**—Better detection of skip lesions
- **Earliest detection** of Pott's spine **on STIR/T1W images**

FDG-PET

- Standard uptake values (SUV) > 2.5 for malignant but **up to '21' can be seen in tubercular infections**
- However uptake peaks at 60 minutes than decrease in infective/inflammatory lesions while does not decrease in malignant diseases.
- **FDG-PET + C-11 acetate** → **latter accumulates only in malignant lesions.**

CT

- Better to detect calcification
- **Epidural extent can be missed on plain CT due to beam hardening artifact**

1

- **Spinal vertebral hydatid**—Usually unilocular with diverticulated cysts
- Subarachnoid neurocysticercosis is MC type of spinal cysticerci.

1

On X-ray > 30–50% mineral must be lost before a radiolucent lesion becomes conspicuous.

1

- Dot and Dash appearance also seen in cases of Multiple sclerosis on FLAIR images of MRI.

1

In posterior elements T.B has predilection for → Pedicle and lamina
Pyogenic disease—predilection for—facet joints.

Most Common Variety

- **Paradiscal/marginal/intervertebral/subarticular/metaphyseal lesions.**
- Disease process usually begins in anterior part of vertebral body.
- In dorsal spine the paraspinal abscess has fusiform appearance (**Bird's Nest appearance**).
- Abscess at the **dorsolumbar junction has an indistinct converging lower border (Petering abscess)**.
- Calcification: **Pathognomonic** of tubercular abscess (**tear drop shaped calcification**).
- Four Patterns of Destruction on CT
 - **Fragmentry (47%)-exploded vertebral bodies-MC**
 - Osteolytic (33%)
 - Subperiosteal (10%)
 - Well defined lytic with sclerotic margins (10%)
- Thick nodular rim of increased attenuation due to increase vascularity and hypercellular wall of the inflammatory cavity–**Rind sign**.
- Preserved disk space despite extensive bone destruction–**Floating disk sign**.

1 Pyogenic spondylitis shows multiple small erosions like a 'Pepper Pot' with no calcification.

- 1
- T2W hyperintensity without T1W hypointensity in the cord → **cord edema**
 - with T1W hypointensity → **myelomalacia**.

Healing TB

- Ivory vertebra
- Fusion of contiguous vertebrae considered surest sign of healing.

NONINFECTIVE INFLAMMATORY ARTHRITIS

Described Under

- Distribution of affected joints
- Presence of soft tissue swelling
- Bone density
- Cartilage space narrowing
- Reactive bone formation
- Site and character of erosions
- Subarticular cystic lesions
- Presence of soft tissue calcification
- Joint deformities.

1 **Gas within disk**

- Brucellosis discitis (Hallmark)
- Clostridial
- Streptococcal

Gas in degenerative disk vacuum phenomenon

Rheumatoid Arthritis-MC Inflammatory Arthritis

- **Early changes** → (Nonosseous) → USG and MRI
- **Late changes** → (osseous)
- Earliest
 - Joint space widening and soft tissue swelling (due to edema and swelling of synovium) and effusion
 - Best detected at 5th MCP joint
- Fusiform soft tissue swelling at-PIP and IInd to 5th MCP
- Swelling over ulnar styloid—due to involvement of extensor carpi ulnaris sheath
- Blurring and obliteration of pre-Achilles fat pad
- Blurring and thickening of the Achilles tendon.
- Osteopenia
 - Juxta articular—due to synovial inflammation
 - Generalized → Limitation of movement due pain.

Early X-Ray Change

- Juxta articular osteopenia
- Uniform narrowing of:
 - Distal radioulnar
 - Radiocarpal
 - Intercarpal joints
- Subluxations at 1st MCP and IP (**Hitchhiker's deformity**)
- Terminal phalangeal sclerosis
- Lack of periosteal reaction—Hallmark of disease.
- Marrow edema

1 MRI is IOC for early RA, as treatment is more effective if administered early.

Erosions

- **Most important diagnostic feature (indicates irreversible joint damage) which contain inflamed synovium—enhance on postcontrast imaging**
- **Ball-catcher's view to see erosions**
- **USG more sensitive than radiographs for erosions**
- Earliest sites
 - Bare areas between edge of articular cartilage and site of attachment of joint capsule.
 - Wrist, MCP and PIP MC at radialvolar aspect of head of 2nd and 3rd metacarpals are commonly involved.

1 DIP joints are spared in RA

1 No uniform joint space narrowing—Osteoarthritis.

- **Fusion of carpal bones (latter)**
- Posterosuperior aspect of calcaneum above the insertion of Achilles tendon.
- Tarsal erosions less common in RA than seronegative spondyloarthropathies.
- En face-Erosions appear cystic

Hip

- Reduced medial joint space with medial migration of head of femur and **protrusion acetabuli**.

Late Changes of RA

- Subluxation with ulnar deviation at MCP joints
- **Boutonniere deformity** → flexion at PIP/extension at IP joints
- **Swan-Neck deformity** → extension at PIP/Flexion at DIP
- **Hitchhiker's thumb** → Flexion at MCP/extension at IP joint
- **Bayonet deformity** → Dislocation of the carpus
- **Hallux valgus** → Lateral deviation of toe
- Hallux sesamoids subluxation
- Flattening of transverse arch
- **Telescoping of bones/fingers**
- **Arthritis mutilans**
- **Bird's beak appearance**
 - Grass loss of bone at femoral head (also seen in TB hip).
- Resorption of distal clavicle
- Stress fracture
- Giant synovial cyst
- Ankylosis of carpal bones
- *Sec. O.A. in weight bearing* joints however with very less new bone formation.

Axial Skeleton

- Cervical spine—Most Commonly Involved
 - Osteoporosis/disc narrowing/end plate irregularity (More common in upper cervical vertebrae)
 - **Step ladder appearance due to facet joint erosions**
 - Atlanto-axial subluxation (> 2.5 mm adult; > 4 mm-child)
 - **Erosion of odontoid peg.**

1 Superior compartment involvement in c/o—O.A

1 **Arthritis mutilans**
 RA
 Erosive OA
 Multicentric reticulo-histiocytosis
 Psoriatic arthritis

Best Imaging for RA → MRI → Gold std for synovial imaging

- Increase of enhancement correlates with degree of inflammation
- Fibrotic pannus and pannus with hemosiderin deposit → low signal
- **Rice bodies**

1

Lung changes

- Effusion (MC)
- Pulmonary nodules
- **ILD lower lobes**

JRA

- Fused cervical vertebrae
- Fusion of carpi (squashed carpi)
- Ballooned epiphysis (widened)
- Decrease soft tissue bulk.

Ankylosing Spondylitis

Synovitis with predisposition to develop ankylosis via cartilage metaplasia, enchondral ossification, fibrosis/woven bone formation.

- Bilateral symmetrical sacroiliitis
 - (Earliest change-Loss or blurring of subchondral cortex)
- Rat bite erosions (iliac aspect)
- Spine
 - Romanus lesions (Erosions at corners-at attachment site of outer fibers of annulus fibrosis) (MRI)
 - **Shiny corner sign (On X-ray)**
 - Erosive spondylitis
 - Squaring of vertebrae (due to ALL/PLL thickening)
 - **Barrel-shaped vertebrae** (convex anterior border due to exuberant new bone formation)
 - **Syndesmophytes** (Marginal/Symmetrical/fine/delicate)
 - Bamboo spine
 - **Calcification of i/v discs**
 - **Dagger sign** (ossification of interspinous ligament)
 - **Tram track sign** (ossification of facet joints)
 - Enthesitis
 - Spinal fractures (just beneath the end plates)
 - Traumatic (after spinal fusion) (unstable) (all three columns)

1

Rice bodies

- RA
- TB

1 Protrusio Acetabuli

- RA
- AS
- Osteomalacia

- Stress (Cervico-thoracic/thoracolumbar junction) Sclerotic pseudoarthrosis with destruction of disk and vertebral end plates (**Andersson lesions**) (**Resemble infective discitis**)

- **Large posterior dural diverticulae-meningoceles**
- Arachnoiditis
- Atlantoaxial subluxation

• **Hip**

- Concentric joint space reduction
- Axial migration
- Cuff like osteophytes
- **Protrusio acetabuli**
- Shaggy periostitis

• **Shoulder**

- **Hatchet deformity** on humeral head d/t enthesitis of rotator cuff tendon.
- Enthesitis → Ischial tuberosity (**Ischial whiskering**)

Psoriatic Arthropathy (PA)

- Mono/oligo articular with enteritis
- Peripheral/polyarticular like RA
- Axial like AS

DIP also Involved (MC) with PIP/MCP/MTP

- Bone proliferation-**Bone density preserved**
- Fusiform soft tissue **swelling (sausage digit)**
- Marginal erosions which proceed toward joint along articular surface (**Surface erosion**)
- Marginal erosions
 - Proceed along the capsule away from joint along the metaphysis (**enthesitis erosion**)
 - Proceed along the articular surface (surface erosion)
- **Pencil in cup deformity**
- **Mouse-ears sign (d/t bone proliferation)**
- **Resorption of terminal tufts**
- Arthritis mutilans
- Opera glass hand
- **Nonmarginal syndesmophytes**
- **B/L asymmetric sacroiliitis**
- Paravertebral ossifications.

1 PA have asymmetric sacroiliitis with nonmarginal syndesmophytes unlike AS.

Reiter's Syndrome

- U/L Asymmetric sacroiliitis
- Asymmetric syndesmophytes
- Calcaneal spurs (d/t lamellar or fluffy periostitis)



Chondrocalcinosis

- Gout
- CPPD
- Chronic renal disease (hyperparathyroidism Primary)

Crystal Deposition Arthropathy

Gout

- Monosodium Urate Crystals
- Strong '**negative**' birefringence
- Sharply marginated, round to oval erosions oriented along long axis of bone, **sclerotic rim, overhanging edges**
- Initially periarticular extend to joint
- Tophi
 - Lumpy-Bumpy Soft Tissue
 - Saucerise Underlying Bone
- Chondrocalcinosis

CPPD Deposition

- In hyaline and fibrocartilage
- Weakly birefringent
- **Pseudogout** (intermittent acute attacks)
- Chondrocalcinosis
 - Triangular cartilage
 - Lunotriquetral ligament
 - Symphysis pubis
 - Rotator cuff



Triad of pseudogout

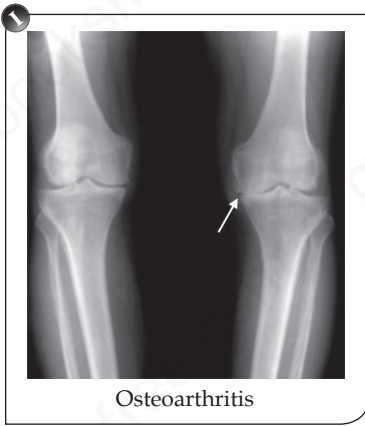
- Pain
- Cartilage calcification
- Joint destruction

Neuropathic Joint 5-Ds

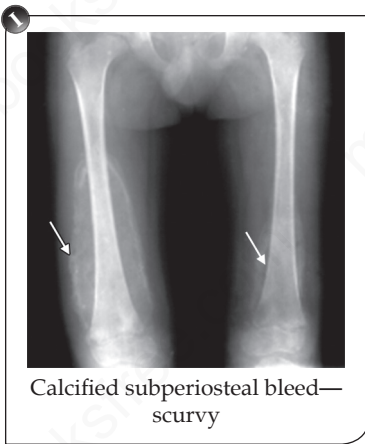
- Disorganization, increased density, debris, destruction and deformity.

Degenerative

- Cryomicrotomy/discography for radial tears.
- Vacuum phenomenon → air in degenerated disk
- Facetal arthropathy
 - More linked with pain than disk and
 - **CT better than MRI for early detection of facetal arthropathy**
- Air within vertebral body—**avascular necrosis of spine**
- Osteoporosis and osteoarthritis are inversely proportional.

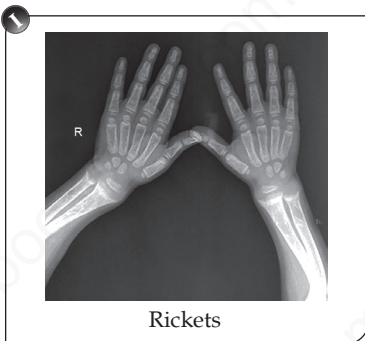


Osteoarthritis



Calcified subperiosteal bleed—scurvy

Normal cupping in infants distal Ulna, both ends of fibula and distal tibia
Normal cupping never seen in bones of elbow



Rickets

Osteoarthritis (OA)

- **False profile view** for hip joint cartilage space.
- Subchondral cysts in acetabulum (**Egger's cysts**)
 - **Sunrise view and merchant view**→ femoropatellar joint
 - **Tooth Sign**→ hyperostotic changes at anterosuperior aspect of patella.
- Palpable Osteophytes
 - Bony nodules at PIP—**Bouchard's**
 - Bony nodule at DIP—**Heberden's nodes**
 - Wavy contours of base of distal phalanx—**Seagull sign/gull wing sign**
 - O.A. of 1st metatarsophalangeal joint—**Hallux rigidus**
 - **Patella MC bone to be affected in O.A**

METABOLIC DISEASE

1. Defects of osteoid formation—scurvy
2. Defects of mineralization—Rickets/osteomalacia
3. Altered bone resorption—Hyperparathyroidism
4. Decreased bone mass with no defect in mineralization/osteoid-osteoporosis

1. Defects of osteoid formation—scurvy

- Osteoporosis
- White line of Frankel (metaphyseal)
- Trummerfeld zone or scorbutic zone
- Wimberger's sign—small sharply defined epiphysis
- Pelkan's spur
- Subperiosteal hemorrhage

2. Defect in Mineralization of Osteoid

- Rickets (child)/Osteomalacia (Adults)
- Incomplete mineralization of normal osteoid tissue
- Soft tissue swelling around growth plates due to hypertrophied cartilage.
- Disorganized zone of provisional calcification.

Rickets

- Increased non-calcified osteoid—Increased radiolucency
- **Osteopenia (MC X-ray finding although non-specific)**

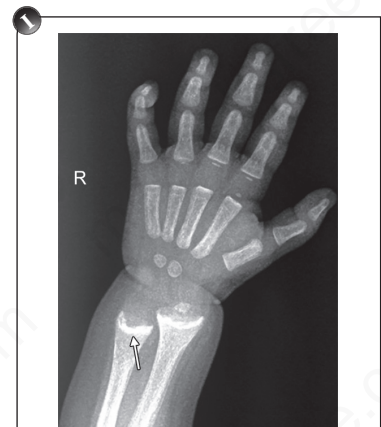
- Changes earlier at distal radius & Ulna (Ulna > radius)
- Growth Activity
 - Costochondral junction > distal femur > proximal humerus > both ends of tibia > distal ulna > distal radius
- Widening, fraying and cupping—classical findings (Figure)
- Widening of growth plates (d/t bulky cartilaginous cells) (Earliest specific radiologic change)
- Irregular metaphyseal margins (paint brush metaphysis) d/t fraying & disorganization of the spongy bone.
- Widening and cupping of metaphysis (d/t **protrusion of bulky cartilaginous cells into poorly mineralized metaphysis**)
- **Osteopenic epiphysis** → irregular, indistinct borders and delayed appearance of ossification center.
- Rarefaction of shafts with coarse texture of cortex.
- Skeletal Deformities
 - **Skull** → posterior flattening, craniotabes (squaring of skull)
 - **Long bones** → bowing
 - **Ribs** → Rachitic rosary—d/t bulbous enlargement (indent the pleural surface/thymus)
 - **Spine** → scoliosis
 - **Pelvis** → Triradiate configuration—d/t protrusion of hip and spine
 - Fractures

Signs of Healing Rickets

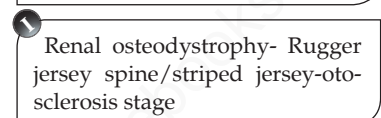
- Reappearance of dense zone of provisional calcification.
- Increase in cupping of healing metaphysis
- Recalcification of the subperiosteal osteoid
- Epiphyseal center becomes sharply defined.

Osteomalacia

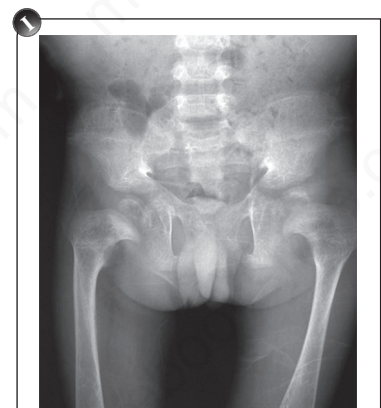- Defective mineralization of cortical & spongy bone.
- **Osteopenia (MC radiological sign)**
- Coarse indistinct trabecular pattern
- Thin cortices



Healing rickets—dense zone of provisional calcification

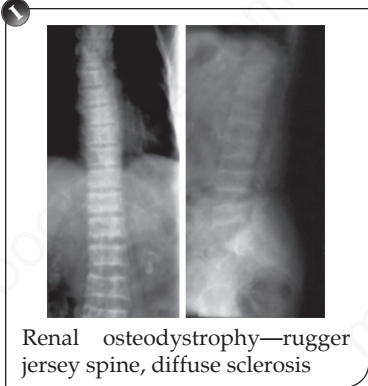

Renal osteodystrophy- Rugger jersey spine/striped jersey-otosclerosis stage

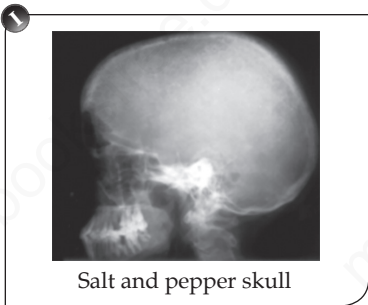
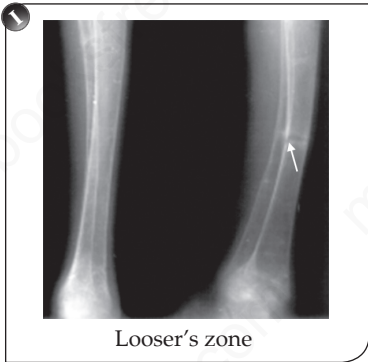

Triradiate pelvis—osteomalacia

- 1 - Trabeculae are coarse and indistinct osteomalacia
- Trabeculae are thin & sharp osteoporosis
- Uniform spinal deformity osteomalacia
- Nonuniform spinal deformity osteoporosis



- 1 Secondary HPT
 - Skeletal changes
 - Sclerosis
 - Soft tissue calcification



- **Pseudofracture/looser's zone/Milkman's fracture/increment fractures/Umbauzonen (at right angle to cortex)** (Mild sclerosis with absence of callus)
 - Axillary margins of scapula
 - Superior and inferior Pubic rami
 - Inner margins of the prox. femur
 - Posterior margins of the prox. ulna and fibula
 - Ribs
- Bone Scintigraphy for osteomalacia
 - Widening of mandible
 - Rachitic rosary sign
 - Tie sign of sternum
 - Pseudofracture sign
 - Prominent epiphysis of knee
- Bony Deformities
 - **Protrusio acetabuli**
 - Triradiate pelvis
 - Biconcave shape vertebral bodies (Cod fish vertebra)
 - Basilar invagination

3. Altered Bone Resorption

Hyperparathyroidism (HPT)

| Primary HPT | Secondary HPT |
|--|--|
| <ul style="list-style-type: none"> • Consist of skeletal features of HPT only • Skeletal changes less florid • Sclerosis rarely seen • Brown tumors • Chondrocalcinosis • Soft tissue and vascular calcification are less common | <ul style="list-style-type: none"> • Skeletal features of HPT with features of renal osteodystrophy (Rickets/osteosclerosis) • More florid • Commonly seen sclerosis • Less common • Less common • More common |

- Bone resorption and substitutive fibrosis hallmark of disease
 - Subperiosteal
 - Intracortical (increased cortical **striations-Tunneling**) **blurring** of trabecular bone.
 - Endosteal
 - Subchondral

- Trabecular surfaces
- **Subperiosteal Resorption**
 - Earliest and best along radial aspect of middle phalanges of middle and index finger.
- Trabecular bone resorption
 - Salt and pepper skull
- Brown tumors/osteitis fibrosa cystica/von Recklinghausen disease
- Condrocalcinosis
 - **Pri:** HPT
 - CPPD disease
 - Chronic renal disease
- **Renal osteodystrophy (Sec-HPT)**-In children metaphyseal changes with cortical erosions-rotting fence post appearance
- *The radiopharmaceutical of choice—^{99m}Tc sestamibi for parathyroid*

Hypoparathyroidism

- **Bony sclerosis (MC) finding**
- Calvarial thickening
- Band like areas of increased radiodensity in metaphysis
- **DISH-Diffuse idiopathic skeletal hyperostosis**
- Subcutaneous calcification
- **Basal ganglia calcification**

Pseudohypoparathyroidism

- **Shortening of 4th metacarpal (Metacarpal sign + if tangential line from heads of 4th & 5th MT intersect IIIrd**
- Exostosis (at 90 degrees to bones rather than away from joint)

Hypercortisolism

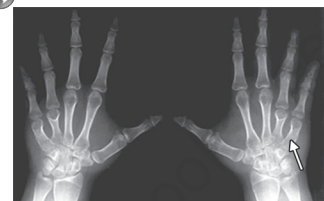- Osteoporosis
- Accentuation of pri. trabeculae
- Increased density of superior and inferior endplates of collapsed vertebra d/t exuberant callus known as—**Marginal condensation**
- Osteonecrosis

Congenital Hypothyroidism

- Deformed and irregular epiphysis (epiphyseal dysgenesis)

Other causes of basal ganglia calcification

- Fahr's (ferrocalcinosis)
- CO poisoning
- Toxoplasma
- CMV
- Radiation
- Pseudohypoparathyroidism



Short 4th and 5th metacarpals—pseudohypoparathyroidism

Positive metacarpal sign

- Basal cell nevus syndrome
- Multiple epiphyseal dysplasia
- Beckwith-Wiedemann syndrome
- Juvenile chronic arthritis
- Sickle cell anemia
- Turner's syndrome

Bullet shaped vertebrae

- Congenital hypothyroidism
- Achondroplasia
- Metachromatic leukodystrophy

- Wormian bones in skull
- Bullet shaped vertebrae
- Slipped capital femoral epiphysis

Thyroid Acropachy

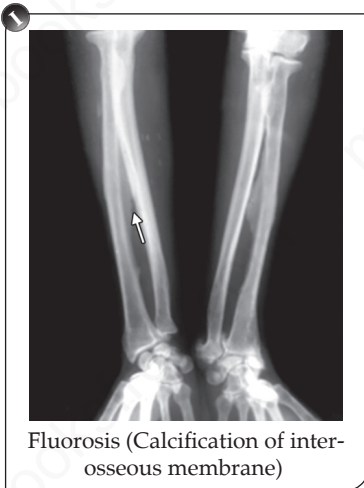
After treatment by antithyroid drugs dense, solid, periosteal new bone with feathery margins along radial margins of metacarpals and phalanges in the diaphyseal region.

Turner's Syndrome

- Depression or slanting of medial tibial plateau with overgrowth of medial femoral condyle.
- Short 4th and 5th metacarpals.

Acromegaly

- Heel pad thickening
- Enlarged sella
- Hyperpneumatized maxillary sinuses
- Widening of mandibular angle
- Prominent joint space in hands
- **Arrow head appearance of distal phalanx**
- Large sesamoid index > 40
- Increased interstyloid distance
- Increased height of intervertebral discs
- Widened and elongated vertebral bodies
- Beaking of symphysis pubis



Fluorosis

- Osteosclerosis
- Thickening of the cortex
- Rose thorn appearance irregularity/fringed inferior margin of ribs
- Ligamentous calcification and ossification
- Ossification of interosseous membrane (figure)
- Osteophytosis
- Paraspinal/intraspinous ligament ossification.

4. Decreased Bone Mass with no Defect in Mineralization/Osteoid-Osteoporosis

- Z. score → age and gender matched
- T. score → compared with standard young population

WHO define BMD on the basis of 'T' scores

- Normal-T ≥ -1 SD of normal
- Osteopenia $-2.5 < T < -1.0$ T between -1 to -2.5 SD
- Osteoporosis $T \leq -2.5$ SD
- Severe osteoporosis $T \leq -2.5$ SD with fragility fractures

Vanishing Bone Disease

- Gorham's disease
- Angiomatosis of bone
- Thick coarse trabeculae with lytic areas in between

BONE TUMORS**Enostosis/Bony Islands**

- Dense intramedullary lamellar bone
- Aligned along long axis of trabeculae

Osteoid Osteoma

- Nidus < 1 cm—cortical (MC)
- Medullary and subperiosteal (less sclerotic bone)
- IOC: CT $>$ MRI
- Equilibrium phases of bone scintigraphy \rightarrow double density sign.

MRI \rightarrow IOC for all bone tumors except Osteoid osteoma where CT is better than MRI

Osteoblastoma

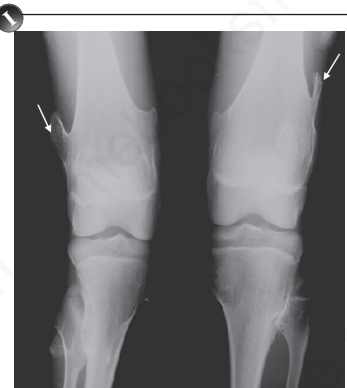- Nidus > 2 cm
- Less surrounding sclerotic halo

FCD

- Fibrous cortical defect-blister like expansion of cortex with thin shell

Osteochondroma

- Malignant
 - If grows after epiphyseal closure
 - Cartilage cap > 2.0 cm
- Diaphyseal aclasis (FIGURE)



Osteochondroma diaphyseal aclasis.

Enchondroma

- Ollier's disease \rightarrow multiple enchondromas
- Enchondromatosis with multiple hemangioma Maffucci's syndrome
- 'O'ring sign \rightarrow popcorn or annular calcification.

Joint extension of tumor if hyaline cartilage is penetrated or tumor extends through capsule.

Fibrous Dysplasia

- + Precocious puberty-McCune-Albright syndrome
- Shepherd's Crook deformity of femur
- Leonine facies
- Expansion of medullary cavity with sclerotic margin
- Ground glass opacity on X-ray
- Increased uptake on radionuclide studies

Calvarial Hemangioma

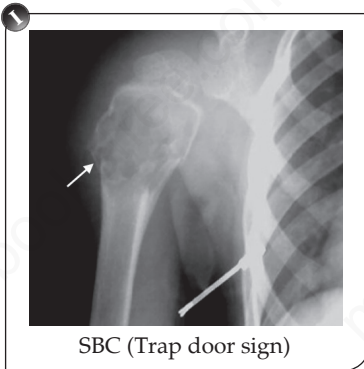
- Sunburst appearance

Vertebral Hemangioma

- Corduroy on X-ray
- Polka dot on CT
- Hyperintense on both T1W and T2W-MRI.

Giant Cell Tumor (Osteoclastoma)

- Soap bubble appearance
- Eccentric lytic without sclerotic rim after closure of epiphysis.



Simple Bone Cyst (Unicameral Bone Cyst)

Majority (Prox. humerus)

- Fallen fragment sign (d/t cystic/fluid nature)
- Trap door sign (Figure)
- Rising bubble sign

Aneurysmal Bone Cyst

- Multiloculated expansile
- Cystic/ballooned out
- **Blood fluid level**

Blood fluid level can also be seen in

- Osteosarcoma (telangiectatic)
- GCT
- Osteoblastoma
- Chondroblastoma

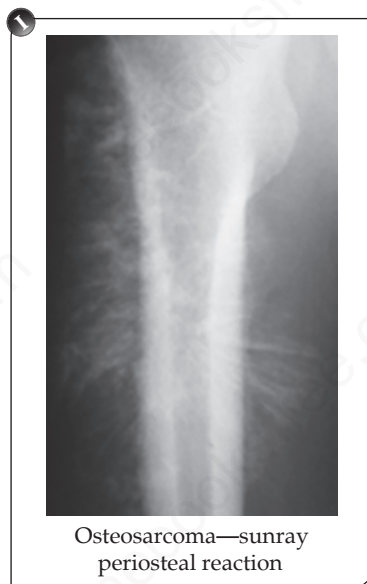
Eosinophilic Granuloma

- Punched out lytic lesion with bevelled margin (d/t unequal involvement of inner and outer table)
- Sclerotic focus (button sequestrum)
- Floating teeth sign in mandible
- Solitary collapsed vertebra in children

Osteosarcoma

- Commonest primary malignant bone tumor in the young

- Sunburst/Sunray pattern/spiculated periosteal reaction (Figure)
- Onion skin periosteal reaction
- Cumulus cloud appearance (d/t osteoid mineralization)
- **MRI-IOC**
- **Intracortical osteosarcomas are rarest**
 - Small lytic lesion surrounded by thickened cortex
 - D/d-Osteoid osteoma and osteoblastoma
- **Pneumothorax**
 - Metastasis of osteosarcoma in lung causes Pneumothorax
- **Juxtacortical/parosteal osteosarcoma**
 - Attached to the surface of the affected bone and has a tendency to encircle it
 - **MC site** → lower end of post. aspect of femur,
 - X-Ray: A well defined radiolucent line separates the tumor from the normal cortex
 - D/d- myositis ossificans (peripheral calcification)
 - Parosteal o.sarcoma (central calcification)



Secondary Osteosarcoma (Mnemonic-FOPP)

- Fibrous dysplasia
- Ollier's disease
- Paget's disease
- Post-radiation osteosarcoma

Ewing's Sarcoma

- Central diaphyseal permeative lesion with wide zone of transition
- Saucerization
- Multilaminar (onion peel) periosteal result however incomplete laminar periosteal reaction is more common with marginal codman's triangle.
- Hair on end periosteal reaction can also be seen.
- MC pri. malignant tumor to metastasize to bone.

Chordoma

- Lytic destruction with calcification → Sacrum/basiocciput.

Multiple Myeloma

- MC primary malignant neoplasm of bone.

Metastasis going beyond elbow and knee joints—BBC

- Bronchus
- Bladder (urinary)
- Colon

Post-radiation sarcoma

- MC in pelvic/shoulder girdle
- **MC** → osteosarcoma
- **IInd MC** → malignant fibrous histiocytoma

- Normal ALP and Phosphate
- Increased ALP if healing
- Punched out lytic lesions (Rain drop lesion) (Figure)
- D/d—metastasis

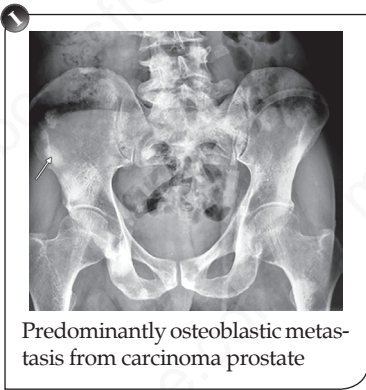
Plasmacytoma

- **Medulla of bone**
- Geographic, radiolucent bone which is expansile with apparent trabeculation or a **soap bubble appearance**.
- Differential Diagnosis
 - Metastasis
 - Chordoma
 - Brown tumor
 - Hemophilic pseudotumor
 - Hydatid cyst
 - FD
 - GCT

1 **Soap bubble app.**
 – GCT
 – Angiosarcoma
 – Fibrosarcoma

1 Skeletal survey is better than bone scan as MM lesions are osteolytic with no-bone reaction

1 Metastasis can give-
 – Sunburst appearance
 – Simulating osteosarcoma



1 *****FDG PET more sensitive and specific for bone metastasis than bone scintigraphy.**
***** NaF (Sodium fluoride) PET more sensitive to detect both osteolytic & osteoblastic metastasis.**

| Multiple Myeloma | Metastasis |
|--|--|
| <ul style="list-style-type: none"> • Less common • I/V disc may involve • Soft tissue mass associated with bony lesion • Mandible common site • False 'negative' on radionuclide studies • ALP may be (n) • Punched out | <ul style="list-style-type: none"> • Post. elements more common • Less likely • Soft tissue ext. less common • Rarely • Radionuclide studies very sensitive • ALP always raised • Irregular lytic lesions |

POEMS Syndrome

- Polyneuropathy
- Organomegaly (hepatosplenomegaly)
- Endocrinopathy (DM)
- M-proteins (plasma cell dyscrasia)
- Skin changes (hirsutism, pigmentation)

Metastasis

Predominantly Osteoblastic Metastasis

- Prostate (Figure)
- Carcinoid
- Stomach

Mixed Osteolytic and Osteoblastic

- Breast
- Lung

Osteolytic

- Hypernephroma (RCR) (Blow out metastasis)
- Thyroid

IOC for-metastatic workup is bony scintigraphy except in spine where MRI is preferred

Super scan

- Generalized increased bone activity with absent or reduced renal activity
- e.g. diffuse osteoblastic metastatic disease

1

CNS tumors and BCC of skin.
Does not metastasize to bone-
rest all tumors can metastasize
to bone.

TRAUMA

Plain Radiography-Ist investigation

IOC→NCCT

- Green Stick (Hickory Stick Fracture) d/t angulative force break on convex cortex with intact concave side
- Torus (Buckling)
 - Longitudinal **compressive** forces
 - Cortex bulges out

Fractures of Growth Plate/Physis-Salter-Harris Classification X-ray

- Type I: Through growth plate-**X-ray (n)**
 - II: Fracture through displaced growth plate along with metaphysis-(**MC**)**Thurston Holland-sign**
 - III: Through growth plate and epiphysis→**Intra-articular (need open reduction)**
 - IV: Though G.P., Meta and epiphysis
 - V: Crush/compressive fracture

Features of Nonunion

- Rounding of fracture edges
- Smoothing of margins with sclerosis
- Gap b/w two fragments
- Demonstration of mobility (on serial stress radiograph/fluoroscopy)
- **Lack of callus formation**
- Pseudoarthrosis

Upper Limb

- Anterior dislocation of shoulder
 - **Hill-Sach's defect** (Impaction of humeral head)
 - **Bankart's lesion** (avulsion of inferior glenoid labrum)
- Post. Dislocation
 - Light bulb sign on AP-X-ray
 - Tennis Racquet sign
- Inf. dislocation
 - Luxatio erecta—arm held in abduction

Fractures with Acronyms

- Fracture of Prox. ulnar shaft with dislocation of the radial head
 - Monteggia's Fracture Dislocation (MUS)
- Isolated # of distal ulnar shaft → **Nightstick/Parry**
- Fracture of distal shaft of radius at junction of middle & distal third with dislocation of distal radio-ulnar joint
 - Galeazzi or Reversed Monteggia#
- Fracture of distal end of radius with post. angulation of distal fragment → **Colle's #**
 - Dinner Fork Deformity on Lateral View
- Fracture of distal radius with anterior angulation
 - Smith's fracture/Reversed Coll's fracture
- # Post. rim of distal radius → **Barton's #**
- # Anterior rim of distal radius → **Reverse Barton's**
- Radial styoid-**Chauffeur's fracture**
- #Scaphoid → AVN-X-ray view of choice → oblique view
- Avulsion fracture of triquetrum at attachment site of radiocarpal ligament → **Fischer's fractures**
- Scapholunate Dislocation
 - Terry Thomas sign
 - Signet ring sign (Small and circular scaphoid)
- Oblique intraarticular # of base of 1st metacarpal with dorsal and radial displacement of shaft → **Bennett's fracture**
- Comminuted Bennett's fracture → is **Ronaldo's #**
- Transvers # of neck of 5th MC with volar angulation-**Boxer's #**
- Avulsion chip # At insertion of extensor tendon-**Mallet finger**

AVN-common sites are:

- Femoral head
- Scaphoid
- Humeral head
- Talus

- MRI is IOC for joints and soft tissue lesions

Lower Limb

- # of lateral tibial plateau at attachment of iliotibial tract → Segond's #
- Undisplaced spiral # of shaft (<2 yrs) of tibia → Toddler's #
- #Calcaneum → less/decreased Bohler's angle (N)-28-40 degrees)
- Lisfranc's dislocation dislocation at tarsometatarsal joints
- Chopart's dislocation-medial dislocation of talonavicular and calcaneo-cuboid joints of the foot.

Soft Tissue

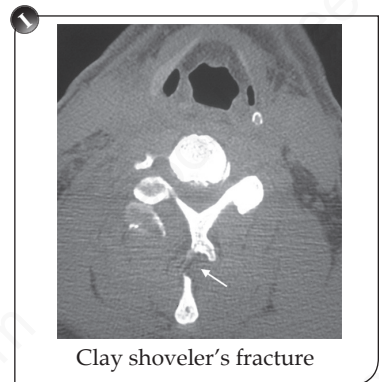
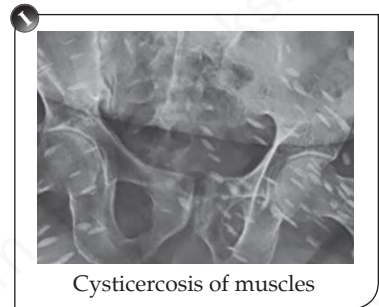
- Decrease radiodensity of soft tissue (**Fat and air**)
- Calcified cyst, oval, elongated along the long axis of muscle fiber → cysticercosis (Figure)
- Pipe stem calcification → phlebolith/vascular calcification
- Repeated trauma leads to bone formation at tendon/lig. Insertion sites
 - Adductor longus muscle → Rider's bone
 - Pellegrini-Stieda lesion → adductor tubercle of distal femur
 - Fencer's bone → brachialis muscle
 - Dancer's bone → soleus muscle
- Bursitis superficial to patella → **house maid's knee**
- Bursae superficial to olecranon → **Student's elbow**.

Spondylolisthesis

- Inverted Napoleon hat sign (on AP view)
- Beheaded Scottish terrier sign on oblique view spondylolysis → Scotty dog with collar
- Fracture of C₇ spinous process → Clay Shoveler's fracture

Tractional Injuries

| | |
|-----------------------------------|----------------------|
| Tibial tubercle | – Osgood Schlatter's |
| Distal pole of patella | – Sinding Larsen's |
| Os calcis | – severs |
| Ring epiphysis of vertebra | – Scheuermann's |
| Capitulum | – Panner's |
| Scaphoid | – Preoser's |



AVN

- Prox. femoral epiphysis → Perthe's
- Distal epiphysis of IInd MT → Freiberg's
- Navicular → Kohler's
- Lunate → Kienbock's

Injuries around knee

Meniscal Injuries

- Radial/free edge tears
 - Cleft sign
 - Marching cleft sign
 - Ghost sign (absent meniscus)
 - Truncated triangle sign.
- Longitudinal Tears
 - Bucket handle tear
 - Absent bow-tie on 2-successive sagittal images on MRI (Absent bow-tie sign).

1 Elastographic techniques
ARFI → acoustic radiation force impulse
TE → Transient elastography

ACL Tear

- Double PCL sign (MRI)
- Empty notch sign (MRI)
- Lax PCL (Question mark configuration)

Segond Fracture

- Anterolateral corner fracture of tibial plateau

O' Donoghue Triad

- ACL tear
- MCL disruption
- Medial meniscus tear

1 (N) oblique view Scottish dog appearance

Pellegrini-Stieda Disease

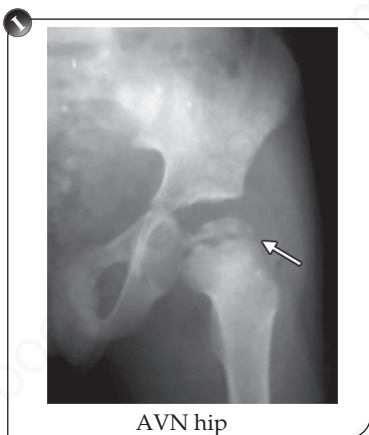
- Calcification around the medial femoral condyle
- chronic partial/complete tears of MCL

Baker's Cyst

- b/w semimembranous and medial head of gastrocnemius.

Shoulder Labral Injury

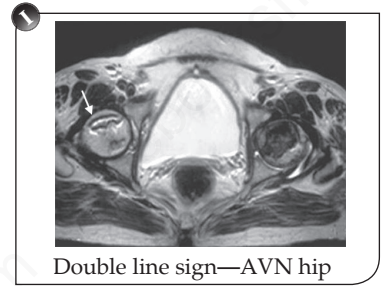
- Perthes → Labrum injury + intact periosteum
- GLAD → Labrum + cartilage (Glenolabral articular disruption)
- ALPSA → Labrum + periosteal (stripping) (Anterolabroligamentous periosteal sleeve avulsion)
- **Bankart-periosteal rupture + labrum injury**
- HAGL-capsule and IGHC detached from humerus (Humeral avulsion of GHL)
- **Thick MGHL with absent anterosuperior → Buford complex labrum**



Avascular Necrosis of HIP

- MC MRI Appearance
 - Geographic/serpiginous circumscribed subchondral lesion
 - Double line sign on T2W images
 - Bright Band sign
 - Crescent sign (subchondral collapse)
- Mitchell’s Classification

| | | | |
|----------|---------|---|----------|
| Class A: | Adipose | - | Fat |
| B: | Blood | - | Blood |
| C: | sea | - | Water |
| D: | Dense | - | Fibrosed |
- Radionuclide Study by 99Tc MDP Later
 - Photopenic zone
 - Doughnut sign—Due to reactive hyperemia/ reparative response



Femoroacetabular Impingement

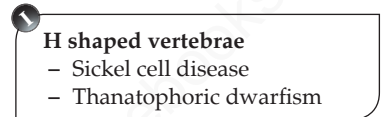
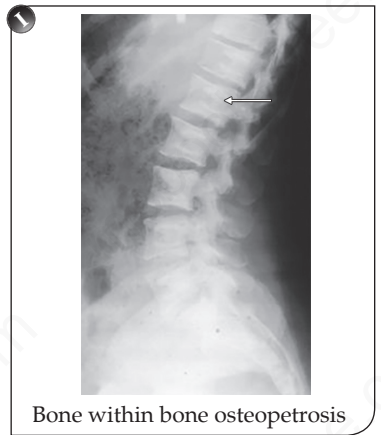- **Cam impingement** → pistol grip deformity
- **Pincer impingement** → crossover sign

Erlenmeyer Flask Deformity

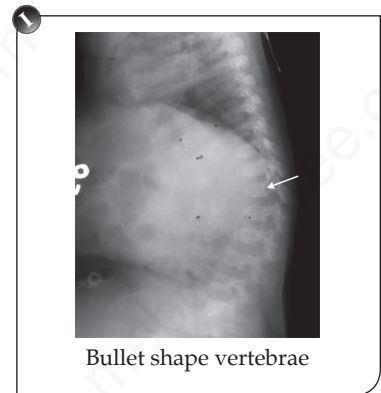
- Metaphyseal dysplasia
- Thalassemia
- Osteopetrosis
- Gaucher’s disease

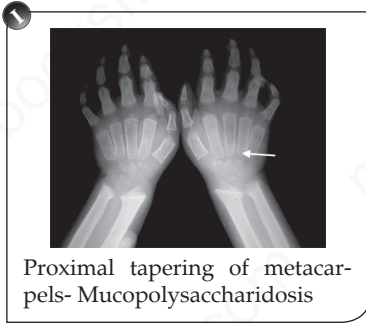
Paget’s Disease

- Osteoporosis circumscripta
- Picture frame vertebra
- Cotton wool skull

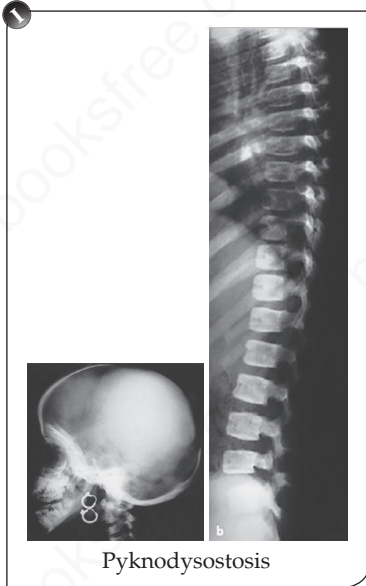

| Benign vertebral collapse | Malignant vertebral collapse |
|--|--|
| <ul style="list-style-type: none"> • (n) signal intensity in nonfractured vertebrae • Ab (n) signal parallels fracture • Flat post. border of vertebra • No paravertebral mass • Ab (n) signal stabilizes with time • Fluid sign present (also in osteoporotic collapse) | <ul style="list-style-type: none"> • Ab (n) signal in other non-fractured vertebrae • Ab (n) signal of entire fractured vertebra • Convex post: border of fractured vertebrae • Occasional paravertebral mass • Progresses to destruction |

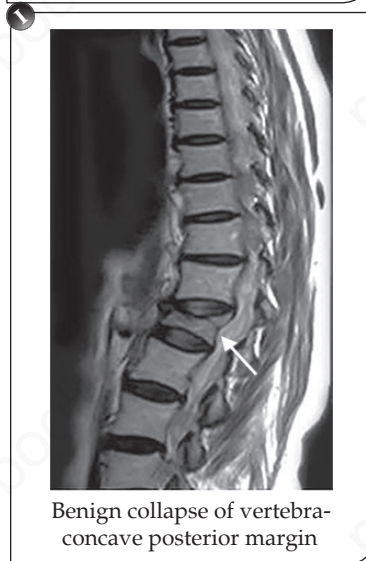



Proximal tapering of metacarpals- Mucopolysaccharidosis



Pyknodysostosis



Benign collapse of vertebra- concave posterior margin

ANEMIA

Thalassemia

- Diploic widening (occiput spared)
- **Hair on end**
- **Crew cut**
- **Hair brush**
- Flask shaped femora
- Rodent facies
- Widened Intercondylar Notch-
 - Hemophilic arthropathy
 - JRA
 - TB

Ivory Vertebra

- Paget's
- Metastasis
- Lymphoma
- Infection

Vertebra Plana

- Eosinophilic granuloma (child)
- Metastasis/Melanoma
- Lymphoma
- T.B./Trauma

Achondroplasia

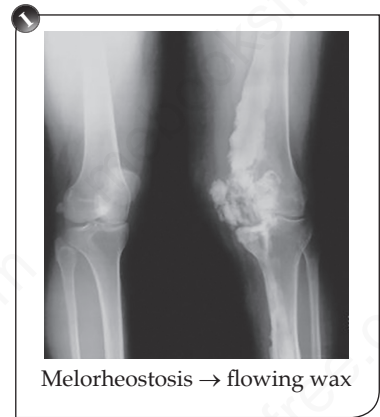- Champagne Glass pelvis (narrow Sacrosciatic notch)
- Trident hand
- Chevron sign-V shape notch in metaphysis
- Bullet shape vertebrae
- Post scalloping of vertebrae
- Tomb stone iliac blades

Mucopolysaccharidosis

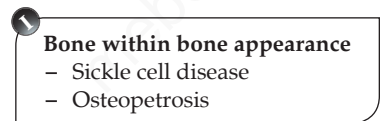
- Oar shaped ribs
- Anterior beaking of vertebra central Morquios, anterioinferior Hurler's
- J Shaped sella
- prox. tapering of metacarpals
- Simian pelvis

Pyknodysostosis

- Increase bone density
- Spool vertebra
- Obtuse angle of mandible
- Acroosteolysis
- Osteogenesis imperfecta
 - Diaphyseal fractures
- Battered baby syndrome
 - Metaphyseal corner #
 - Post rib #
- **Melorheostosis**
 - Molten wax appearances/Candle dripping sign (Figure)
- Nail patella syndrome
 - Iliac horns.
- Thanatophoric dwarfism
 - H-shaped vertebra
 - **Telephone handle long bones**
 - Clover leaf skull



Melorheostosis → flowing wax



Bone within bone appearance

- Sickle cell disease
- Osteopetrosis

BREAST IMAGING

Screening Mammography

Mammography has 4 basic X-ray films two for each breast which includes mediolateral oblique and craniocaudal views.

The standard mammogram (along with appropriate history-taking) makes up the entire screening mammogram. The indication for this examination is the search for

- **Occult carcinoma in an asymptomatic patient** (>40 years)
- Breast lump in men
- Asymptomatic women with risk factor/ Symptomatic women in >35 years. (This is done sometimes to assess the density of breast, if more MRI is performed).
- Surveillance of breast following local excision.
- (Younger women have dense breast due to glandular tissue- low sensitivity for mammography)
- Mammography is the screening modality of choice for breast cancer as sometimes only microcalcification is the finding in DCIS.

- MRI is most sensitive to detect DCIS. (dynamic enhancement curves; Type-1 benign, type 2 is intermediate and type 3 curve signify malignancy)
- MRI is screening method of choice in patients with family history or BRACA/P53 mutations as need assessment at younger age where mammography is not sensitive
- Also MRI is preferred in patients with silicon implants.

Diagnostic Mammography

The diagnostic mammogram begins with the two-view standard mammogram.

Indications for diagnostic mammography are (1) a palpable mass or other symptom or sign (e.g. skin dimpling, nipple retraction, or nipple discharge that is clear or bloody) and (2) a radiographic abnormality on a screening mammogram. Additionally, patients with a personal history of breast cancer may be considered in the diagnostic category.

- Mammography is a part of triple assessment which includes—clinical assessment (history and examination), mammography or USG and histopathology which is used to confirm the diagnosis.

Features of breast lesion on mammography

| Benign | Malignant |
|--|---|
| Smooth marginated, low density, homogenous lesion | Ill defined irregular margins with spiculations, high density, heterogenous lesion |
| Macrocalcifications (> 0.5 mm) <5 in number (Lobular, rod like (duct ectasia), tram like (vascular) calcifications) | Microcalcifications (< 0.5 mm) >10 in number Granular Casting calcification within ducts |
| Calcification with level in milk of calcium cyst | • Pleomorphic |
| Egg shell curvilinear calcification in fat necrosis | • Fine heterogenous-rounded very thin but irregular shaped |
| Popcorn calcification in involuting fibroadenoma | |
| Punctuate (very small sharply defined, pin point like) | Fine branching |

BIRADS: breast imaging reporting and data system—used to grade the breast lesion on mammography

| Grade | Interpretation | Management |
|-------|---|----------------------------|
| 0 | Incomplete evaluation | Complete it |
| 1 | Normal | Routine mammography |
| 2 | Benign | Routine mammography |
| 3 | Probably benign (<2% chances of malignancy) | Short follow up (6 months) |
| 4 | Suspicious/intermediate (3-90% chances of malignancy) | Biopsy |
| 5 | Highly suspicious (> 95% chances of malignancy) | Biopsy |
| 6 | Biopsy proven | Definitive treatment |

Breast Ultrasonography

The indications for ultrasonography are:

- Mammographically detected mass, the nature of which is indeterminate
- A palpable mass that is not seen on mammography
- A palpable mass in a patient below the age recommended for routine mammography
- Guidance for intervention
- The augmented breast
- Breast inflammation
- Breast lump in male
- **Breast lump developing during pregnancy or lactation**

Ultrasonography is a highly reliable technique for differentiating cystic from solid masses. If criteria for a simple cyst are met, the diagnosis is more than 99% accurate.

A limitation of ultrasonography is that it is very operator dependent.

Features on USG

The benign lesions are usually well defined, smooth margined, broader than taller, homogenous hypo-echoic masses.

Malignant masses are heteroechoic masses, taller than broader, irregular, spiculated, infiltrating margins with necrosis and internal vascularity.

USG Elastography

It is a recent advancement of USG used to detect stiffness of tissue. Malignant masses have more stiffness than benign.

QUESTIONS

1. **Molten-wax appearance is seen in:**
 - a. Osteoporosis
 - b. Osteopoikilosis
 - c. Melorheostosis
 - d. Osteogenesis imperfecta
2. **A person has an injury in the forefinger with glass and it is suspected that he has a retained piece of glass in his finger. What is the first investigation you will do?**
 - a. MRI
 - b. CT scan
 - c. Plain radiograph
 - d. Ultrasonography
3. **A 76-year-old man presents with lytic lesion in the vertebrae. X-ray skull showed multiple punched out lesions. The diagnosis is:**
 - a. Metastasis
 - b. Multiple myeloma
 - c. Osteomalacia
 - d. Hyperparathyroidism
4. **Champagne glass pelvis is seen in:**
 - a. CDH
 - b. Down's syndrome
 - c. Cretinism
 - d. Achondroplasia
5. **Multiple punched-out lesions on skull X-ray is found in:**
 - a. Down's syndrome
 - b. Hyperparathyroidism
 - c. Multiple myeloma
 - d. All of the above
6. **In scurvy all the following radiological signs are seen except:**
 - a. Pelican spur
 - b. Soap bubble appearance
 - c. Zone of demarcation near epiphysis
 - d. Frenkel's line
7. **Pelican spur is seen in:**
 - a. Rickets
 - b. Scurvy
 - c. Hemophilia
 - d. All of the above
8. **Wind swept deformity is seen in:**
 - a. Ankylosing spondylitis
 - b. Scurvy
 - c. Rheumatoid arthritis
 - d. Rickets
9. **Which of the following features on mammogram would suggest malignancy?**
 - a. Well defined lesion
 - b. A mass of decreased density
 - c. Areas of speculated microcalcifications
 - d. Smooth borders
10. **Investigation to diagnose stage-I carcinoma breast:**
 - a. B/L mammogram
 - b. X-ray chest
 - c. Bone scan
 - d. Liver scan
11. **The sensitivity of Mammography is low in young females because:**
 - a. Less glandular tissue and more fat
 - b. Young females are less cooperative
 - c. Young breasts have dense tissue
 - d. Because of less fat content
12. **Which of the following is the least useful for diagnosis of spondylolisthesis?**
 - a. CT
 - b. MR
 - c. X-ray lumbar spine-AP view
 - d. X-ray lumbar spine-Lateral view
13. **Beheaded scottish terrier sign is:**
 - a. Spondylolysis
 - b. Spondylolisthesis

- c. Lumbar canal stenosis
 - d. S lipped disc
14. In spondylolisthesis following radiological features is seen:
- a. Scotty dog
 - b. Scotty dog wearing a collar
 - c. Beheaded scotty dog terrier sign
 - d. Napoleon sign
15. Calcification around the joint is seen in:
- a. Pseudogout
 - b. Hyperparathyroidism
 - c. Rh. arthritis gout
16. Looser's zone is seen in:
- a. Osteogenesis imperfecta
 - b. Osteopetrosis
 - c. Osteomalacia
 - d. Hypoparathyroidism
17. Bamboo spine is seen in:
- a. Ankylosing spondylitis
 - b. RA
 - c. Paget's disease
 - d. All of the above
18. X-ray finding of osteomyelitis within 5 day is:
- a. Cystic swelling
 - b. Soft tissue swelling
 - c. New bone formation
 - d. Sequestrum formation
19. Wormian bones are seen in all except:
- a. Hypothyroidism
 - b. Down syndrome
 - c. Turner syndrome
 - d. Osteogenesis imperfecta
20. Bare orbit is/are seen in:
- a. NF-1
 - b. Osteomyelitis
 - c. VHL
 - d. Tuberous sclerosis
21. Best radiographic view for fracture of C1, C2 vertebrae is:
- a. AP view
 - b. Odontoid view
 - c. Lateral view
 - d. Oblique view
22. Which of the following is not true regarding ossified posterior longitudinal ligament (OPLL)?
- a. Most commonly involves 'thoracic spine
 - b. Gradient echo MR sequence may overestimate the canal stenosis
 - c. MRI is best for diagnosis
 - d. Low signal intensity on all MR sequences
23. Multiple lytic lesions of skull with beveled edges are seen in:
- a. Eosinophilic granuloma
 - b. Metastases
 - c. Multiple myeloma
 - d. Neuroblastoma
24. Sonographic finding of spina bifida:
- a. Ventriculomegaly
 - b. Obliteration of cisterna magna
 - c. Small BPD
 - d. Abnormal curvature of cerebellum
25. Hair on end" appearance is seen in:
- a. Thalassemia
 - b. Sickle cell anemia
 - c. Hemochromatosis
 - d. Megaloblastic anemia
26. Radiological findings of scurvy are A/E:
- a. Epiphyseal widening
 - b. Metaphyseal porosis
 - c. Metapyseal infarction
 - d. Pelkan spur
27. Radiological feature of osteosarcoma is:
- a. New bone formation
 - b. Sunray appearance
 - c. Cotton wool appearance
 - d. Osteoid formation

28. Radiographic appearance of Pindborg's tumor is:
- Onion-peel appearance
 - Sunburst appearance
 - Cherry-blossom appearance
 - Driven-snow appearance
29. Expansile lytic lesion with fluid-fluid levels within the metaphysis of fibula seen on CT aided MRI in an early adolescent female is typical of:
- Giant cell tumor
 - Aneurysmal bone cyst
 - Hemangioma
 - Fibrous dysplasia
30. Not a radiological feature of rickets:
- Splaying of metaphysis
 - Cupping of metaphysis
 - Rachitic rosary
 - Pelkan's spur
31. Which endocrine disorder is associated with epiphyseal dysgenesis?
- Hypothyroidism
 - Cupping of metaphysis
 - Addison's disease
 - Hypoparathyroidism
32. A classical expansive lytic lesion in the transverse process of a vertebra is seen in:
- Osteosarcoma
 - Aneurysmal bone cyst
 - Osteoblastoma
 - Metastasis
33. Best investigation for bone metastasis is:
- MRI
 - CT
 - Bone scan
 - X-ray
34. An eight-year-old boy presents with back pain and mild fever. His plain X-ray of the dorsolumbar spine reveals a solitary collapsed dorsal vertebra with preserved disk spaces. There was no associated soft tissue shadow. The most likely diagnosis is:
- Ewing's sarcoma
 - Tuberculosis
 - Histiocytosis
 - Metastasis
35. Chondrocalcinosis is seen with:
- Gout
 - Osteoarthritis
 - Pseudogout
 - Septic arthritis
36. Investigation of choice for a lesion of temporal bone:
- CT
 - MRI
 - USG
 - Plain X-ray
37. Codman's triangle is a feature of:
- Osteosarcoma
 - Osteochondroma
 - Osteoid osteoma
 - Chondrosarcoma
38. Radiological mass shows sunray appearance is:
- Osteosarcoma
 - GCT
 - Osteomyelitis
 - Ewing's sarcoma
39. A 40-year-old male female patient on long-term steroid therapy presents with recent onset of severe pain in the right hip. Imaging modality of choice for this problem is:
- CT scan
 - Bone scan
 - MRI
 - Plain X-ray
40. Which one of following is the earliest radiographic manifestation of childhood leukemia?
- Radiolucent transverse metaphyseal band
 - Diffuse demineralization of bones
 - Osteoblastic lesions in skull
 - Parenchymal pulmonary lesions on chest films

41. **Calcification of intervertebral disc is seen in:**
- T.B. spine
 - Prolapse of intervertebral disk (PID)
 - Non-rheumatic ankylosis
 - Rheumatic ankylosis
42. **Post irradiation thyroid tumor is:**
- Follicular Ca
 - Papillary Ca
 - Lymphoma
 - Hurthle cell tumor
43. **Calcification of meniscal cartilage is feature of:**
- Achondroplasia
 - Hyperparathyroidism
 - Gaucher's disease
 - Pseudogout
44. **Which one of the following is a recognized X-ray feature of rheumatoid arthritis?**
- Juxta-articular osteosclerosis
 - Sacroiliitis
 - Bone erosions
 - Periarticular calcification
45. **Bone Density is best studied by**
- CT scan
 - DEXA scan
 - MRI scan
 - Bone scan
46. **Earliest evidence of healing in rickets is provided by:**
- S. Ca⁺⁺
 - S. PO₄³⁻
 - Radiological examination of growing bone ends
 - S. Alkaline Phosphate level
47. **Splaying and cupping of the metaphysis is seen in:**
- Rickets
 - Scurvy
 - Paget's disease
 - Lead poisoning
48. **Flaring of anterior ends of the ribs is characteristically seen in:**
- Neurofibromatosis
 - Scurvy
 - Rickets
 - Hypothyroidism
49. **Best investigation for traumatic paraplegia:**
- CT scan
 - MRI
 - X-ray spine
 - Myelography
50. **A small simple lytic lesion in X-ray of upper end of humerus. The diagnosis is ?**
- Osteosarcoma
 - Osteochondroma
 - Unicameral bone cyst
 - Osteoclastoma
51. **Radiological features of scleroderma are A/E:**
- Diffuse periosteal reaction
 - Esophageal dysmotility
 - Erosion of tip of phalanx
 - Lung nodules
52. **Fraying and cupping of metaphyses of long bones in a child does not occur in:**
- Rickets
 - Lead poisoning
 - Metaphyseal dysplasia
 - Hypophosphatasia
53. **X-ray of which bone (s) would be diagnostic in hyperparathyroidism?**
- Skull
 - Phalanges
 - Long bones
 - Scapula
 - Spine
54. **Pathognomonic feature of hyperparathyroidism:**
- Osteopenia
 - Loss of Lamina dura
 - Brown's tumor
 - Subperiosteal resorption of phalanges

55. **The gold standard for the diagnosis of osteoporosis is:**
- Dual energy X-ray absorptiometry
 - Single energy X-ray absorptiometry
 - Ultrasound
 - Quantitative computed tomography
56. **Which of the following is not a cause of generalized increase in bone density in adults?**
- Myelosclerosis
 - Renal osteodystrophy
 - Fluorosis
 - Caffey's disease
57. **Expansion of the contrast filled space in myelography is seen in:**
- Intramedullary tumor
 - Intradural extramedullary tumor
 - Spinal dysraphism
 - Extradural tumor
58. **Heberden's nodes are found in:**
- PIP joints in osteoarthritis
 - DIP joints in osteoarthritis
 - PIP joints in rheumatoid arthritis
 - DIP joints in rheumatoid arthritis
59. **Tufting of distal phalanx is characteristically seen in:**
- Gout
 - Psoriatic arthropathy
 - Hypoparathyroidism
 - Hyperparathyroidism
60. **Increased bone density is seen in all except:**
- Primary hyperparathyroidism
 - Osteopetrosis
 - Fluorosis
 - Hypoparathyroidism
61. **"Flowing wax" appearance on anterior and posterior borders of vertebrae with normal intervertebral disc space occurring due to ligament calcification is seen in:**
- Ankylosing spondylitis
 - Diffuse idiopathic skeletal hyperostrophy
 - Psoriatic spondyloarthropathy
 - RA
62. **X-ray shows soap bubble appearance at lower end of radius treatment of choice is:**
- Local excision
 - Excision & Bone grafting
 - Amputation
 - RT
63. **Lytic lesion in skull are seen in following except:**
- Multiple myeloma
 - Metastasis bronchus
 - Thalassemia
 - Ca prostate
 - Chronophilic granuloma
64. **Osteolytic metastasis is seen with:**
- Lung
 - Kidney
 - Thyroid
 - All of the above
65. **A 70 years old female is on treatment with Alendronate for 7 years for osteoporosis. Now she complains of pain in right thigh. What is the next investigation to be performed?**
- DEXA scan
 - X-ray
 - Serum vitamin D levels
 - Serum alkaline phosphate levels
66. **Wimberger's sign is seen in?**
- Scurvy
 - Rickets
 - Congenital syphilis
 - Osteomalacia
67. **CT scan finding in carotid cavernous sinus fistula is:**
- Enlarged superior ophthalmic vein
 - Enlarged inferior ophthalmic vein
 - Enlarged superior ophthalmic artery
 - Enlarged inferior ophthalmic artery

Multiple Correct Answers

68. A 2-year-old boy suffering from leukemia, following are the X-ray finding:

- a. Osteolytic lesion in flat bones
- b. Metaphyseal osteoporosis
- c. Periosteal new bone formation
- d. Osteosclerosis of long bones
- e. Transverse line of dark band below the growth plate

69. All are radiological features of sickle cell anemia except:

- a. Vertebra plana
- b. Floating teeth
- c. Bone infarct

- d. Marrow hyperplasia
- e. Secondary osteomyelitis

70. Radiological features of rickets include:

- a. Narrowing of epiphysis
- b. Cupping of metaphysis
- c. Ricketic rosary
- d. Pelikan's spur

71. Radio iodine is used in treatment of:

- a. Papillary Ca thyroid
- b. Medullary Ca thyroid
- c. Follicular Ca thyroid
- d. Anaplastic Ca thyroid

ANSWER KEYS

1. **Ans. c.** Melorheostosis
2. **Ans. c.** Plain radiograph
3. **Ans. b.** Multiple myeloma
4. **Ans. d.** Achondroplasia
5. **Ans. c.** Multiple myeloma
6. **Ans. b.** Soap bubble appearance
7. **Ans. b.** Scurvy
8. **Ans. d.** Rickets > **c.** Rheumatoid arthritis
9. **Ans. c.** Areas of speculated microcalcifications
10. **Ans. a.** B/L mammogram
11. **Ans. c.** Young breasts have dense tissue
12. **Ans. c.** X-ray lumbar spine-AP view
13. **Ans. b.** Spondylolisthesis
14. **Ans. c.** Beheaded scotty dog terrier sign
15. **Ans. a.** Pseudogout
16. **Ans. c.** Osteomalacia
17. **Ans. a.** Ankylosing spondylitis
18. **Ans. b.** Soft tissue swelling
19. **Ans. c.** Turner syndrome
20. **Ans. a.** NF-1
21. **Ans. b.** Odontoid view
22. **Ans. a.** Most commonly involves 'thoracic spine
23. **Ans. a.** Eosinophilic granuloma
24. **Ans. d.** Abnormal curvature of cerebellum
25. **Ans. a.** Thalassemia
26. **Ans. a.** Epiphyseal widening
27. **Ans. b.** Sunray appearance
28. **Ans. d.** Driven-snow appearance
29. **Ans. b.** Aneurysmal bone cyst
30. **Ans. d.** Pelkan's spur.
31. **Ans. a.** Hypothyroidism
32. **Ans. b.** Aneurysmal bone cyst
33. **Ans. c.** Bone scan
34. **Ans. c.** Histiocytosis
35. **Ans. c.** Pseudogout
36. **Ans. a.** CT
37. **Ans. a.** Osteosarcoma
38. **Ans. a.** Osteosarcoma
39. **Ans. c.** MRI
40. **Ans. a.** Radiolucent transverse metaphyseal band
41. **Ans. c.** Non-rheumatic ankylosis
42. **Ans. b.** Papillary Ca
43. **Ans. d.** Pseudogout
44. **Ans. c.** Bone erosions
45. **Ans. b.** DEXA scan
46. **Ans. c.** Radiological examination of growing bone ends
47. **Ans. a.** Rickets
48. **Ans. c.** Rickets
49. **Ans. b.** MRI
50. **Ans. c.** Unicameral bone cyst
51. **Ans. d.** Lung nodules
52. **Ans. b.** Lead poisoning
53. **Ans. b.** Phalanges
54. **Ans. d.** Subperiosteal resorption of phalanges
55. **Ans. a.** Dual energy X-ray absorptiometry
56. **Ans. d.** Caffey's disease
57. **Ans. b.** Intradural extramedullary tumor
58. **Ans. b.** DIP joints in osteoarthritis
59. **Ans. b.** Psoriatic arthropathy
60. **Ans. a.** Primary hyperparathyroidism
61. **Ans. b.** Diffuse idiopathic skeletal hypertrophy
62. **Ans. b.** Excision & Bone grafting
63. **Ans. c.** Thalassemia **d.** Ca prostate
64. **Ans. d.** All of the above
65. **Ans. b.** X-ray
66. **Ans. c.** Congenital syphilis
67. **Ans. a.** Enlarged superior ophthalmic vein

Multiple Correct Answers

68. **Ans. a.** Osteolytic lesion in flat bones
c. Periosteal new bone formation **d.**
Osteosclerosis of long bones **e.** Trans-
verse line of dark band below the
growth plate

69. **Ans. a.** Vertebra plana **b.** Floating teeth

70. **Ans. b.** Cupping of metaphysis and
c. Ricketic rosary

71. **Ans. a.** Papillary CA thyroid **c.** Folli-
cular Ca thyroid

Section C

RADIOTHERAPY AND NUCLEAR SCANS

- **Radiotherapy and Chemotherapy**
- **Nuclear Scans**

mebooksfree.com

6

Radiotherapy and Chemotherapy

It is the treatment of various body ailments using radioactive sources. It is based on the interaction of ionizing particles with tissues at the molecular level.

Mechanism of Action

- Ionization of molecules by breaking the chemical bonds
- Direct DNA damage

Properties of Commonly Used Isotopes

| Isotope | Half-life | Use |
|---------|------------|---|
| Tc99m | 6 hours | Radionuclide scan |
| Ra-226 | 1622 years | For brachytherapy but not used nowadays |
| Co-60 | 5.26 years | Teletherapy & brachytherapy |
| Cs-137 | 30 years | Teletherapy & brachytherapy |
| Ir-192 | 74.2 days | Brachytherapy |
| I-125 | 60.2 days | Brachytherapy |
| I-123 | 13.2 hours | For thyroid scan (not available in India) |
| I-131 | 8 days | Systemic therapy for well differentiated thyroid cancer |
| P-32 | 14 days | Brachytherapy |
| Au-198 | 2.7 days | Brachytherapy |

Modes of Radiotherapy

- Teletherapy (External beam radiation therapy)—most commonly used therapy
- Brachytherapy
 - Interstitial
 - Intracavitary
 - Mold
- Systemic radiotherapy

Teletherapy

Generation of energy particles at some distance from the patient.

- Commonly used source for Teletherapy are **Cobalt – 60** and **CS-137**
- **Linear accelerators (currently best source for teletherapy)**
 - Capable of generating X-rays along with electrons.
 - Most patients are treated with megavoltage X-rays or gamma rays (photons), which are penetrating whereas electron beam is usually used for superficial tumors.
- Neutrons and proton

Inverse Square Law

The intensity of radiation from any source decreases by the square of the distance from the source.

Thus, if the radiation source is 10 cm above the skin surface and the tumor is 10 cm below the skin surface, the intensity of radiation in the tumor will be 25% of the intensity at the skin.

Types of External Beam Therapy

- Orthovoltage or deep X-ray therapy (200–400 kV)
 - Megavoltage therapy (2 to 8 million volts)
 - Supervoltage therapy
- Megavoltage therapy is preferred over orthovoltage therapy because of following advantages:
- **Skin sparing effects:** with orthovoltage X-rays, maximum dose is received by skin surface, whereas with high voltages, maximum dose is at some distance beneath skin; the skin is thus spared from high dose
 - Greater penetration of beam
 - Differential absorption in tissues; Greater penetration of energy in target volume
 - Improved collimation; Very low scatter

Uses of X-ray Beam

- 4- to 6-MeV X-rays or cobalt 60 gamma for tumors of head and neck, usually located at a depth of 7–8 cm.

- 15- to 25-MeV X-rays for cancers 12 to 15 cm deep, such as cancer of the prostate or uterine cervix.

Uses of Electron Beam

Poorer skin-sparing properties than photon beams

- 6-MeV electrons are commonly used for cancers of the skin or lip
- 6- to 9-MeV electrons for cervical lymph nodes over the spinal cord
- 9- to 12-MeV electrons for cancers of the buccal mucosa
- 15- to 18-MeV electrons for cancers of the tonsillar area or parotid gland.

Brachytherapy

Radioactive sources are placed within or close to the target volume.

- **Interstitial Brachytherapy:** These sources can be placed directly into the tumor and surrounding tissues, e.g. prostate cancer
- **Intracavitary Brachytherapy:** within body cavities, e.g. gynecological malignancies
- **Mold Brachytherapy:** onto epithelial surfaces, ocular malignancy.

Brachytherapy Implants are of Two Types

| Temporary implants (long-lived isotopes) | Permanent implants (short-lived isotopes) |
|---|---|
| Radium 226 Cesium 137 Iridium 192 | Cesium 133 Gold 198 Iodine 125 Palladium 103 ytterium |

Systemic Radiotherapy

- I-131 for well differentiated thyroid cancer
- P-32 for Polycythemia Rubra vera

Dosing Pattern

- Conventional fractionation (usually 5 days a week (Monday to Friday))
- Hyperfractionation RT: multiple doses of radiation (b.i.d. or t.i.d.) can be given to exploit the radiobiological advantages used in head and neck cancers and carcinoma of lung.

| Emission of Beta rays by | Both Beta+ gamma rays |
|-----------------------------|--------------------------|
| Ytterium | Gold |
| Phosphorus | I-131 |
| Strontium | Radium |

- Accelerated RT: over a shorter period of time; head and Neck cancer
- **CHART regimen: Continuous hyperfractionated accelerated radiotherapy; used in non-small cell lung cancer**
- Hypofractionation RT; palliation of advanced cancers; painful bone metastasis.

Types of Radiotherapy Treatment

Radical radiotherapy:

- Early stages of cancers at an aim to cure.
- The common tumors treated are:
 - Vocal cord cancer of larynx
 - Nasopharynx
 - Cancer of uterine cervix
 - Skin cancers
 - Bladder cancers
 - Breast cancers
 - Prostate cancers

Radical radiotherapy should be considered in patients with localized lung cancer if surgery is contra-indicated or refused. It is suitable for less than 5% of patients. Criteria for eligibility are as follows:

- Tumors 5 cm or less in maximum dimension
- Age less than 70 years
- Good general medical condition
- Adequate pulmonary function
- Non-small cell histology

Adjuvant radiotherapy

- To improve the results of other treatment usually surgery and ultimately survival
 - Before surgery (preoperative radiotherapy),
 - After surgery (postoperative radiotherapy),
 - During surgery (intraoperative radiotherapy)
 - Combination of preoperative and postoperative radiotherapy (sandwich radiotherapy)
- Commonly used in
 - Rectal cancers
 - Head and neck cancers
 - Breast cancers
 - Brain tumors
 - Most frequently used in postoperative set up.

Intraoperative radiotherapy (IORT)

- Very simple technique where radiation are delivered to the tumor bed after the removal of the tumor.
- Electrons are most commonly used for intraoperative radiotherapy.
- IORT seem to improve local control figures in retroperitoneal soft-tissue sarcomas, pancreatic cancers, and other abdominopelvic tumors where external radiation is not feasible in view of higher normal tissue complications. It is also used in Breast cancer.

Preoperative radiotherapy

- Carcinoma cervix
- Rectal cancer
- Inoperable non-small cell lung Ca

Postoperative radiotherapy

- Poorly differentiated tumors
- Positive tumor margins
- More depth of infiltration
- Positive nodes
- Multifocal tumors

Concurrent chemoradiotherapy

- Anti-neoplastic drugs like cisplatinum, 5FU and hydroxyurea when given in conjunction with radiotherapy, enhance the efficacy of radiation.
- When radiation given concurrently with chemotherapy the cancer cell kill increases twofold.

Commonly used in organ preservation techniques in

- Anal canal cancer, bladder cancer, esophageal cancer, nasopharyngeal cancer and cervical cancers

| Radiosensitizers | Radioprotectors |
|-----------------------------|-----------------|
| Metronidazole, misonidazole | Amifostine |
| Hyperbaric oxygen | Pentoxifyline |
| Cisplatin | Il-1 |
| 5 FU | GM-CSF |
| Gemcitabine | |
| hydroxyurea | |
| CYCLOPHOSPHAMIDE IS | |
| NOT | |

Chemosensitivity of tumors

Highly Chemosensitive^Q

- Teratoma testis
- Hodgkin's disease
- Non-Hodgkin's disease (high grade)
- Wilm's tumors
- Choriocarcinoma
- Acute lymphoblastic leukemia (ALL)

Relatively Insensitive

- Gastric carcinoma
- Bladder carcinoma
- Squamous cell carcinoma (head, neck)
- Soft tissue sarcoma
- Cervical carcinoma

Moderately Chemosensitive

- Ovarian cancer
- Small cell carcinoma lungs
- Non-Hodgkin's disease (low grade)
- Breast carcinoma
- Myeloma
- Acute myeloid leukemia (AML)

Extremely Resistant^Q

- Melanoma
- Squamous cell carcinoma lungs
- Large bowel carcinoma

Multi-modal (Holistic) Approach

- Many anticancer treatments are joined together to attack cancer cell in many ways called *multi-modal (holistic) approach* in cancer treatment.
- *Radiotherapy and surgery interval is kept between 4 to 6 weeks except for Wilms' tumor where radiotherapy should be started on 10th day.*
- *In Wilms' tumor initially nephrectomy is done then local radiotherapy on the 10th day and subsequently chemotherapy (VAC) for 12–24 months.*
- The other tumors treated by combined approach includes:
 - locally advanced breast cancer
 - cancer endometrium
 - soft tissue sarcoma.

Palliative Radiotherapy

- Cure is not possible

Used for:

- Painful bony metastasis (8 gy in single dose is preferred)
- Multiple brain metastasis
- SVC obstruction

| Curative therapy | Palliative therapy | Preventive therapy |
|--|--|--|
| <ul style="list-style-type: none"> • Hodgkin's disease • Head and neck cancer (larynx, oral cavity, pharynx) • prostate cancer • Gynecologic cancers (vagina, cervix) • Esophagus • Skin | <ul style="list-style-type: none"> • Relief of bone pain from metastatic disease • Control of brain metastases • Reversal of spinal cord compression • superior vena caval obstruction • shrinkage of painful masses • Opening of threatened airways | <ul style="list-style-type: none"> • Development of leptomeningeal disease and brain metastases in acute leukemia and lung cancer |

Modification/Advances in Radiotherapy

3D CRT (Conformal RT)

- To reduce radiation dose to the normal healthy tissue
- A CT scan is done first
- Planning of the field to be irradiated is done
- Skin marking is done for ensuring the same area is irradiated every time
- Used for tumors closed to important radiosensitive organ and structure of the body
 - Prostate cancer
 - Esophageal cancer
 - Lung cancer
 - Bladder cancer
 - Pancreatic cancer

INTENSITY-MODULATED RADIOTHERAPY (IMRT)

- Uses a multi-leaf collimator to shape the treatment area precisely to fit to the tumor shape.
- Microscopic cancer cells just outside the treatment area may not be destroyed.
- IMRT found useful in the treatment of small brain tumors, and head and neck cancers. It is best suitable for carcinoma of prostate.

STEREOTACTIC RADIOSURGERY

- High precision, stereotactically guided delivery of large dose of radiation in a single fraction
- Gamma knife' consisting of multiple cobalt-60 radioactive sources or X-rays from **linear accelerator**.

It is used for treating following lesions:

- Solitary cerebral metastasis
- Arteriovenous malformation
- Small meningiomas
- Schwannomas
- Pituitary adenomas

PROTON BEAM THERAPY

- **Highly specialized form of RT with proton beam accelerated toward the tumor tissue**
- **Used for**
 - Lung
 - Prostate
 - Brain
 - Spinal tumors

SIDE EFFECTS OF RADIOTHERAPY

- Most common radiation side effect is dermatitis
- Depends upon the field size, fraction size and the total dose of radiation.

| Early reacting tissues | Late reacting tissues |
|--------------------------------------|---|
| • Rapidly dividing cells | • Slowly dividing cells |
| • Mucosa and hematopoietic cells | • Stable cells like kidney, and brain |
| • Greater potentiality to regenerate | • Cannot regenerate |
| • Sub-lethal radiation damage | • Effects of radiation damage are permanent |
| • Immediately after radiotherapy | • 6 Months to years following radiotherapy |
| • e.g. Radiation sickness | • Rectal bleeding |
| • Mucositis and sore throat | • Hematuria |
| • Diarrhea | • Osteoradionecrosis |
| • Cystitis | • Radiation nephritis |
| • Vomiting | |
| • Fall in blood counts | |

Acute Effect of Total Body Radiation

| System affected | Dose | Time of death post exposure |
|---------------------------|-------------|-----------------------------|
| Hematopoietic syndrome | 2–8 gray | Weeks |
| Gastrointestinal syndrome | 5–12 gray | Days |
| Cerebrovascular syndrome | 20–100 gray | 24–48 hours |

GUIDE TO THE RELATIVE RADIOSENSITIVITY OF TISSUE

| | Most | Least |
|--|--|--|
| Stage of cell cycle | G2M > M | S |
| Organ | Ovary, testis | Vagina>bone>cns |
| Tissue | Gonads, bone marrow | Nervous tissue |
| Cell type (Law of Bergonie and Tribondeau) | Undifferentiated, well nourished highly metabolically active | Quiescent |
| Blood cell | Lymphocyte | Platelet |
| Retinal layer | Retinal vessel endothelium | Retinal pigmented epithelium > ganglion cell layer |

GUIDE TO THE RELATIVE RADIOSENSITIVITY OF TUMORS

| Highly Radiosensitive (WELMS) | Highly Resistant (HOMP) |
|-------------------------------|-------------------------|
| Wilms' tumor | Hepatoma |
| Ewing's sarcoma | Osteosarcoma |
| Lymphoma | Melanoma |
| Myeloma | Pancreatic Ca |
| Seminoma/dysgerminoma | |

FOLLOW-UP OF CANCER PATIENT RECEIVING RADIOTHERAPY

- Reappearances of the disease within 6 months are called residual disease

- Reappearances of the disease after 6 months are called recurrent disease
- Follow-up is usually done
- Every 2 months × 2 years
- Every 3 months × 3 years
- Every 6 months × 5 years
- Every year × 10 years

TREATMENT OF VARIOUS MALIGNANCIES

Surgery alone—treatment of choice:

- Lower esophagus, stomach, colon
 - Pancreas
 - Kidney
 - Thyroid
 - Melanoma
 - Hcc
 - Keratoacanthoma
-

Radiotherapy – the treatment of choice:

- Oral cavity, lip, tongue, cheek
 - Nasopharynx, oropharynx and hypopharynx
 - Nasal cavity
 - Larynx
 - Skin cancers (except melanoma)
 - Cervix
 - Bladder (except t1)
 - Testis – seminoma
 - Hodgkin's disease – early disease
 - Nhl – early disease
 - Medulloblastoma (following surgical resection)
 - Astrocytomas (grades 3 and 4)
 - Retinoblastoma
-

Chemotherapy – the treatment of choice:

- Acute and chronic leukemias
- HD (advanced)
- NHL (advanced)
- Testicular teratoma
- Choriocarcinoma
- Small cell lung cancer
- Rhabdomyosarcoma
- Neuroblastoma

QUESTIONS

- All of the following are pure beta emitters except:**
 - Yttrium-90
 - Phosphorus-32
 - Strontium-90
 - Samarium-153
- Amifostine is a:**
 - Radiosensitizer
 - Radioprotector
 - Radiomodifier
 - Radio modulator
- Stereotactic radiotherapy is used in:**
 - Miliary tuberculosis
 - Stage I lung carcinoma
 - Lymphangitis carcinomatosa
 - Carcinoma base of tongue with positive lymph nodes
- For radiotherapy an isotope is paced in or around cancer site. It is called as:**
 - Brachytherapy
 - Teletherapy
 - External beam therapy
 - Intensity-modulated radiotherapy
- Radionucleotide(s) used in external beam therapy:**
 - Iodine-131
 - Co-60
 - Cs137
 - Ra226
 - Ir192
- Stereotactic surgery is used for treatment of:**
 - Brain tumor
 - Lung carcinoma
 - Cervix cancer
 - Renal carcinoma
- That is atomic number:**
 - Proton
 - Electrons + protons
 - Proteins + neutrons
 - Protons + protons
- Substance with same atomic number but different mass number:**
 - Isotope
 - Isobar
 - Atom
 - Mineral
- Principle used in radiotherapy is:**
 - Cytoplasmic coagulation
 - Ionization of molecules
 - DNA damage
 - Necrosis of tissue
- Ionization radiation acts on tissue leading to:**
 - Linear acceleration injury
 - Excitation of electron from orbit
 - Formation of pyrimidine dimer
 - Thermal injury
- Functional basics of ionizing radiation depends on:**
 - Pyrimidine base pairing
 - Removal of orbital electron
 - Linear energy transfer
 - Adding orbital electron
- Most sensitive structure in cell for radiotherapy is:**
 - Cell membrane
 - Mitochondrial membrane
 - DNA
 - Enzymes
- Which of the following statements best describes 'Background Radiation'?**
 - Radiation in the background of nuclear reactors
 - Radiation in the background during radiological investigations
 - Radiation present constantly from natural sources
 - Radiation from nuclear fallout

14. Principles of linear accelerators are used in:
 - a. X-rays
 - b. Gamma rays
 - c. Alpha rays
 - d. Infrared rays
 - e. Alpha particles
15. Brachytherapy is:
 - a. Radiotherapy with the source of radiation outside the body well at a distance
 - b. External beam radiation therapy
 - c. Radiation source used in body cavities or implanted directly into the tissues
 - d. Per oral radiation therapy
16. Most commonly used rays for radiotherapy:
 - a. X-rays
 - b. γ -rays
 - c. α -rays
 - d. β -rays
17. Most commonly radiotherapy uses:
 - a. X-rays
 - b. Gamma rays
 - c. Alpha rays
 - d. Electron
18. The major difference between X-rays and light is:
 - a. Energy
 - b. Mass
 - c. Speed
 - d. Type of wave
19. Which one of the following has the maximum ionization potential?
 - a. Electron
 - b. Proton
 - c. Helium ion
 - d. Gamma Photon
20. Which of the following is the most penetrating beam?
 - a. Electron beam
 - b. 6 MV photons
 - c. 18 MV photons
 - d. Proton beam
21. Most harmful to individual cell:
 - a. X-rays
 - b. α -particles
 - c. p-particles
 - d. Gamma rays
22. For the treatment of deep seated tumors, the following rays are used:
 - a. X-rays and Gamma-rays
 - b. Alpha rays and Beta-rays
 - c. Electrons and positrons
 - d. High-power laser beams
23. Which of the following is used for permanent interstitial implant brachytherapy?
 - a. Boron
 - b. Cesium-131
 - c. Phosphorus
 - d. Iridium
24. Most common skin manifestation seen after 2 days of radiation therapy is:
 - a. Erythema
 - b. Atopy
 - c. Hyperpigmentation
 - d. Dermatitis
25. For teletherapy setup, all are used except:
 - a. Iridium 127
 - b. Cobalt 60
 - c. Simulator
 - d. Computer
26. Which is used in teletherapy and brachytherapy both:
 - a. Iridium 127
 - b. Cobalt 60
 - c. Padium
 - d. Iodine 131
27. Radioactive phosphorus is used in the treatment of:
 - a. Polycythemia rubraveria
 - b. Thyroid metastasis
 - c. Multiple myeloma
 - d. Embryonal cell carcinoma
28. Which of the following elements is obsolete in radiotherapy?
 - a. Radium 226
 - b. Cobalt 60
 - c. Iridium 192
 - d. Cesium 137
29. Features of interstitial radiotherapy are all except:
 - a. Only used in head and neck
 - b. Damage to normal tissue
 - c. Temporary or permanent
 - d. Only iridium used
 - e. Used for easily accessible organ

30. **MC cancer due to radiation:**
- Leukemia
 - Bronchogenic Ca
 - Thyroid Ca
 - Breast cancer
31. **Stereotactic radiosurgery uses all except:**
- Proton
 - Electron
 - Linear accelerator
 - Gamma knife
32. **Isotopes used in relief of metastatic bone pain includes:**
- Strontium 89
 - I-131
 - Gold-198
 - P-32
 - Rhenium-186
33. **The technique employed in radiotherapy to counteract the effect of tumor motion due to breathing is known as:**
- Arc technique
 - Modulation
 - Gating
 - Shunting
34. **Hyperfractionation radiotherapy is used in the management of:**
- Lung cancer
 - Breast cancer
 - Seminoma
 - Ovarian cancer
35. **Radiosensitizer drug(s) is/are:**
- Misonidazole
 - Actinomycin D
 - Oxygen
 - Hyperthermia
 - Amifostine
36. **Which of the following statements about stochastic effects of radiation is true?**
- Severity of effect is a function of dose
 - Probability of effect is a function of dose
 - It has a threshold
 - Erythema and cataract are common examples
37. **Most radiosensitive tissue of body among the following is:**
- Bone marrow
 - Spleen
 - Kidney
 - Brain
38. **Low-dose radiation causes:**
- Lung cancer
 - AML
 - Cervical cancer
 - Glioma
 - Meningioma
39. **Postradiation transverse myelitis usually presents at white urine after radiation therapy:**
- 1–2 weeks
 - 1–2 months
 - 4–6 months
 - 1 year
40. **The maximum permissible radiation exposure per year recommended by NCRP for radiation worker is:**
- 3 rad
 - 8 rad
 - 10 rad
 - 50 mSv
41. **Point A and point B Manchester location are important for treatment of which cancer:**
- Cervix
 - Vagina
 - Ovary
 - Uterus
42. **Maximum recommended external beam radiation therapy dose for a case of carcinoma cervix is:**
- 80 Gy
 - 70 Gy
 - 50 Gy
 - 35 Gy
43. **Photodynamic therapy with lemaporphyrins and light is increasingly used in treatment of:**
- Ovary Ca
 - Skin Ca
 - Colon Ca
 - All of the above
44. **The ideal timing of radiotherapy for Wilms' tumor after surgery is:**
- Within 10 days
 - Within 2 weeks

- c. Within 3 weeks
d. Any time after surgery
45. At $t = 0$, there are 6×10^{23} radioactive atoms of a substance, which decay with a disintegration constant equal to 0.01/sec. What would be the initial decay rate?
a. 6×10^{23} b. 6×10^{22}
c. 6×10^{21} d. 6×10^{20}
46. All are features of radiation except:
a. Biological
b. Photographic
c. Fluorescent
d. Nonpenetrating
47. Most stable radio-isotope among the following:
a. O-18 b. C-14
c. P-32 d. I-125
48. Which is not a deep heat therapy?
a. Short wave diathermy
b. Infrared
c. USG
d. Microwave
49. Radiation produces its effect on tissue by:
a. Coagulation of cytoplasm
b. Increasing the temperature
c. Charring of nucleoprotein
d. Hydrolysis
50. Gray equals:
a. 100 rad
b. 1000 rad
c. 10000 rad
d. 10 rad
51. Curie is unit of:
a. Radiation exposure
b. Radiation absorption
c. Radioactivity
d. All of the above
52. Most commonly radiotherapy uses:
a. X-rays b. γ -rays
c. α -rays d. Electron
53. Which of the following radioactive isotopes is not used for brachytherapy?
a. Iodine-125
b. Iodine-131
c. Cobalt-60
d. Iridium-192
54. Isotope used in radioactive iodine uptake is:
a. I131 b. I123
c. I125 d. I127
55. All of the following radioisotopes are used as systemic radionuclides except:
a. Phosphorus-32
b. Strontium-89
c. Iridium-192
d. Samarium-153
56. Which one of the following radioisotopes is not used as permanent implant?
a. Iodine-125
b. Palladium-103
c. Gold-198
d. Cesium-137
57. Radioisotopes are used in the following techniques except:
a. Mass spectroscopy
b. RIA
c. ELISA
d. Sequencing of nucleic acid
58. Which of the following radioisotopes is commonly used as a source for external beam radiotherapy in the treatment of cancer patients?
a. Strontium-89
b. Radium-226
c. Cobalt-59
d. Cobalt-60
59. Longest half life is seen in:
a. Radon b. Radium
c. Uranium d. Cobalt

60. The half life of Cobalt-60 is:
a. 3.4 years b. 5.2 years
c. 1.2 years d. 2.3 years
61. Half life of I131 is:
a. 4 hours b. 8 days
c. 4 days d. 10 days
62. The half life of Technetium is:
a. 6 hours b. 12 hours
c. 24 hours d. 26 hours
63. Radium emits which of the following radiations:
a. Alpha rays b. Beta rays
c. Gamma rays d. X-rays
e. Neutrons
64. Radiation emits by Ir-192:
a. 0.5 Mev b. 0.6 Mev
c. 0.66 Mev d. 0.666 Mev
e. 0.47 Mev
65. Phosphorus-32 emits:
a. Beta particles
b. Alfa particles
c. Neutrons
d. X-rays
66. Most suitable radioisotope of Iodine for treating hyperthyroidism is:
a. I123 b. I125
c. I131 d. I132
67. Maximum dose of radiation per year in a human which is safe is:
a. 1 rads b. 5 rads
c. 10 rads d. 20 rads
68. Maximum permissible radiation dose in pregnancy is:
a. 0.5 rad b. 1.0 rad
c. 1.5 rad d. 5 rad
69. Most sensitive tissue to radiaton is:
a. Liver b. Gonads
c. Spleen d. Skin
70. The cell most sensitive to RT:
a. Neutrophil b. Lymphocyte
c. Basophil d. Platelet
71. The radiation tolerance of whole liver is:
a. 15 Gy b. 30 Gy
c. 40 Gy d. 45 Gy
72. Most radiosensitive stage:
a. S phase b. G1 phase
c. G2 phase d. G2M phase
73. Photon transferring some of its energy to electron is:
a. Photoelectric effect
b. Bremsstrahlung effect
c. Compton effect
d. Ionization
74. Photoelectric effect is:
a. Interaction between high energy incident photon and the inner shell electron
b. Interaction between the low energy incident photon and the inner shell electron
c. Interaction of the incident photon with the nucleus
d. Interaction between a photon and electric current
75. Ionising radiation is most sensitive in:
a. Hypoxia b. S phase
c. G2M phase d. Activating cell
76. Most radiosensitive stage of cell cycle:
a. G1 phase
b. G2M interphase
c. Early S phase
d. Late S phase
e. M phase
77. What is radioresistant?
a. Cartilage
b. Seminoma
c. Ewing's sarcoma
d. GI epithelium
78. Which of the following is the most radiosensitive tumor?
a. Ewing's tumor
b. Hodgkin's disease

- c. Carcinoma cervix
d. Malignant fibrous histiocytoma
79. **Most radiosensitive ovarian tumor is:**
a. Serus cystadenoma
b. Dysgerminoma
c. Dermoid cyst
d. Teratoma
80. **Most radiosensitive brain tumor is:**
a. Astrocytoma
b. Ependymoma
c. Medulloblastoma
d. Craniopharyngioma
81. **Most radiosensitive tumor is:**
a. Brenner's tumor
b. Dysgerminoma
c. Mucinous cystadenoma
d. Teratoma
82. **All are highly radiosensitive except:**
a. Osteogenic sarcoma
b. Lymphoma
c. Ewing's sarcoma
d. Seminoma
83. **Most radiosensitive testicular tumor is:**
a. Yolk sack tumor
b. Embryonal cell tumor
c. Teratoma
d. Seminoma
84. **Most radiosensitive lung CA is:**
a. Sqamous cell
b. Small cell
c. Adeno cell
d. Large cell
85. **The most radiosensitive tumor among the following is:**
a. Bronchogenic carcinoma
b. Carcinoma parotid
c. Dysgerminoma
d. Osteogenic sarcoma
86. **Which of the following malignant tumors is radioresistant?**
a. Ewing's sarcoma
b. Retinoblastoma
c. Osteosarcoma
d. Neuroblastoma
87. **Most radiosensitive tumor of the following is:**
a. Ca Kidney b. Ca Colon
c. Ca Pancreas d. Ca Cervix
88. **Tumor(s) most responding to radiotherapy:**
a. Sarcoma b. Seminoma
c. Lymphoma d. Leukemia
89. **Tumor responding best to radiation includes the following:**
a. Melanoma
b. Dysgerminoma
c. Teratoma
d. Choriocarcinoma
90. **All are chemosensitive except:**
a. Small Cell CA
b. Ca Cervix
c. Ewing's tumor
d. Malignant melanoma
91. **Radiation exposure during infancy has been linked to which of the following carcinomas:**
a. Breast b. Melanoma
c. Thyroid d. Lung
92. **Least amenable to screening is:**
a. Breast CA
b. Cervix CA
c. Lung CA
d. Oral cavity CA
93. **Craniospinal irradiation is used in the treatment of:**
a. Oligodendroglioma
b. Pilocytic astrocytoma
c. Mixed oligoastrocytoma
d. Meduoblastoma
94. **Prophylactic cranial irradiation is not indicated in treatment of:**
a. Small cell Ca of lung
b. ALL
c. Hodgkin's lymphoma
d. NHL

95. **Prophylactic intracranial irradiations are given in:**
- Small cell Ca of lung
 - Testicular Ca
 - Ca breast
 - Ca stomach
96. **Stereotactic radiosurgery is a form of:**
- Radiotherapy
 - Radioiodine therapy
 - Robotic surgery
 - Cryosurgery
97. **Gamma knife:**
- Steel knife
 - Used for cutting tumors in difficult location
 - Cobalt is used
 - Recovery delayed
98. **Radiation therapy to hypoxic tissues may be potentiated by the treatment with:**
- Mycostatin
 - Metronidazole
 - Methotrexate
 - Melphalan
99. **For which malignancy is Intensity Modulated Radiotherapy (IMRT) the most suitable?**
- Lung
 - Prostate
 - Leukemias
 - Stomach
100. **All are radiosensitizers except:**
- 5-Fu
 - BUDR
 - Cyclophosphamide
 - Hydroxyurea
101. **Which of the following is not an indication of RT in pleomorphic adenoma of parotid?**
- Involvement of deep lobe
 - Second histologically benign recurrence
 - Microscopically positive margins
 - Malignant transformation
102. **For mobile tumor of vocal cord treatment of choice is:**
- Surgery
 - Chemotherapy
 - Radiotherapy
 - None
103. **What dose of radiation therapy is recommended for pain relief in bone metastases?**
- 8 Gy in one fraction
 - 20 Gy in 5 fractions
 - 30 Gy in 10 fractions
 - Above 70 Gy
104. **In which malignancy is postoperative radiotherapy minimally used?**
- Head and neck
 - Stomach
 - Colon
 - Soft tissue sarcomas
105. **Radioprotective drug is:**
- Paclitaxem
 - Vincristine
 - Amifostine
 - Etoposide
106. **Intercavitary radiotherapy is treatment modality for:**
- Ca Cervix
 - Ca esophagus
 - Ca Stomach
 - Renal cell Ca
107. **Point B in treatment of Ca cervix corresponds to:**
- Mackenrodt's ligament
 - Obturator lymph node
 - Ischial tuberosity
 - Round ligament
108. **A patient with cancer received extreme degree of radiation toxicity. Further history revealed that the dose adjustment of a particular drug was missed during the course of radiotherapy. Which of the following drugs required a dose adjustment in that patient during radiotherapy in order to prevent radiation toxicity?**
- Vincristine
 - Dactinomycin
 - Cyclophosphamide
 - 6-Mercaptopurine

109. **Amifostine protects all of the following except:**
- CNS
 - Salivary glands
 - Kidneys
 - GIT
110. **Which of the following is used in the treatment of differentiated thyroid cancer?**
- I-131
 - Tc-99
 - P₃₂
 - MIBG
111. **Most common presentation of radiation carditis is:**
- Pyogenic Pericarditis
 - Pericardial Effusion
 - Myocardial Fibrosis
 - Atheromatous Plaque
112. **Most common hormone deficiency seen after intracranial radiation therapy:**
- Prolactin
 - Gonadotropins
 - ACTH
 - Growth hormone
113. **Photoelectric effect can be best described as an:**
- Interaction between high energy incident photon in the outer shell electron
 - Interaction between low energy incident photon and the outer shell electron
 - Interaction of the high energy incident photon and the outer shell electron
 - Interaction between a low energy incident photon and the inner shell electron
114. **Phase of the cell cycle which is most sensitive to radiation:**
- S
 - G1
 - G2M
 - G0
115. **Which of the following statements is true:**
- γ -rays are produced from linear accelerator
 - γ -rays are produced by orbital electrons
 - X-rays are produced from Co-60
 - X-rays and γ -rays have similar
116. **Photon transferring some of its energy to electron is:**
- Photoelectric effect
 - Bremsstrahlung effect
 - Compton effect
 - Ionization
117. **Which is provided by linear accelerator**
- Electron
 - Neutron
 - Proton
 - Infrared rays
118. **Phosphorous 32 emits:**
- Beta particle
 - Alpha particle
 - Neutron
 - X-rays
119. **High energy accelerator produces:**
- X-ray
 - Electron
 - Gamma rays
 - Neutron
 - Proton
120. **Radioresistant tumor is:**
- Ewing's sarcoma
 - Retinoblastoma
 - Osteosarcoma
 - Neuroblastoma
121. **All of the following modalities can be used for in situ ablation of liver secondaries, except:**
- Ultrasonic waves
 - Cryotherapy
 - Alcohol
 - Radiofrequency
122. **Most commonly used isotope for treatment of bone cancer:**
- Pb86
 - I-125
 - Cr-51
 - Sr-89

Multiple Correct Answers

123. Radioactive substance emits the following except:
- Gamma
 - Beta
 - Alpha
 - X rays
124. For teletherapy, isotopes commonly used are:
- 1-123
 - Cs-137
 - CO-60
 - Tc-99
 - Ir-191
125. Used in radiotherapy:
- I-131
 - Co-60
 - Ir-192
 - Id-125
126. Features of interstitial therapy are all except:
- Only used in head and neck
 - Damage to normal tissue
 - Temporary or permanent
 - Only iridium used
 - Used for easily accessible organ
127. Artificial radioisotopes:
- Radium
 - Uranium
 - Plutonium
 - Iridium
 - Cobalt
128. Radioactive isotopes that are used in treatment of cancer are:
- Cesium
 - Cobalt
 - Carbon
 - Technetium
 - Nitrogen
129. Isotopes used for radiotherapy:
- Radon
 - Cobalt-60
 - Iridium
 - Cesium
130. Organs sensitive to radiation are:
- Gonad
 - Bone marrow
 - Liver
 - Fat
 - Nervous tissue
131. Radiosensitive tumors are:
- Seminoma
 - Lymphoma
 - Sarcoma
 - Ewing's sarcoma
 - Leukemia
132. Advantage of brachytherapy:
- Noninvasive
 - Less radiation hazard to normal tissue
 - Maximum radiation to diseased tissue
 - Can be given in all malignancies
 - Doesn't require trained personnel
133. Radiotherapy is used for which stage-I cancer?
- Colon
 - Larynx
 - Anterior 2/3 of tongue
 - Lung
 - Stomach
134. Intraoperative RT is given in:
- Ca Cervix
 - Ca Breast
 - Ca Pancreas
 - Ca Thyroid
135. Emergency radiotherapy is given in:
- Superior vena cava syndrome
 - Pericardial tamponade
 - Increased ICP
 - Spinal cord compression
136. Late effects of radiation therapy:
- Mucositis
 - Enteritis
 - Nausea and vomiting
 - Pneumonia
 - Somatic mutations

ANSWER KEYS

1. **Ans. d.** Samarium-153
 2. **Ans. b.** Radioprotector
 3. **Ans. b.** Stage I lung carcinoma
 4. **Ans. a.** Brachytherapy
 5. **Ans. b.** Co-60, **c.** Cs137, **e.** Ir192
 6. **Ans. b.** Lung carcinoma
 7. **Ans. a.** Proton
 8. **Ans. a.** Isotope
 9. **Ans. b.** Ionization of molecules
 10. **Ans. b.** Excitation of electron from orbit
 11. **Ans. b.** Removal of orbital electron
 12. **Ans. c.** DNA
 13. **Ans. c.** Radiation present constantly from natural sources
 14. **Ans. a.** X-rays
 15. **Ans. c.** Radiation source used in body cavities or implanted directly into the tissues
 16. **Ans. a.** X rays, **b.** γ -rays, **c.** α -rays, **d.** β -rays
 17. **Ans. a.** X-rays
 18. **Ans. a.** Energy
 19. **Ans. c.** Helium ion
 20. **Ans. c.** 18 MV photons
 21. **Ans. b.** α -particles
 22. **a.** X-rays and Gamma-rays
 23. **Ans. b.** Cesium-131
 24. **Ans. a.** Erythema
 25. **Ans. a.** Iridium
 26. **Ans. b.** Cobalt 60
 27. **Ans. a.** Polycythemia rubra vera
 28. **Ans. a.** Radium 226
 29. **Ans. a.** Only used in head and neck, **b.** Damage to normal tissue, **d.** Only iridium used
 30. **Ans. a.** Leukemia
 31. **Ans. b.** Electron
 32. **Ans. a.** Strontium 89
 33. **Ans. c.** Gating
 34. **a. Lung cancer**
 35. **Ans. a.** Misonidazole, **b.** Actinomycin D, **c.** Oxygen
 36. **Ans. b.** Probability of effect is a function of dose
 37. **Ans. a.** Bone marrow
 38. **Ans. b.** AML
- For decades, researchers have been trying to quantify the risks of very low doses of ionizing radiation—the kind that might be received from a medical scan, or from living within a few tens of kilometres of the damaged Fukushima nuclear reactors in Japan. So small are the effects on health—if they exist at all—that they seem barely possible to detect. A landmark international study has now provided the strongest support yet for the idea that long-term exposure to low-dose radiation increases the risk of leukaemia, although the rise is only minuscule (K. Leuraud et al. *Lancet Haematol.* <http://doi.org/5s4>; 2015). ICRP recommendations, which most national radiation-protection agencies follow, already call for monitoring of individuals whose annual exposure is likely to exceed 6 mSv. They restrict exposure to 20 mSv annually over 5 years, with a maximum of 50 mSv in any one year. Researchers found that 531 of the workers died from leukaemia during the average 27 years they spent in the industry; the data suggest that 30 of those deaths could be attributed to the radiation. Even in this large study, there was no direct evidence that workers who had accumulated extremely low doses of radiation (below a total of 50 mSv) had an increased risk of leukaemia,

says Olsen. But a mathematical extrapolation of the data suggests that each accumulation of 10 mSv of exposure raised a worker's risk of leukaemia by around 3%, compared to the average risk of the group of workers in the study.

39. **Ans. d.** 1 year

40. **Ans. d.** 50 mSv

41. **Ans. a.** Cervix

42. **Ans. c.** 50 Gy

The risk of major complications is increased when the dose of whole-pelvic radiation exceeds 40 Gy at 2 Gy per fraction or 45 Gy at 1.8 Gy per fraction. There is no clear evidence that fraction sizes of less than 2 Gy significantly decrease the rate of late complications, although daily fractions of 1.8 Gy may reduce the severity of acute radiation effects when large treatment fields or concurrent chemotherapy is used. Although 40–45 Gy is usually sufficient to control microscopic tumor in the pelvis, additional treatment must be given to control gross disease. ICRT is used to deliver a high dose to cancer in the cervix; enlarged pelvic nodes or lateral parametrial tumor may lie beyond the high-dose range of ICRT (intracavitary radiation therapy) but may be given additional treatment with small external-beam fields.

Jhingran, A, Eifel, P, Glob. libr. women's med., (ISSN: 1756-2228) 2008; DOI 10.3843/GLOWM.10234

43. **Ans. b.** Skin cancer

Photodynamic therapy (PDT) is a treatment that involves the use of a light-sensitive medication and a light source to destroy abnormal cells.

It can be used to treat some skin and eye conditions, as well as certain types of cancer.

On their own, the medication and light source are harmless, but when the medication is exposed to the light, it activates and causes a reaction that damages nearby cells.

This allows small abnormal areas of tissue to be treated without the need for surgery.

PDT can be used to treat abnormalities in parts of the body a light source can most easily reach, such as the skin, eyes, mouth, oesophagus (light reaches by endoscope) and lungs.

44. **Ans. a.** Within 10 days

45. **Ans. c.** 6×10^{21}

46. **Ans. d.** Nonpenetrating

47. **Ans. a.** 0-18

48. **Ans. b.** Infrared

49. **Ans. c.** Charring of nucleoprotein

50. **Ans. a.** 100 rad

51. **Ans. c.** Radioactivity

52. **Ans. a.** X-rays

A high-energy photon beam is by far the most common form of radiation used for cancer treatment. It is the same type of radiation that is used in X-ray machines, and comes from a radioactive source such as cobalt, cesium, or a machine called a linear accelerator (linac, for short). Photon beams of energy affect the cells along their path as they go through the body to get to the cancer, pass through the cancer, and then exit the body.

American cancer society

53. **Ans. b.** Iodine-131

54. **Ans. b.** I123

55. **Ans. c.** Iridium-192

56. **Ans. d.** Cesium-137

57. **Ans. c.** ELISA

58. **Ans. d.** Cobalt-60

59. **Ans. c.** Uranium

60. **Ans. b.** 5.2 years

61. **Ans. b.** 8 days

62. **Ans. a.** 6 hours
63. **Ans. a.** Alpha rays, **b.** Beta rays, **c.** Gamma rays
64. **Ans. e.** 0.47 Mev
65. **Ans. a.** Beta particles
66. **Ans. c.** I131
67. **Ans. b.** 5 rads
68. **Ans. a.** 0.5 rad
69. **Ans. b.** Gonads
70. **Ans. b.** Lymphocyte
71. **Ans. c.** 40 Gy
72. **Ans. d.** G2M phase
73. **Ans. c.** Compton effect
74. **Ans. b.** Interaction between the low energy incident photon and the inner shell electron
75. **Ans. c.** G2M phase
76. **Ans. b.** G2M interphase
77. **Ans. a.** Cartilage
78. **Ans. a.** Ewing's tumor
79. **Ans. c.** Dermoid cyst
80. **Ans. c.** Medulloblastoma
81. **Ans. b.** Dysgerminoma
82. **Ans. a.** Osteogenic sarcoma
83. **Ans. d.** Seminoma
84. **Ans. b.** Small cell
85. **Ans. c.** Dysgerminoma
86. **Ans. c.** Osteosarcoma
87. **Ans. d.** Ca Cervix
88. **Ans. b.** Seminoma, **c.** Lymphoma, **d.** Leukemia
89. **Ans. b.** Dysgerminoma
90. **Ans. d.** Malignant melanoma
91. **Ans. c.** Thyroid
92. **Ans. c.** Lung CA
93. **Ans. d.** Meduoblastoma
94. **Ans. c.** Hodgkin's lymphoma
95. **Ans. a.** Small cell Ca of lung
96. **Ans. a.** Radiotherapy
97. **Ans. c.** Cobalt is used
98. **Ans. b.** Metronidazole
99. **Ans. b.** Prostate
100. **Ans. c.** Cyclophosphamide
101. **Ans. d.** Malignant transformation
102. **Ans. c.** Radiotherapy
103. **Ans. a.** 8 Gy in one fraction
104. **Ans. b.** Stomach
105. **Ans. c.** Amifostine
106. **Ans. a.** Ca Cervix
107. **Ans. b.** Obturator lymph node
108. **Ans. b.** Dactinomycin
109. **Ans. a.** CNS
110. **Ans. a.** I-131
111. **Ans. b.** Pericardial Effusion
112. **Ans. d.** Growth hormone
113. **Ans. d.** Interaction between a low energy incident photon and the inner shell electron
114. **Ans. c.** G2M
115. **Ans. d.** X-rays and γ -rays have similar properties
116. **Ans. c.** Compton effect
117. **Ans. a.** Electron
118. **Ans. a.** Beta particle
119. **Ans. a.** X-ray, **b.** Electron and **e.** Proton
120. **Ans. c.** Osteosarcoma
121. **Ans. a.** Ultrasonic waves
122. **Ans. d.** Sr-89
- Multiple Correct Answers**
123. **Ans. a.** Gamma, **b.** Beta, **c.** Alpha, **d.** X-rays
124. **Ans. b.** Cs-137
125. **Ans. a.** I-131, **b.** Co-60, **c.** Ir-192 **d.** Id-125
126. **Ans. c.** Temporary or permanent, **e.** Used for easily accessible organ
127. **Ans. d.** Iridium, **e.** Cobalt
128. **Ans. a.** Cesium, **b.** Cobalt
129. **Ans. a.** Radon, **b.** Cobalt-60, **c.** Iridium, **d.** Cesium
130. **Ans. a.** Gonad, **b.** Bone marrow, **c.** Liver
131. **Ans. a.** Seminoma, **b.** Lymphoma, **d.** Ewing's sarcoma

132. **Ans. b.** Less radiation hazard to normal tissue, **c.** Maximum radiation to diseased tissue
133. **Ans. b.** Larynx, **c.** Anterior 2/3 of tongue, **d.** Lung
134. **Ans. b.** Ca Breast, **c.** Ca Pancreas
135. **Ans. a.** Superior vena cava syndrome, **b.** Pericardial tamponade, **c.** Increased ICP, **d.** Spinal cord compression
136. **Ans. b.** Enteritis, **d.** Pneumonia, **e.** Somatic mutations

Nuclear Scans

Nuclear Medicine

Nuclear scans are different from radiological scans as in nuclear medicine studies, a radiopharmaceutical substance is administered, that is known to target a certain organ or organs. Its distribution is then examined to determine any pathologic condition in that particular organ.

| | |
|---------------------------|--------------------------------|
| Radiological studies | Nuclear scans |
| Predominantly uses X-rays | Gamma rays for imaging |
| Outside to inside | Inside to outside |
| Anatomical scans | Physiological/functional scans |
| E.g. CT scan | Bone scan |

Most commonly used Radionuclide is Tc 99m

- Technetium-99m fulfills criteria of an ideal radionuclide.
- **Short half life of 6 hours**
- **Predominant emission of gamma rays of energy 140-keV**
- Tc-99m is obtained from the parent 99Mo (67-hour half-life)
- Taken up by salivary glands, choroid plexus, thyroid gland, gastric mucosa, and functioning breast tissue.
- Can cross placenta

Gamma camera, aka Anger's camera is used to capture gamma photons generated by the radionuclide in the patient. It converts photons into a light pulse and subsequently into a voltage signal. This signal is used to form an image of the distribution of the radionuclide.

Radionuclide Scans

1. Renal Scan

- **DTPA** (Diethylene triamine Penta acetic acid) is excreted through glomerular filtration and is the agent of choice for assessment of;
 - GFR
 - Vesicoureteral reflux
 - Perfusion
 - Obstructive uropathy
- **Tc-99m Mercaptoacetyltriglycine (MAG3)** is a better agent for measurement of renal function as it has some tubular excretion as well but it is costly.
- **Tc-99m DMSA** (dimercaptosuccinic acid) is suitable for imaging of; functioning cortical mass pseudotumor versus the lesion. It is also the agent of choice for evaluation of scar in the kidney. It is also the agent of choice for differential renal function.
- **I-131 OIH (Orthoiodohippurate)**-Largely replaced by Tc -99m MAG3 used for evaluation of Renal tubular function/effective renal plasma flow.

2. MDP Bone scan

- Used to evaluate cancer spread to osseous sites.
- Sensitive but relatively nonspecific
- False positive in healing fractures, arthritis, Paget's disease.

Three-phase bone scan (99mTc-MDP): Characteristic finding in osteomyelitis: increased uptake in all three phases of scan.

- Highly sensitive in acute infection.

3. Meckel's scan

Perchnetate is taken up by the gastric mucosa and is the agent of choice for evaluation of ectopic gastric mucosa of Meckel's diverticulum.

4. GI nuclear imaging:

- Tc 99m RBC scintigraphy localize bleeding sites in patients with brisk hemorrhage so can be used to pick up intermittent bleeding.
- The sensitivity is more than catheter angiography with bleeding rate as low as 0.05 mL/min can be picked up.

MRI is the most accurate investigation to assess ventricular function

5. V-P (Ventilation-perfusion) scan

Radioisotope scan in the form of V-P (Ventilation-perfusion) scan is the 2nd line **investigation** for the diagnosis of pulmonary thromboembolism. CT angiography is the investigation of choice for diagnosis of pulmonary embolism.

6. Heart imaging

Multiple-gated blood pool imaging (MUGA), also known as, Equilibrium radionuclide angiography,

- Provides an accurate, reproducible method for assessment of LV function.
- Most commonly used when echocardiography is technically difficult or when poor LV function requires accurate quantitation.
- **Involves the imaging of 99mTc-labeled** albumin or red cells that are uniformly distributed throughout the blood volume.

Requires that the heart rate be reasonably constant.

a. Advantages of MUGA scan are:

- Higher information density than 1st pass method
- Assessment of pharmacological effect possible
- "Bad beat" rejection possible

b. Disadvantages of MUGA scan are:

- Significant background activity
- Inability to monitor individual chambers
- Plane of AV valve difficult to identify

a. Myocardial Ischemia & viability can be studied:

- i. **Directly** with myocardial perfusion imaging by
 - Thallium-201 chloride SPECT imaging
 - Tc-99m sestamibi/tetrofosmin SPECT imaging
 - PET

ii. **Indirectly** with ventricular function imaging by

- Multigated acquisition scan (**MUGA**)
- First pass radionuclide coronary Angiography

iii. **Simultaneous** assessment of myocardial perfusion + ventricular function by

- First pass radionuclide angiography + gated **SPECT** perfusion imaging

FDG PET is considered to be the best noninvasive technique to assess cardiac viability.

7. Biliary Scintigraphic Scan

Hepatic Iminodiacetic acid scan (**HIDA Scan**) is a biliary scintigraphic scan. ^{99m}Tc acetanilide iminodiacetic acid analogs are HIDA agents and depending on their lipophilicity, there is a trade-off between renal excretion & hepatic uptake (HIDA is least lipophilic).

Applications & indications include:^o

- Acute cholecystitis (**Gold standard**) USG is preferred nowadays for diagnosis because of the ease of performance
- Congenital biliary atresia (Excretion of the day) in the duodenum rules out biliary atresia; May be false positive in severe neonatal hepatitis.)
- Biliary leak evaluation
- Biliary-enteric fistula
- Chronic GB dysfunction

8. Thyroid Scan

I^{123} is a preferred agent due to short half life and only gamma emission. In India, Tc 99m is used due to nonavailability of I^{123} .

- Hot nodule → Adenoma and thyroid carcinoma (extremely rare)
- Cold thyroid nodule → Inflammatory mass, Benign tumor and Malignant tumor

9. Brain scan

– Brain Tumors

- Localized defect on SPECT imaging in Both primary and metastatic brain lesions
- **In the differentiation** of recurrent malignant glioma from radiation necrosis

– Epilepsy

- For evaluation of focus of intractable epilepsy like mesial temporal sclerosis which is the most common pathology
- **PET imaging using FDG** is the method of choice for evaluating metabolism, whereas SPECT imaging with ^{99m}Tc perfusion agents, such as HMPAO or ECD, appears to be the method of choice for evaluation of perfusion status.

10. Positron Emission Tomography (PET)/18-F DG PET SCAN

- Positron is a positively charged electron. No Tc is used in the PET scan.
- Fluorine-18 (F-18) is most commonly preferred. To make the agent to go specifically to the site of interest, F-18 is coupled with deoxyglucose which gets more concentrated in malignant cells as they have much more metabolic demand compared to normal cells.
- 18 F is a Positron emitter which interacts with an electron and cause the release of gamma-radiation (photons) upon collision with tissue. It is this gamma emission that is detected in the PET scanner.
- **Basic principle:** Coincidence detection of paired high energy (511KeV) annihilation gamma photons from **positron emitting radionuclides** like carbon-11, nitrogen-13, oxygen-15 and fluorine-18.⁹
- **PET camera:** Routine gamma camera is not used for PET imaging. PET detectors are made up of special material, called **BGO (Bismuth germinate) crystals**, which sensitively and specifically detects the high energy (511 kev) gamma photons produced after electron and emitted positron combine with each other.

a. Advantages of PET:

- It is a 'unique tool' to study and quantify physiological and pathological function of human tissues and organs.
- Imaging modality that permits noninvasive in vivo examination of metabolism (biochemical imaging), blood flow, electrical activity and neurochemistry:
- Most accurate noninvasive method of detecting and evaluating most cancers.

b. Clinical Applications of PET:

1. Oncology; 2. Neurology; 3. Cardiology
1. Oncologic (Glucose and oxygen utilization of tumors measured)
 - Lung cancer and pancreatic cancer
 - Differentiation of incidentalomas from metastasis in adrenals
 - Breast cancer

- Colon cancer recurrence
- LN metastasis from head and neck cancer
Residual/recurrent tumor versus neurosis
- Response to chemoradiation
- Lymphoma staging
- 2. Neurology
 - Quantification of cerebral blood flow
 - Functional imaging of brain.
- 3. Cardiology
 - Myocardial Perfusion of the heart using Rubidium-82 tracer
 - Myocardial Perfusion of the heart using Ammonia N-13 tracer
 - Myocardial Viability using FDG: Hibernating myocardium uses glucose for metabolism

| Clinical problem | Imaging technique | Radiopharmaceutical | Biological behavior |
|---|---------------------------------|--------------------------------------|--|
| 1. Head | | | |
| Epilepsy (presurgical localization) | Ictal SPECT | ^{99m} Tc HMPAO | Uptake proportional to blood flow |
| | Cerebral metabolism PET | ¹⁸ F fluorodeoxyglucose | Marker of glucose metabolism |
| | Interictal PET | ¹⁸ F fluorodeoxyglucose | Marker of glucose metabolism |
| Dementia | Cerebral perfusion SPECT | ^{99m} Tc HMPAO | Uptake proportional to blood flow |
| Cerebrovascular accident | Cerebral perfusion SPECT | ^{99m} Tc HMPAO | Uptake proportional to blood flow |
| Hydrocephalus CSF rhinorrhea Encephalitis | Cerebrospinal fluid (CSF) study | ¹¹¹ In DTPA (intrathecal) | Marker of CSF flow. |
| | Blood-brain barrier (BBB) study | ^{99m} Tc HMPAO | Passage across disrupted BBB |
| 2. Neck | | | |
| Hyperparathyroidism (presurgical localization) | Parathyroid scintigraphy | ^{99m} Tc MIBI | Differential expression of p-glycoprotein between parathyroid adenoma and thyroid |
| Thyrotoxicosis | | ¹²³ I sodium iodide | Active uptake (¹²³ I and ^{99m} Tc) followed by organification (¹²³ I) |
| Thyroid nodule Ectopic thyroid | Thyroid scintigraphy | ^{99m} Tc pertechnetate | |

Contd...

Contd...

| Clinical problem | Imaging technique | Radiopharmaceutical | Biological behavior |
|--|--|--|---|
| Dry mouth (connective tissue disease) | Salivary gland study | ^{99m} Tc pertechnetate | Secretion in saliva |
| 3. Musculoskeletal system | | | |
| Tumor Fracture Avascular necrosis Arthropathy | Bone scintigraphy | ^{99m} Tc polyphosphate compounds | Osteoblastic response (+ vascularity on early phases) |
| Lymphedema | Lymphoscintigraphy | ^{99m} Tc nanocolloid | Lymphatic uptake and trapping |
| Metabolic bone disease | | | |
| Painful prosthesis Osteomyelitis | Bone scintigraphy + white cell or gallium scintigraphy | ^{99m} Tc polyphosphate | Osteoblastic activity |
| | | ^{99m} Tc- or ¹¹¹ In-leucocytes | Leucocyte migration |
| | | ⁶⁷ Ga gallium citrate | Binds to transferrin and leaks into extravascular space |
| 4. Cardiovascular system | | | |
| Pulmonary embolism | Ventilation/perfusion (V/Q) scan | ¹²³ I fatty acids | |
| | | Perfusion: ^{99m} Tc albumin | Pulmonary arteriole blockade |
| | | Macroaggregates | |
| | | Ventilation: ^{99m} Tc aerosols | Distributes in lungs in proportion to gas regional ventilation |
| | | ¹³³ Xe gas, ^{81m} Kr gas | |
| Chest pain | Myocardial perfusion scan | ²⁰¹ Tl (thallous chloride) | K ⁺ analogue indicating perfusion (ischemic heart disease) (delayed uptake reflects viability) |
| | | ^{99m} Tc isonitriles | Cationic complexes taken up by myocytes in proportion to blood flow |
| | | ^{99m} Tc teboroxime | Lipophilic compound which accumulates by diffusion |
| | | ^{99m} Tc phosphines | Uptake proportional to blood flow |

Contd...

Contd...

| Clinical problem | Imaging technique | Radiopharmaceutical | Biological behavior |
|---------------------------------------|--|--|--|
| Cardiac failure | Cardiac ventriculography (gated study) | ^{99m}Tc red blood cells | Blood pool label |
| | Myocardial viability study | ^{18}F fluorodeoxyglucose | Demonstrates shift from metabolism of fatty acids to glucose |
| Congenital heart disease | Quantitative shunt study | ^{99m}Tc red blood cells | Blood pool label |
| 5. Pulmonary system | | | |
| Solitary pulmonary nodule | Tumor imaging | ^{18}F fluorodeoxyglucose | Marker of glucose metabolism |
| Occult lung disease (alveolitis) | Alveolar permeability study | ^{99m}Tc DPTA aerosol | Passage across alveolar membrane into blood |
| 6. Gastrointestinal system | | | |
| Ectopic gastric mucosa | Meckel's diverticulum scintigraphy | ^{99m}Tc pertechnetate | Active uptake by ectopic gastric mucosa |
| Difficulty in swallowing | Esophageal transit and reflux | ^{99m}Tc sulfur colloid | Transit of labeled material |
| Gastrointestinal hemorrhage | GI bleed study | ^{99m}Tc sulfur colloid | Blood pool label extravasating into bowel |
| | | | ^{99m}Tc labeled red cells |
| Diarrhea (inflammatory bowel disease) | White cell scintigraphy | ^{99m}Tc leucocytes | Leucocyte migration |
| Vomiting (gastroparesis) | | ^{99m}Tc sulphur colloid in egg (solid phase) | |
| | Gastric emptying study | | Compartmental localization of labeled material |
| Dumping | | ^{111}In DTPA in orange juice (liquid phase) | |
| Ectopic splenic tissue | Splenic scintigraphy | Heat damaged ^{99m}Tc labeled red blood cells | Splenic trapping of damaged cells |
| Focal liver lesion (hemangioma) | Red blood cell study | ^{99m}Tc labeled red blood cells | Red cell pooling |
| Cholecystitis | | | |
| Biliary dyskinesia | | | |
| | Hepatobiliary study | ^{99m}Tc iminodiacetic acid derivatives | Uptake by hepatocytes and excretion into bile |
| Biliary atresia | | | |
| Bile leak (postoperative) | | | |

Contd...

Contd...

| Clinical problem | Imaging technique | Radiopharmaceutical | Biological behavior |
|---|------------------------------------|---------------------------------------|--|
| Abdominal sepsis | | ^{99m} Tc | Leucocyte migration |
| | White cell or gallium scintigraphy | | |
| Pyrexia of unknown origin | | ⁶⁷ Ga gallium citrate | Binds to transferrin and leaks into extravascular space |
| 7. Urological, adrenal and genitourinary systems | | | |
| Hypertension (renovascular disease) | Captopril renography | ^{99m} Tc MAG3 | Captopril-induced change in renal transit time and/or function |
| Renal tract obstruction | Diuresis renography | ^{99m} Tc DTPA | Glomerular filtration |
| | | ^{99m} Tc MAG3 | Proximal tubular secretion |
| Renal scarring | Static renal scintigraphy | ^{99m} Tc DMSA | Glomerular filtration and proximal tubular uptake |
| Vesicoureteral reflux | Indirect micturating cystogram | ^{99m} Tc MAG3 | Compartmental localization |
| Adrenal medullary tumor | Adrenal study | ¹²³ I MIBG | Uptake by noradrenaline transporter |
| Adrenal cortical tumor | Adrenal study | ¹²³ I iodocholesterol | Incorporation into hormone metabolism |
| 8. Cancer | | | |
| Skeletal metastases | Bone scintigraphy | ^{99m} Tc polyphosphate | Osteoblastic response |
| Thyroid cancer | Whole body iodine scintigram | ¹³¹ I sodium iodide | Uptake by Na/I transporter |
| Space occupying lesion in brain (SOL) | Tumor imaging | ²⁰¹ Tl (thallous chloride) | K ⁺ analogue indicating perfusion |
| | | ¹⁸ F fluorodeoxyglucose | Marker of glucose metabolism |
| Soft tissue mass (sarcoma) | Tumor imaging | ²⁰¹ Tl (thallous chloride) | K ⁺ analogue indicating perfusion |
| | | ¹⁸ F fluorodeoxyglucose | Marker of glucose metabolism |
| Tumor staging | Tumor imaging | | |
| Tumor recurrence | | ¹⁸ F fluorodeoxyglucose | Tumor glucose metabolism |
| Tumor response assessment | | | |
| Neuroblastoma | MIBG scintigram | ¹²³ I MIBG | Uptake by noradrenaline transporter |

Contd...

Contd...

| Clinical problem | Imaging technique | Radiopharmaceutical | Biological behavior |
|-----------------------------|--------------------|---|---------------------------------|
| Tumor hypoxia | Hypoxia imaging | ^{18}F fluoromisonidazole | Trapped in hypoxic cells |
| Sentinel node detection | Lymphoscintigraphy | $^{99\text{m}}\text{Tc}$ nanocolloid | Lymphatic uptake and trapping |
| Insulinoma | | | |
| Somatostatin receptor study | | ^{111}In pentetreotide (Octreotide®) | Binds to somatostatin receptors |
| Carcinoid tumor | | | |

QUESTIONS

1. On 3 phase ^{99m}Tc -MDP bone scan, which of the following bone lesions will show least osteoblastic activity?
 - a. Paget's disease
 - b. Osteoid osteoma
 - c. Fibrous dysplasia
 - d. Fibrous cortical defect
2. Bone scan in multiple myeloma shows:
 - a. Hot spot
 - b. Cold spot
 - c. Diffusely increased uptake
 - d. Diffusely decreased uptake
3. Investigation of choice for locating parathyroid gland:
 - a. Tc thallium subtraction scan
 - b. CAT scan
 - c. USG
 - d. Angiography
4. Gamma camera in nuclear medicine is used for:
 - a. Organ imaging
 - b. Measuring the radioactivity
 - c. Monitoring the surface contamination
 - d. RIA
5. Increased radioisotope uptake is seen in A/E:
 - a. Primary bone tumor
 - b. Osteomyelitis
 - c. Paget's disease
 - d. Pseudoarthrosis
6. Distribution of functional renal tissue is seen by:
 - a. DMSA
 - b. DTPA
 - c. MAG3-Tc99
 - d. I^{123} iodocholesterol.
7. Vesicoureteric reflux is demonstrated by using:
 - a. DMSA
 - b. DTPA
 - c. MAG3-Tc99
 - d. I^{123} iodocholesterol
8. GFR is measured with which of the following?
 - a. Iodohippurate.
 - b. Tc^{99m} - DTPA
 - c. Tc^{99m} - MAG3
 - d. Tc^{99m} -DMSA
9. Impaired renal function is assessed by:
 - a. MAGS
 - b. Iodohippurate
 - c. DMSA Scan
 - d. DTPA
10. Renal GFR is best measured by:
 - a. TC^{99} DMSA
 - b. TC^{99} pyrophosphate scan.
 - c. TC^{99} DTPA
 - d. Creatinine clearance.
 - e. TC^{99} albumin scan.
11. Amount of I^{131} used for thyroid scan is?
 - a. 5 Microcuries
 - b. 50 Microcuries
 - c. 50 Millicuries.
 - d. 500 Millicuries
12. In pancreatic scanning radioisotope used is:
 - a. Cr51
 - b. Se75
 - c. Tc99
 - d. I131
13. Which one of the following is the most preferred route to perform cerebral angiography?
 - a. Transfemoral route
 - b. Transaxillary route
 - c. Direct carotid puncture
 - d. Transbrachial route

14. **Reversible ischemia of the heart is detected by:**
 - a. Angiography
 - b. Thallium-201-scan
 - c. MUGA
 - d. Resting echocardiography
15. **^{99m}Tc is derived from:**
 - a. Str-99 b. Mo-99
 - c. Str-90 d. Mo-90
16. **The half-life of ^{99m}Tc :**
 - a. 6 hours b. 12 hours
 - c. 24 hours d. 48 hours
17. **Dysprosium-16 is used for:**
 - a. Pituitary tumor ablation
 - b. Resection of cerebral metastases
 - c. Synovectomy in intractable arthritis
 - d. Treatment of painful bone metastases
18. **Multiple gated radionuclide cardiac MUGA scan is used for:**
 - a. Testing drug toxicity on myocardium
 - b. Myocardial perfusion assessment
 - c. Testing ventricular function
 - d. Detecting myocardial aneurysm
19. **Radioactive iodine used in radio-immuno assay:**
 - a. I-123 b. I-125
 - c. I-131 d. I-133
20. **Regarding cardiovascular imaging, false is:**
 - a. Perfusion agents: ^{99m}Tc -mibi, ^{201}Tl
 - b. Viability agents : ^{18}F fdg, ^{201}Tl
 - c. Multigated cardiac function muga: ^{99m}Tc -RBCS
 - d. Infarct agents: ^{99m}Tc -pertechnetate
 - e. Angio-venography: ^{99m}Tc -RBCS
21. **Commonly used agent for liver nuclear scan:**
 - a. ^{99m}Tc -sulfur colloid
 - b. ^{99m}Tc -disida
 - c. ^{99m}Tc -rbc
 - d. ^{99m}Tc Co4
22. **In the nuclear bone scan all the following disorders will show up as 'hot spots' except:**
 - a. Metastasis to bone
 - b. Multiple myeloma
 - c. Osteomyelitis
 - d. Hyperparathyroidism
23. **Double density sign:**
 - a. Osteoclastoma
 - b. Osteoma
 - c. Osteosarcoma
 - d. Osteoid osteoma
24. **Acute myocardial infarct scintigraphy is done with:**
 - a. Thallium
 - b. Gallium
 - c. Neodymium
 - d. Tc stannous pyrophosphate
25. **Local pain can be treated with the following except:**
 - a. Portable MRI
 - b. Diathermy
 - c. Ultrasound therapy
 - d. Transcutaneous electrical stimulation
26. **Radionuclide scans are useful in following except:**
 - a. GI bleed
 - b. Cholecystitis
 - c. Intrabdominal abscess
 - d. Local staging of tumors
27. **Radiation induced necrosis of brain—most sensitive:**
 - a. CT
 - b. MRI
 - c. PET
 - d. Biopsy
28. **Gastroparesis is most commonly diagnosed with:**
 - a. MRI abdomen
 - b. Multidetector CT
 - c. Scintigraphic scan
 - d. High frequency ultrasound

29. **Bilateral symmetric increased uptake on salivary gland scintigraphy is seen in:**
- Sjogren's syndrome
 - Pleomorphic adenoma
 - Abscess
 - Calculi
30. **Which of the following has the ability to identify ischemic or hibernating myocardium?**
- ^{99m}Tc labeled compounds
 - CT scan
 - Gated single photon emission computed tomography
 - Echocardiography
31. **Contraindications to V/Q scanning include all the following except:**
- Asthma
 - Severe heart failure
 - Right to left cardiac shunt
 - Severe pulmonary hypertension
32. **Best investigation to distinguish radiation necrosis from recurrence of a brain tumor:**
- DWMRI with AOC mapping
 - HMPAO SPECT
 - MR spectroscopy
 - PET scan
33. **Positron emission tomographic (PET) scanning is useful in evaluation of the following except:**
- Mycotic aortic aneurysm
 - Solitary pulmonary nodules
 - Staging lung cancer
 - Lymph node involvement by malignancy
34. **Brain SPECT utilizes:**
- | | |
|--------------|---------------|
| a. Radium | b. Technetium |
| c. Plutonium | d. Barium |
35. **Most common radionuclide used for bone scan:**
- | | |
|----------|----------|
| a. I-123 | b. Tc-99 |
| c. Cr-51 | d. Sr-89 |

ANSWER KEYS

1. **Ans. d.** Fibrous cortical defect
2. **Ans. d.** Diffusely decreased uptake
3. **Ans. a.** Tc thallium subtraction scan
4. **Ans. a.** Organ imaging
5. **Ans. d.** Pseudoarthrosis
6. **Ans. a.** DMSA
7. **Ans. c.** MAG3-Tc99
8. **Ans. b.** ^{99m}Tc -DTPA
9. **Ans. d.** DTPA
10. **Ans. c.** TC99 DTPA
11. **Ans. b.** 50 Microcuries
12. **Ans. b.** Se75
13. **Ans. a.** Transfemoral route
14. **Ans. b.** Thallium201-scan
15. **Ans. b.** Mo-99
16. **Ans. a.** 6 hours
17. **Ans. c.** Synovectomy in intractable arthritis
18. **Ans. a.** Testing drug toxicity on myocardium, **c.** Testing ventricular function
19. **Ans. a.** I-123
20. **Ans. d.** Infarct agents: ^{99m}Tc -pertechnetate
21. **Ans. a.** ^{99m}Tc -sulfur colloid
22. **Ans. b.** Multiple myeloma
23. **Ans. d.** Osteoid osteoma
24. **Ans. d.** Tc stannous pyrophosphate
25. **Ans. a.** Portable MRI
26. **Ans. d.** Local staging of tumors
27. **Ans. c.** PET
28. **Ans. c.** Scintigraphic scan
29. **Ans. a.** Sjogren's syndrome
30. **Ans. a.** ^{99m}Tc labeled compounds
31. **Ans. a.** Asthma
32. **Ans. d.** PET scan
33. **Ans. a.** Mycotic aortic aneurysm
34. **Ans. b.** Technetium
35. **Ans. b.** Tc-99

Section D

FEW THUMB RULES IN RADIOLOGY

Few Thumb Rules in Radiology

- Bone fractures/congenital deformities—IOC-NCCT
- Osteomyelitis—MRI
- Bone tumors—MRI
- Bone metastasis-bone scan
- NCCT is IOC for bone fractures, stone (except gallstones – IOC is USG), air and acute cerebral bleed
- MRI is IOC for all skull and spine pathologies even the spinal bony metastasis.
- CT is IOC for most of the chest pathologies except pancoast tumor (MRI is IOC)
- CT is IOC for most mediastinal pathologies except posterior mediastinal pathologies like- Neuroenteric enteric cyst and neurogenic tumors (MRI is IOC)

INVESTIGATION OF CHOICE

- Multiple Bone Metastasis—Bone scan
- Spine Metastasis—MRI
- Avascular necrosis—MRI
- Bone Density/Osteoporosis-DEXA (Dual energy X-ray absorptiometry)
- Aneurysm/ AV Fistula—Angiography
- Dissecting Aneurysm (Stable)-MRI (Unstable)—Transesophageal USG
- Pericardial Effusion-Echocardiography
- Loculated pericardial effusion—MRI > CT
- Minimum Pericardial Effusion—Echocardiography
- Ventricular Function—MRI
- Pulmonary Embolism—CT angiography (IOC) > Pulmonary Angiography (Gold standard) > V/Q Scan
- Interstitial lung disease(Sarcoidosis)—HRCT
- Bronchiectasis—HRCT scan
- Solitary Pulmonary Nodule—High resolution CT (HRCT)
- Posterior Mediastinal Tumor—MRI
- Pancoast Tumor (Superior Sulcus Tumor)—MRI
- Minimum Ascites/Pericardial effusion/Pleural effusion—USG
- Posterior Cranial Fossa—MRI

- Acute hemorrhage—NCCT
- Chronic hemorrhage—MRI
- Intracranial space occupying Lesion—MRI
- Primary brain tumour—contrast MRI (Gold standard however remains to be biopsy)
- Metastatic brain tumor—(Gadolinium) contrast enhanced MRI
- Temporal Bone—HRCT
- SAH Diagnosis—NCCT
- SAH etiology-4 vessel MR Angiography > CT Angiography (Gold standard is DSA)
- Nasopharyngeal angiofibroma—CECT scan. MRI for intraocular is intracranial extent
- Acoustic neuroma—Gadolinium enhanced MRI
- Obstetrics—USG
- Calcifications—NCCT
- Blunt abdominal Trauma—CECT
- Acute necrotizing pancreatitis—CECT
- GERD-24 hour pH manometer > endoscopy
- Dysphagia-Endoscopy (1st investigation usually barium study)
- Congenital hypertrophic pyloric stenosis—USG
- Extrahepatic biliary atresia—perioperative cholangiogram. IOC—HIDA scan
- Obstructive Jaundice/GB Stones—USG
- Diverticulosis—barium enema
- Diverticulitis—CECT scan
- Renal TB (early)—IVP, (Late)—CECT
- Posterior urethral valve—MCU
- Ureteric stone—noncontrast CT
- Renal artery stenosis—Percutaneous angiography (Gold standard. IOC—MR Angio)
- Discrete swelling(solitary nodule) of thyroid—FNAC

Radiological Appearance of Heart in Various Diseases

- Fallot's tetralogy: Boot shaped heart
- Tricuspid atresia: Box shaped heart
- TAPVC (total anomalous pulmonary venous connection): Snow man appearance, 8 shaped heart, cottage loaf appearance (Supracardiac)
- Constrictive pericarditis: Egg in cup
- Pericardial effusion: water bottle, pear shaped.
- Pulmonary hypertension: Jug handle
- Transposition of vessels: egg shell cracking/egg on side
- Hilar dance on fluoroscopy is seen in cases of ASD and Bronchiectasis
- Sitting duck sign is seen in—persistent truncus arteriosus

Emergency Radiotherapy is given in—SANS

- S—Superior vena cava syndrome
- A—Acute epidural spinal cord compression

SIGNS OF SYSTEMIC RADIOLOGY

Neuroradiology

- Banana sign (antenatal US) Refers to a banana-shaped configuration of the cerebellum. Associated with neural tube defects.
- Spalding sign Overlapping cranial sutures. Sign of fatal demise on prenatal ultrasound.
- Tau sign (MRI) Persistent trigeminal artery
- Bat wing appearance (MRI brain) Appearance of 4th ventricle that may be seen with Joubert syndrome.
- Empty delta sign Sign of intracranial dural sinus thrombosis on CECT
- Eye of the tiger sign Low signal intensity circumscribing the globus pallidus in patients with
- Boxcar ventricles Appearance of frontal horns that may be seen in Huntington's disease.
- Strawberry skull Appearance of skull that may be seen on fetal US with trisomy 18
(MRI brain; coronal) Hallervorden-Spatz disease.
- Figure of eight (MRI brain) Appearance of the brain in lissencephaly
- Mount Fuji sign (CT brain) Tension pneumocephalus
- 'Salt and pepper' appearance on MRI Paraganglioma
- Molar tooth sign (CT/MRI brain) Joubert syndrome
- Salt and pepper skull Hyperparathyroidism
- Spider web Appearance of collateral vessels that may be seen on hepatic venography in Budd-Chiari syndrome.
- Starry sky sign CT Appearance that may be seen with neurocysticercosis.
- Cloverleaf skull Appearance of the skull that may be seen with thanatophoric dysplasia
- Tear drop sign (Orbits) Blowout fracture

Cardiothoracic Radiology

- Figure 3 sign (CXR) Appearance of the aorta that may be seen in patients with coarctation of the aorta.
- Comet tail sign Produced by the distortion of vessels and bronchi that lead to an adjacent area of round atelectasis.
- Cob web appearance False lumen in aortic dissection
- Bulging Fissure sign (CXR) Klebsiella pneumonia.
- Egg on a string' heart TGA

- Crazy-Paving sign (HRTC lung) Nonspecific appearance consisting of linear network or reticular pattern with areas of ground-glass opacification. Classically associated with pulmonary alveolar proteinosis.
- Epicardial fat pad sign Sign of a pericardial effusion.
- Feeding vessel sign (CT chest) Sign of pulmonary septic emboli. Can be seen with lung metastases. At times in wg.
- Sitting duck' heart Persistent truncus arteriosus
- Scimitar sign MRI appearance that may be seen with eccentric cystic adventitial disease.
- Bat wing appearance (chest) Classic chest radiography finding for pulmonary edema.
- Finger in glove sign Sign of mucous plugging seen with allergic bronchopulmonary aspergillosis.
- Golden 's' sign (CXR) Right upper lobe atelectasis created by a central mass.
- Signet ring sign (chest CT) Sign of bronchiectasis.
- Lambda sign Uptake in the hilar and paratracheal lymph nodes gives the appearance of a lambda. This is seen in sarcoidosis.
- Juxtaphrenic peak sign (CXR) Tenting of the diaphragm that may be seen with right upper lobe atelectasis.
- Luftsichel sign (CXR) "air crescent". Sign that may be seen with left upper lobe atelectasis.
- Naclerio's v sign (CXR) V shaped lucency that may be seen over the left lower mediastinum in pneumomediastinum.
- Saber-Sheath trachea Appearance of trachea that may be seen with COPD.
- Panda Sign On a Gallium-67 citrate scan, uptake in the lacrimal and salivary glands gives the appearance of a panda. This is suggestive of sarcoidosis.
- Sandstorm appearance (CXR) Pulmonary alveolar microlithiasis.
- Hampton's hump Triangular opacity secondary to infarction in the periphery of the lung distal to a pulmonary embolism.
- Snowstorm pattern (CXR) Silicosis
- Stripe sign On a v/q scan, subpleural activity in a region of decreased pulmonary perfusion. Sign is used to rule out pulmonary embolism.
- Westermark's sign (CXR) Regional pulmonary oligemia secondary to pulmonary embolism.
- Snowman's heart Supracardiac total anomalous pulmonary venous connection.
(figure of '8' or cottage loaf heart)

- Keyhole sign (USG) US appearance that may be seen with posterior urethral valves.
- Parallel track sign Pattern of uptake that may be seen on bone scan in patients with hypertrophic osteoarthropathy.
- Starry sky sign US appearance that may be seen with hepatitis.
- Shoulder sign (ba meal) Appearance of hypertrophic pyloric stenosis that may be seen on upper GI series.
- Pearl necklace sign MRI sign that may be seen with adenomyomatosis.
- Rosary sign CT sign that may be seen with adenomyomatosis.
- Sandwich sign Bulky lymphoma encasing mesenteric vessels.
- Target sign CHPS.
- Umbrella sign (on BMFT) Intussuception.
- Soft-Tissue Rim Sign Hepatic candidiasis and liver metastases.
- String of beads sign Sign of IC TB
- Whirlpool sign Appearance of a ureteral edema surrounding a calculus. Helps differentiates a calculus from a phlebolith (also see comet sign).
- String sign Small bowel obstruction
- Tit sign US sign of midgut volvulus in a neonate.
- Snowstorm pattern (ob/gyn) Ileocaecal TB, hypertrophic pyloric stenosis, Crohn's disease (seen on upper GI series).
- Snowstorm pattern (ob/gyn) Appearance of hypertrophic pyloric stenosis that may be seen on upper GI series.
- Snowstorm pattern (ob/gyn) US pattern for a molar pregnancy.

Musculoskeletal Radiology

- Sausage digit Psoriasis
- Dagger sign Ankylosing spondylitis
- Bamboo spine Ankylosing spondylitis
- Blade of grass sign Paget's disease (seen in leg bones)
- Linguae sign (MRI breast) MRI sign that may be seen in patients with intracapsular breast implant rupture.
- Blood fluid levels (MRI) Abc
- Sail sign Elbow effusion
- Sandwich vertebra Sclerotic end plates that may be seen with osteopetrosis.
- Bone bruise sign Acl tear
- Hair on end skull Hemolytic anemia
- Bone in Bone' / Endobone sign Osteopetrosis
- Crowded carpal sign Volar perilunar dislocation
- Button Sequestrum Eosinophilic granuloma
- Canoe paddle ribs Appearance of ribs that may be seen with mucopolysaccharidoses.

- Saber shin
 - Picture frame vertebral body
 - Celery stalking
 - Champagne-glass pelvis
 - Scottie dog sign
 - Bullet carpal bones
 - Brim sign
 - Rugger Jersey Sign
 - C Sign
 - Deep lateral femoral notch sign
 - Fallen fragment sign
 - FBI Sign
 - fish vertebra
 - Flaring of anterior ends of ribs
 - Fragment-In-Notch Sign
 - Groundglass appearance
 - H-Shaped Vertebra
 - Tumbling Bullet Sign
 - Trolley-Track Sign (X-ray)
 - Lemon sign (antenatal US)
 - Half Moon Sign
 - Lace like pattern (X-ray)
 - Corduroy vertebral body
 - Lacunar skull
 - Breast in a breast sign
 - Lateral capsular sign
 - Metacarpal sign
 - Pedestal sign
 - Bow Tie sign (MRI knee)
 - Crescent sign (X-ray)
 - Pencil in cup deformity
 - Drooping shoulder sign
- Appearance of tibia that may be seen with syphilis.
- Paget disease.
- Irregular appearance of metaphyses in patients with rubella. Also used to describe metaphyses in patients with osteopathia striata.
- Achondroplasia
- On oblique radiographs, the posterior elements form the appearance of a scottie dog. Spondylolysis can have the appearance of a collar around the neck.
- Appearance of carpal bones that may be seen with mucopolysaccharidoses.
- Paget's disease
- Chronic renal failure
- Subtalar coalition
- Acl tear
- Unicameral bone cyst
- Lipohemarthrosis
- Osteopenia
- Rickets
- Bucket-handle tear of the menisci
- Fibrous dysplasia of bone
- Sickle cell anemia
- Post-traumatic bone cyst
- Ankylosing spondylitis
- Refers to shape of calvarium associated with spina bifida.
- Absent in posterior dislocation of the shoulder
- Pattern that may be seen with sarcoid arthropathy.
- Appearance of thickening trabeculations seen in vertebral hemangiomas. (polka-dot sign on CT).
- Appearance of skull that may be seen in infants with Chiari ii malformation.
- Term used to describe fibroadenolipomas.
- Acl tear - segund fracture
- Short 4th metacarpal
- Loosening prosthesis
- Discoid meniscus
- Avascular necrosis
- Erosion pattern of digits that may be seen in patients with psoriatic arthritis.
- Inferior subluxation of the shoulder

- Cotton wool skull Paget's disease
- Shepard's Crook Deformity Appearance of proximal femur that may be seen with fibrous dysplasia.
- Snowstorm pattern (breast) US pattern for breast implant rupture.
- Trough Line In posterior shoulder dislocation, frontal radiographs reveal two nearly parallel lines in the superomedial aspect of the humeral head.
- Spade shaped tufts Shape of tufts that may be seen with acromegaly.
- Vacuum Phenomenon (CT/MRI) Degenerative disk disease
- Step-Off Vertebral Body Sign Sickle cell, Gaucher's disease
- Trident hand Appearance of hands that may be seen with achondroplasia.
- Wimberger's ring sign A circular, opaque radiologic shadow surrounding epiphyseal centers of ossification in patients with scurvy.
- Swan neck deformity Rheumatoid arthritis
- Telephone receiver shaped femora Appearance of femora that can be seen with thanatophoric dysplasia.

Few Important Discoveries in Radiology

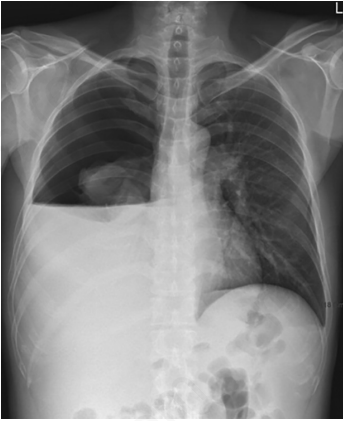
- Antoine Henri Bacquerel Radioactivity
- Charles Dotter Image guided medical procedures; Father of Interventional Radiology
- David E. Kuhl Positron Emission Tomography (PET)
- Ernest Rutherford Alpha/beta particles, neutrons; Father of Nuclear Physics
- Godfrey Hounsfield Computed Tomography (CT) scan
- Ian Donald Ultrasonography (USG); Father of Obstetric Ultrasound
- John Caffey Father of Pediatric Radiology
- Laterbeur and Mansfield MRI (Nobel Prize in Medicine)
- Wilhelm Roentgen X-rays (Nobel Prize in Physics); Father of Diagnostic Radiology

Section E

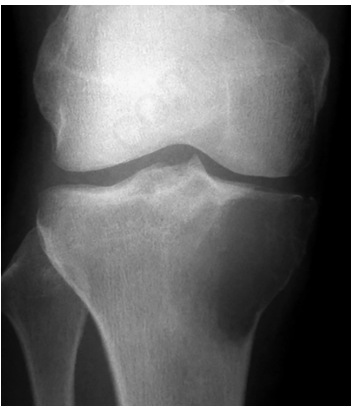IMAGE BASED QUESTIONS

IMAGE BASED QUESTIONS

1. Chest X-ray of an adult male presented with respiratory distress. What is the diagnosis.

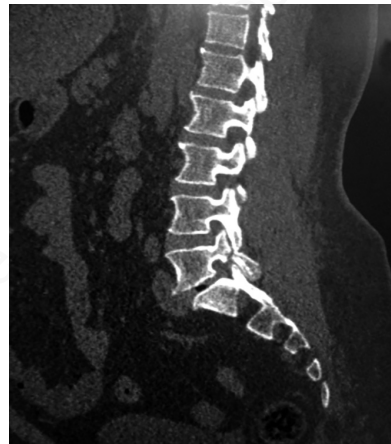

- a. Hydropneumothorax
 - b. Pleural effusion
 - c. Pneumothorax
 - d. Consolidation of right lower lobe
2. A 28 years old female presented with knee pain in the orthopedics OPD. She did not have fever or constitutional symptoms. X-ray knee was advised. What is the diagnosis:

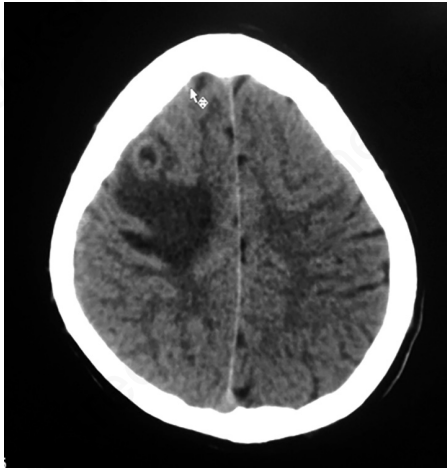


- a. Aneurysmal bone cyst
- b. Giant cell tumor
- c. Simple bone cyst
- d. Osteomyelitis

3. An adult patient was presented with severe low back pain at the level of L5 vertebra with no motor weakness. A CT LS spine was advised. What is the diagnosis and corresponding X-ray sign?

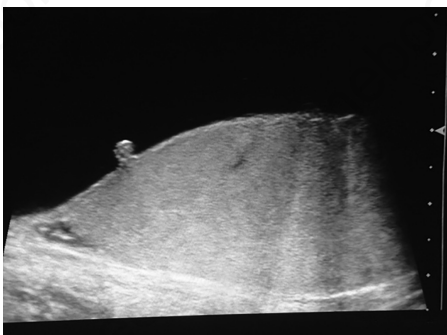


- a. Spondylolisthesis, Scottish dog with collar
 - b. Spondylolysis, beheaded Scottish dog
 - c. Spondylolisthesis, beheaded Scottish dog
 - d. Spondylolysis, Scottish dog with collar
4. A child had an episode of seizure and fell unconscious. The child was referred to a neurologist who prescribed for a NCCT head. What is the diagnosis:



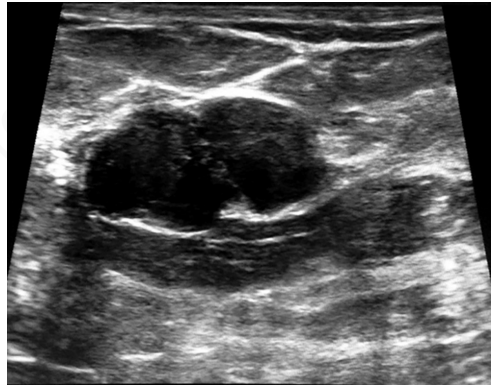
- a. Tuberculoma
- b. Metastasis
- c. Abscess
- d. Neurocysticercosis

5. An adult was presented with left scrotal swelling with no constitutional features, having a dull character. An USG was done by a radiologist who diagnosed it a left sided hydrocele. What is the characteristic USG finding in hydrocele.



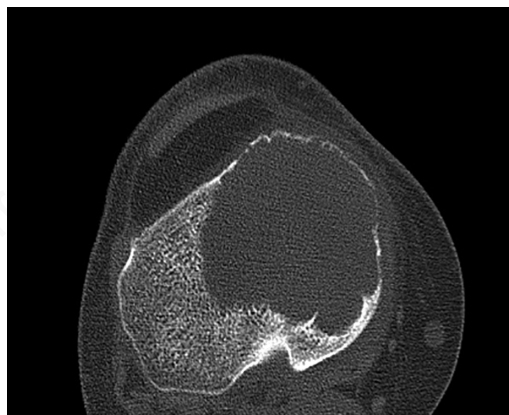- a. Isoechoic collection in scrotal sac
- b. Hypoechoic collection in scrotal sac
- c. Anechoic collection in scrotal sac
- d. Hyperechoic collection in scrotal sac

6. A 36 years old female presented with lump in right breast with no features of nipple discharge, skin puckering or weight loss. USG reveals an oval iso to hypoechoic soft-tissue nodule which shows lateral distal shadow with no surface irregularity. What is the diagnosis.



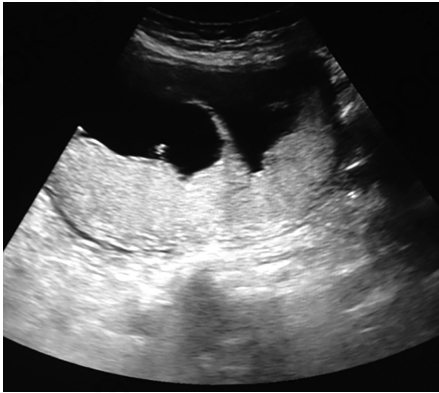
- a. Breast abscess
- b. Carcinoma breast
- c. Fibroadenoma
- d. Simple cyst

7. A patient was presented with knee pain and found to have a lytic lesion the X-ray. A NCCT was done for the better evaluation of the lesion and found to be a nonaggressive lesion. All the features are seen on this NCCT except:



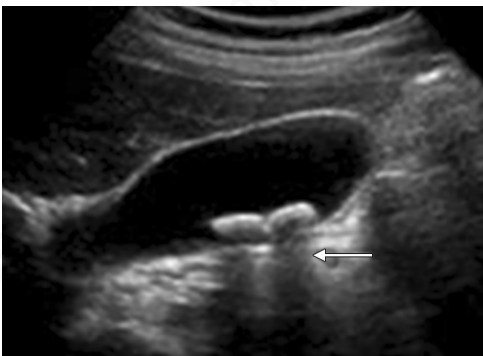- a. Well-defined lytic lesion
- b. Narrow zone of transition
- c. No surrounding sclerotic rim
- d. Associated exophytic soft-tissue component

8. A female patient presented in the ANC OPD for routine checkup. She was found to have twin pregnancy. USG was done to assess the chorionicity of the placenta. What is the diagnosis and USG sign on given image.



- a. Monochorionic diamniotic, twin peak sign
- b. Monochorionic diamniotic, T sign
- c. Dichorionic diamniotic, twin peak sign
- d. Dichorionic diamniotic, T sign

9. What is this USG sign (arrow) known as in the sonography of gallbladder?

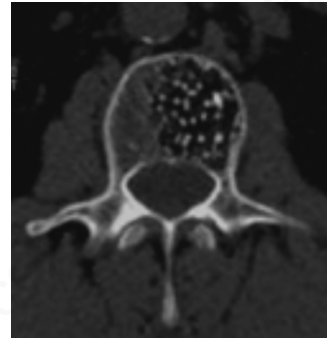


- a. Acoustic enhancement
- b. Acoustic shadowing
- c. Comet-tail artefact
- d. Twinkling artefact

10. Where do we see this sign ?

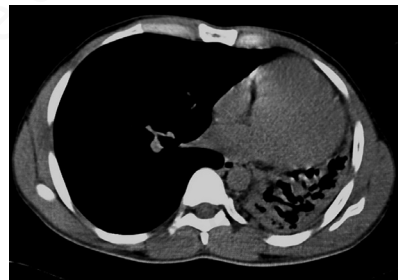
- a. Gallbladder calculi
- b. Kidney calculus
- c. Gallbladder cyst
- d. Both A and B

11. In a patient with back pain, NCCT spine reveals the following appearance of the vertebra. What is the diagnosis and the sign known on X-ray?



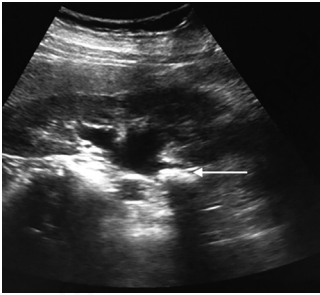
- a. Hemangioma, corduroy appearance
- b. Hemangioma, polka dot appearance
- c. Osteoporosis, H-shape vertebrae
- d. Osteoporosis, polka dot appearance

12. A patient presented in the chest clinic for follow-up of pulmonary Kochs post ATT having dyspnea. CT scan was advised which revealed:



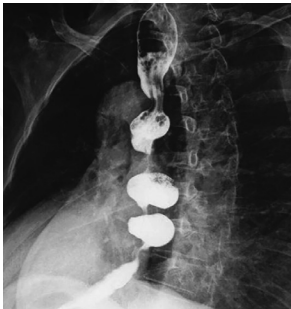- a. Consolidation with airbronchogram with ipsilateral mediastinal shift
- b. Collapse with bronchiectatic changes and ipsilateral mediastinal shift
- c. Collapse with airbronchogram and ipsilateral mediastinal shift
- d. Consolidation with bronchiectatic changes with ipsilateral mediastinal shift

13. A patient presented with acute left lumbar pain of colicky nature. USG KUB was advised which revealed the following finding in left upper ureter (arrow). What is the diagnosis?



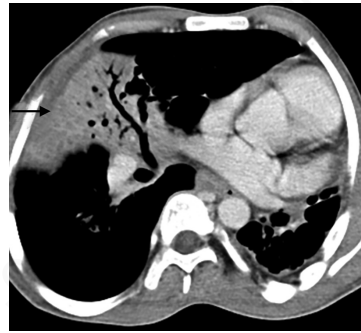- a. Pyelonephritis
- b. Renal calculus
- c. Abscess formation
- d. Cyst with internal hemorrhage

14. A patient presented with dysphagia with pain. A barium swallow was advised. Which revealed multiple alternating constrictions and dilations giving shish-kebab appearance. What is the diagnosis and gold standard investigation?



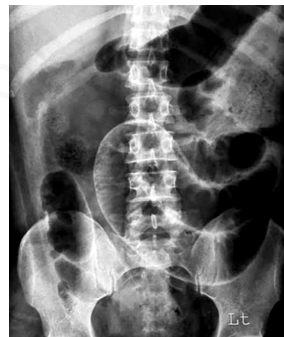- a. Presbyoesophagus, barium swallow
- b. Diffuse esophageal spasm, barium swallow
- c. Diffuse esophageal spasm, manometry
- d. Multiple strictures, barium study

15. A follow-up patient of healed pulmonary tuberculosis who had fibro-atelectatic collapse of left lung presented with acute onset respiratory distress, cough and fever. Urgent CECT was advised as the CXR was inconclusive. The CT revealed (arrow) in the right lung. What is the diagnosis?



- a. Collapse
- b. Consolidation
- c. Malignancy
- d. Abscess

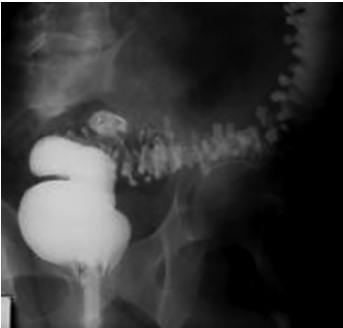16. A patient presented with acute abdomen and came to emergency department. After initial pain management X-ray abdomen was done to rule out acute obstruction. What is the diagnosis and sign known as?



- a. Hydropneumoperitoneum, football sign

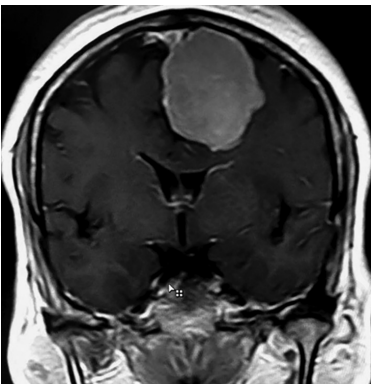
- b. Pneumoperitoneum, string of beads sign
- c. Acute small bowel obstruction, string of beads sign
- d. Pneumoperitoneum, Rigler's sign

17. An old age patient presented with left lower abdominal pain with bleeding per rectum occasionally. Barium enema was done. What is the diagnosis and sign in the radiograph?



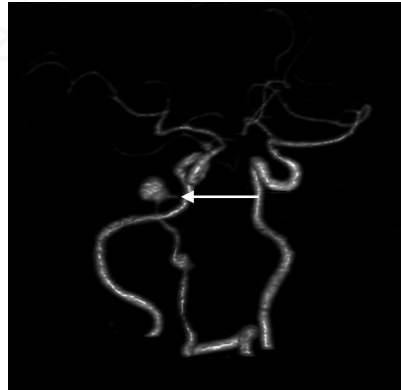- a. Hirschsprung's disease, transition zone
- b. Diverticulosis, cork screw appearance
- c. Diverticulosis, saw tooth appearance
- d. Ulcerative colitis, pseudopolyps

18. An adult female presented with headache which was not responding to conservative treatment. Contrast enhanced MRI was done which shows the following space occupying lesion in the brain. What is the most probable diagnosis.



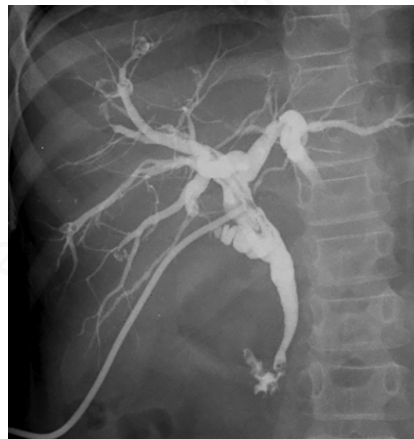- a. Medulloblastoma
- b. Abscess
- c. Meningioma
- d. Ganglioglioma

19. An old aged patient presented with worst headache of his life. NCCT head revealed acute SAH. MR angiography was performed. What is the diagnosis (arrow)?



- a. Arteriovenous malformation
- b. Cavernous hemangioma
- c. Fusiform aneurysm
- d. Berry aneurysm

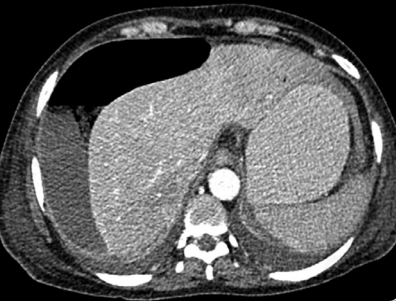20. Identify the investigation done to rule out CBD calculus:



- a. T-Tube cholangiogram, invasive
- b. MRCP- noninvasive

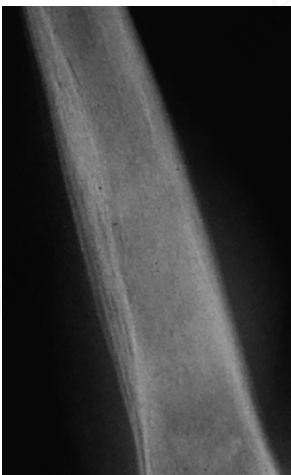
- c. T-Tube cholangiogram, noninvasive
- d. ERCP, invasive

21. A diagnosed patient of severe peptic ulcer disease presented in the emergency with severe abdominal pain and abdominal rigidity. An emergency CECT was performed to see the cause of the pain. Which reveals:



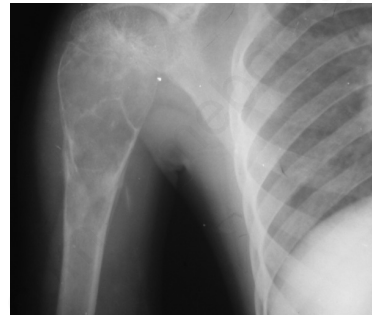
- a. Ascites
- b. Pneumoperitoneum
- c. Hydropneumoperitoneum
- d. Liver abscess

22. A child presented with severe leg pain with fever. On examination, a large soft tissue was noted in the leg. A radiograph was obtained which reveals a soft tissue and periosteal reaction. What is the probable diagnosis and the type of periosteal reaction.



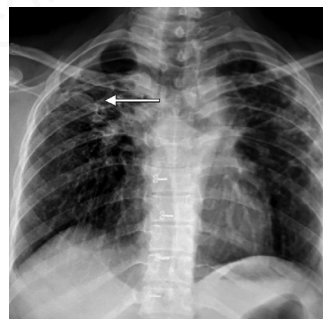
- a. Osteosarcoma, sunburst periosteal reaction
- b. Ewing's sarcoma, sunburst periosteal reaction
- c. Osteosarcoma, onion ring periosteal reaction
- d. Ewing's sarcoma, onion ring periosteal reaction

23. A child presented with pain in right shoulder. X-ray reveals an expansile lytic lesion with the radiographic appearance as shown below. What is the diagnosis?



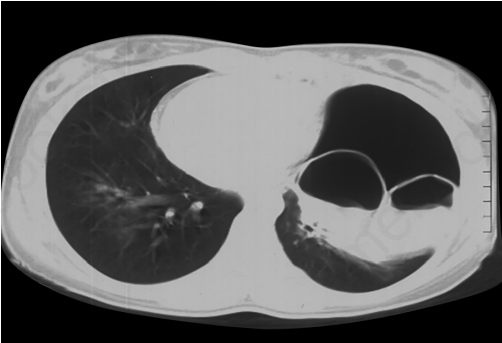
- a. Simple bone cyst
- b. Aneurysmal bone cyst
- c. Giant cell tumor
- d. Osteosarcoma

24. A follow-up case of healed pulmonary tuberculosis presented with hemoptysis. Chest X-ray was undertaken which revealed old fibrotic opacities in bilateral lungs and a focal lesion in the right upper zone (arrow). What is the probable diagnosis.



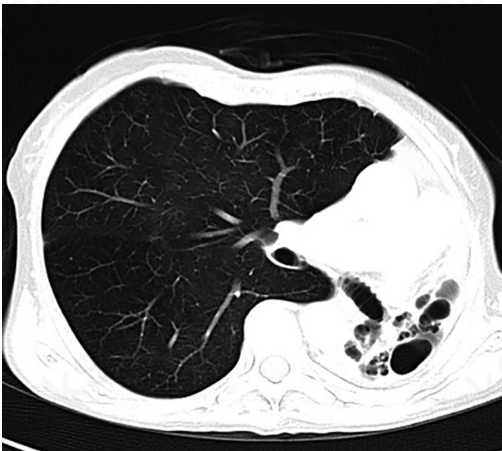
- a. Abscess with cavity formation
- b. Fungal ball with air crescent sign
- c. Hydatid cyst
- d. Consolidation

25. A patient from north east presented with respiratory distress. An NCCT was prescribed which reveals a large cystic lesion with following features. What is the diagnosis?



- a. Lung abscess
- b. Lung cyst (simple)
- c. Hydatid cyst
- d. Hydropneumothorax

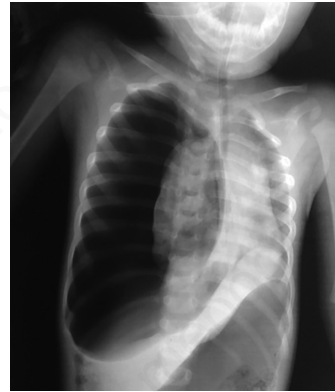26. What is the diagnosis?



- a. Consolidation
- b. Collapse with no mediastinal shift

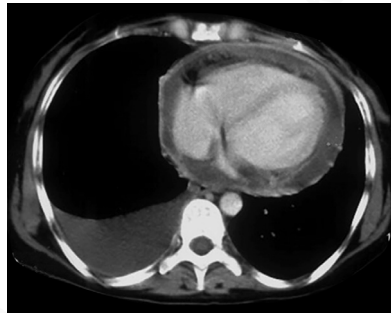
- c. Collapse with mediastinal shift
- d. Collapse with mediastinal shift with bronchiectasis

27. A child presented with acute respiratory distress. X-ray reveals a life threatening condition. Diagnosis is:



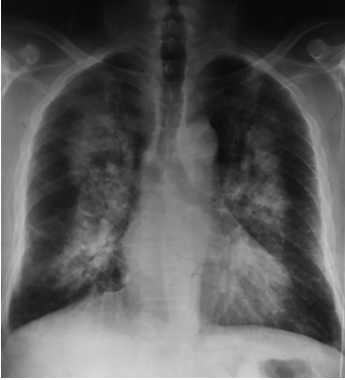- a. Hydropneumothorax
- b. Pneumothorax
- c. Tension pneumothorax
- d. Collapse of lung with hyperinflated contralateral lung

28. A patient of tuberculosis underwent CECT which reveals following findings.



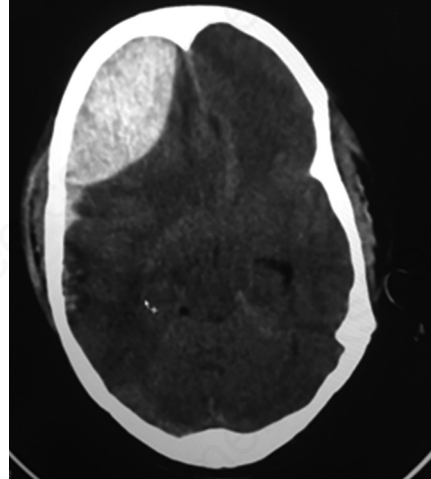
- a. Pleural effusion and pericardial effusion
- b. Pleural effusion and pericarditis with effusion
- c. Empyema and pericarditis with effusion
- d. Empyema with pericardial effusion

29. An ICU patient presented with acute respiratory distress and frothy pink sputum. CXR reveals:



- Acute pulmonary edema with cephalisation of pulmonary vessels
- Pulmonary edema with acute interstitial edema and septal thickening
- Aspiration pneumonia with pleural effusion
- Frank pulmonary edema with bat wing appearance

30. A patient presented in the emergency department after head trauma. NCCT was advised. What is the diagnosis?



- Acute EDH
- Hyperacute EDH
- Chronic EDH
- Subacute EDH

ANSWERS

- | | | | | | | |
|--------|--------|--------|--------|--------|--------|--------|
| 1. a. | 2. b. | 3. c. | 4. d. | 5. c. | 6. c. | 7. d. |
| 8. c. | 9. b. | 10. d. | 11. a. | 12. b. | 13. b. | 14. c. |
| 15. b. | 16. d. | 17. c. | 18. c. | 19. d. | 20. a. | 21. c. |
| 22. d. | 23. a. | 24. b. | 25. c. | 26. d. | 27. c. | 28. b. |
| 29. d. | 30. a. | | | | | |